This is a digital copy of a book that was preserved for generations on library shelves before it was carefully scanned by Google as part of a project to make the world's books discoverable online.

It has survived long enough for the copyright to expire and the book to enter the public domain. A public domain book is one that was never subject to copyright or whose legal copyright term has expired. Whether a book is in the public domain may vary country to country. Public domain books are our gateways to the past, representing a wealth of history, culture and knowledge that's often difficult to discover.

Marks, notations and other marginalia present in the original volume will appear in this file - a reminder of this book's long journey from the publisher to a library and finally to you.

Usage guidelines

Google is proud to partner with libraries to digitize public domain materials and make them widely accessible. Public domain books belong to the public and we are merely their custodians. Nevertheless, this work is expensive, so in order to keep providing this resource, we have taken steps to prevent abuse by commercial parties, including placing technical restrictions on automated querying.

We also ask that you:

+ *Make non-commercial use of the files* We designed Google Book Search for use by individuals, and we request that you use these files for personal, non-commercial purposes.

+ *Refrain from automated querying* Do not send automated queries of any sort to Google's system: If you are conducting research on machine translation, optical character recognition or other areas where access to a large amount of text is helpful, please contact us. We encourage the use of public domain materials for these purposes and may be able to help.

+ *Maintain attribution* The Google "watermark" you see on each file is essential for informing people about this project and helping them find additional materials through Google Book Search. Please do not remove it.

+ *Keep it legal* Whatever your use, remember that you are responsible for ensuring that what you are doing is legal. Do not assume that just because we believe a book is in the public domain for users in the United States, that the work is also in the public domain for users in other countries. Whether a book is still in copyright varies from country to country, and we can't offer guidance on whether any specific use of any specific book is allowed. Please do not assume that a book's appearance in Google Book Search means it can be used in any manner anywhere in the world. Copyright infringement liability can be quite severe.

About Google Book Search

Google's mission is to organize the world's information and to make it universally accessible and useful. Google Book Search helps readers discover the world's books while helping authors and publishers reach new audiences. You can search through the full text of this book on the web at `http://books.google.com/`

A 3 9015 00380 094 6
University of Michigan – BUHR


ARTES
SCIENTIA
VERITAS
LIBRARY OF THE
UNIVERSITY OF MICHIGAN
SI QUAERIS PENINSULAM AMOENAM
CIRCUMSPICE

610.5
C64
S6

TRANSACTIONS

OF

THE CLINICAL SOCIETY.

VOL. XXXVII.

TRANSACTIONS

OF

THE CLINICAL SOCIETY

OF

LONDON.

VOLUME THE THIRTY-SEVENTH.

LONDON:
LONGMANS, GREEN, AND CO.
1904.

1837
ARTES
SCIENTIA
VERITAS
LIBRARY OF THE
UNIVERSITY OF MICHIGAN
E PLURIBUS UNUM
SI QUAERIS PENINSULAM AMOENAM
CIRCUMSPICE

610.5
C64
S6

TRANSACTIONS

OF

THE CLINICAL SOCIETY.

VOL. XXXVII.

TRANSACTIONS

OF

THE CLINICAL SOCIETY

OF

LONDON.

VOLUME THE THIRTY-SEVENTH.

LONDON:
LONGMANS, GREEN, AND CO.
1904.

PRINTED BY ADLARD AND SON, LONDON AND DORKING.

NOTICE.

THE present Volume comprises the Proceedings of the Society during its Thirty-seventh Session, October, 1903, to May, 1904.

The Council think it proper to state that the authors of the several communications are alone responsible for the statements, reasonings, and opinions contained in their respective papers.

20, HANOVER SQUARE, W.;
October 14th, 1904.

228206

CONTENTS.

PAGE

NOTICE FROM THE COUNCIL v

LIST OF ILLUSTRATIONS xvi

LIST OF OFFICERS AND MEMBERS OF THE COUNCIL DURING 1904–5 xix

LIST OF PRESIDENTS OF THE SOCIETY FROM ITS FORMATION . xx

LIST OF HONORARY MEMBERS OF THE SOCIETY . . . xxi

LIST OF MEMBERS OF THE SOCIETY xxiii

REPORT OF THE COUNCIL li

TREASURER'S STATEMENT OF RECEIPTS AND PAYMENTS . lii

PAPERS READ:

I. A CASE OF EROSIVE GASTRIC ULCERATION WITH SEVERE HÆMATEMESIS; OPERATION; RECOVERY. By Sir DYCE DUCKWORTH, M.D., LL.D., and H. T. BUTLIN, D.C.L., F.R.C.S. . . . 1

II. A CASE OF ACUTE HÆMORRHAGIC PANCREATITIS. By ANTHONY BOWLBY, C.M.G. . . . 5

III. A CASE OF HÆMORRHAGIC PANCREATITIS. By FREDK. TAYLOR, M.D. 8

PAGE

IV. Case of Myositis Fibrosa, with pathological examination. By Frederick E. Batten, M.D. 12

V. Case of Coma with Measles in an Adult, followed by recovery. By G. Newton Pitt, M.D. 23

VI. A Case of Pernicious Anæmia presenting unusual features. By William Pasteur, M.D. 35

VII. A Case of Chronic Intussusception; excision of forty-two inches of small intestine; recovery. By F. C. Wallis, M.B. . . 42

VIII. Two Cases of Leucocythæmia (Lymphatic Leukæmia). By Frederick Taylor, M.D. . 46

IX. A Case of Post-operative Hernia treated by the Introduction of Prepared Silver-wire Filigree. By Lawrie McGavin . . . 59

X. Congenital Narrowness of the Pyloric Orifice: a Cause of Chronic Gastric Disease in the Adult; illustrated by seven cases successfully treated by operation. By A. Ernest Maylard, M.B., B.S.Lond. . . 63

XI. One Hundred Cases of Gastro-enterostomy for Simple Ulcer of the Stomach and Duodenum. By B. G. A. Moynihan, M.S., F.R.C.S. 74

XII. A Case of Pneumococcal Peritonitis; laparotomy; left empyema; thoracentesis; recovery. By Sir Dyce Duckworth, M.D., LL.D., and Howard Marsh, M.A., F.R.C.S. . 83

PAGE

XIII. A Case of Pneumococcal Peritonitis. By Frederick Taylor, M.D. 91

XIV. A Case of Fibroid Disease of the Pancreas with Calculi, accompanied by Jaundice and subsequently by Diabetes; laparotomy; relief of symptoms; death. By Sidney Phillips, M.D. 96

XV. Two Cases of Malignant Anæmia, without signs of Erythrocytolysis, and associated with Suppuration about the Jaws. By Norman Dalton, M.D. 101

XVII. A Note on a Case of Ankylosis of both Temporo-maxillary Joints. By J. Jackson Clarke, M.B Lond. 110

XVIII. Primary and Secondary Local Tuberculosis of the Thyroid Gland. By Edred M. Corner 112

XIX. A Case of Chronic Polycythæmia with Enlarged Spleen, probably a Disease of the Bone-marrow. By F. Parkes Weber, M.D., F.R.C.P., and J. H. Watson, M.B., B.S. . . 115

XX. Intra-cranial Resection of the Second Division of the Fifth Nerve for Epileptiform Neuralgia. By J. Hutchinson, Jun. . 136

XXI. Foreign Body impacted in Bronchus; Removal by Operation. By W. Pasteur, M D., and T. H. Kellock 141

XXII. Two Cases of Intestinal Obstruction immediately following an attack of Typhoid Fever. By E. W. Goodall, M.D. . . . 145

PAGE

XXIII. Severe and Fatal Hæmaturia of Unknown Origin. By W. G. Spencer 156

XXIV. A Case of Attempted Division of the Eighth Nerve within the Skull for the relief of Tinnitus. By Cuthbert S. Wallace and H. J. Marriage. (With a Report on the Resulting Degenerations by E. Farquhar Buzzard) 159

XXV. Cases illustrating the value of the "X" Rays as a factor of diagnosis of Early Pulmonary Tuberculosis. By A. Stanley Green, M.B., B.S., and W. H. B. Brook, M.D., F.R.C.S. 167

XXVI. Notes of Two Cases illustrating the advantages and disadvantages of X-ray Treatment in Recurrent Carcinoma of the Breast. By E. A. Peters, M.D., F.R.C.S. . 180

XXVII. A Case of Tuberculous Pyopneumothorax treated by Incision and Removal of Ribs. By David W. Finlay, M.D. 183

XXVIII. Two Cases of Tumour of the Left Auricle of the Heart, simulating Mitral Stenosis. By Dr. H. T. Thompson and Dr. C. U. Aitchison (introduced by Dr. Percy Kidd) . 192

XXIX. Femoral Aneurysm in Hunter's Canal; Ligature of the Superficial, Femoral, and Popliteal Arteries; Cure of the Aneurysm; Death from Cardiac Disease ten weeks later. By Henry Betham Robinson, M.S. Lond. 205

PAGE

CLINICAL CASES EXHIBITED:

I. A CASE OF DIFFUSE LIPOMA (ADIPOSIS DOLOROSA ?) IN A MAN. By LEONARD WILLIAMS, M.D. 209

II. A CASE OF ECTOPIA VESICÆ AFTER OPERATION. By THOS. H. KELLOCK, M.A., F.R.C.S. . . 210

III. A CASE OF (?) TUMOUR AT THE BASE OF THE SKULL. By THOS. H. KELLOCK, M.A., F.R.C.S. 210

IV. CASE OF VASCULAR NASO-PHARYNGEAL FIBROMA OF EXTENSIVE ORIGIN, FINALLY REMOVED BY A COMBINED OPERATION THROUGH THE SOFT AND HARD PALATE AND EXTENSIVE REMOVAL OF ANTERIOR WALL OF LEFT SUPERIOR MAXILLARY BONE. By HERBERT TILLEY, M.D., B.S., F.R.C.S. 212

V. TWO CASES OF OSTEITIS DEFORMANS. By HERBERT FRENCH, M.B. 213

VI. A CREASOTE INHALER REMOVED FROM THE ŒSOPHAGUS BY GASTROTOMY, WITH SKIAGRAPH SHOWING THE INHALER *IN SITU*. By HERBERT J. PATERSON, B.C., F.R.C.S. (introduced by Mr. A. A. BOWLBY, C.M.G.) 215

VII. CASE OF A CHILD WITH APPARENTLY COMPLETE ABSENCE OF SEXUAL ORGANS. By EDGAR BEAUMONT, L.R.C.P., M.R.C.S. . . . 216

VIII. A CASE OF SARCOMA OF THE LEFT SUPRA-RENAL BODY WITH SECONDARY DEPOSITS IN THE CRANIAL BONES, WITH THE SPECIMEN OF A SECOND CASE. By HAROLD L. BARNARD, M.S. 216

PAGE

IX. A Pedicle Trident for Multiple Ligature of Pedicles and Omentum. By Harold L. Barnard, M.S. 217

X. Diffuse Lipomatosis in a Woman without any Associated Pain. By F. Parkes Weber, M.D. 220

XI. Diffuse Lipomatosis in a Man with slight General Wasting. By F. Parkes Weber, M.D. 221

XII. Tumour of the Liver in a Boy æt. 10 years. By A. E. Garrod, M.D. 222

XIII. Case of Total Paraplegia due to Caries of the Mid-dorsal Vertebræ, for which the operation of Costo-transversectomy has been performed, with Complete Recovery. By W. H. B. Brook, M.D. 223

XIV. A Case of Chronic Periostitis (Syphilitic), with Skiagram. By John R. Lunn . . 224

XV. A Case of Ununited Fracture of Radius and Ulna. By John R. Lunn 224

XVI. Bilateral Enlargement of Testicles in a Boy æt. 10. By W. G. Spencer . . . 225

XVII. A Case of Ophthalmoplegia Externa with Blindness of Acute Onset, in a Child æt. 5 years. By F. E. Batten, M.D. . . . 225

XVIII. Congenital Absence of the Phalanges of the Left Hand. By Lawrie McGavin, F.R.C.S. 226

PAGE

XIX. Translucent Cyst (probably Dermoid) of Root of Nose. By Raymond Johnson . . 227

XX. A Case of Multiple Aneurysm in which the largest, affecting the Brachial Artery, was excised. By Raymond Johnson . . 228

XXI. Two Cases of Post-Diphtheritic Chronic Bulbar Paralysis. By Wilfred Harris, M.D. 228

XXII. Congenital Elevation of the Shoulder. By Charles R Keyser 230

XXIII. Congenital Absence of the Fibulæ. By Charles R. Keyser 230

XXIV. Two Cases of Osteitis Deformans. By C. Gordon Watson 231

XXV. A Case of Fracture-dislocation in the Upper Cervical Region without Symptoms. By William Henry Battle 232

XXVI. Fracture of both Pedicles of the Axis. By Edred M. Corner 234

XXVII. Fracture of the Body and Laminæ of the Fifth Cervical Vertebra. By Edred M. Corner 234

XXVIII. Congenital Absence of the Small Muscles of the Hands and Deformity of the Feet in Mother and Infant Daughter. By H. Batty Shaw, M.D. 235

XXIX. Sporadic Case of Friedreich's Disease. By Bertram Abrahams, M.B. 237

PAGE

XXX. Morbus Cordis. Pulmonary Regurgitation associated with Mitral Stenosis. By J. Porter Parkinson 238

XXXI. A Case of Enlargement of the Bones of the Cranium, Jaw, and Thorax (? Syphilitic). By W. G. Stone, M.D. . . . 239

XXXII. A Case of Achondroplasia with Spinal Curvature (? Rachitic). By Charles R. Keyser, F.R.C.S. 240

XXXIII. A Case of Pyopneumothorax due to Phthisis; operations on the principles of Estlander's (Thoracoplasty); healing with an Aërial Fistula. By Edred M. Corner 243

XXXIV. Cyst arising in Connection with the Organ of Giraldes. By Donald Armour, M.B., F.R.C.S. 244

XXXV. Contracture of Hip and Knee treated by Elastic Traction. By T. H. Openshaw, C.M.G. 245

XXXVI. A very large Femoral Hernia. By William Henry Battle 245

XXXVII. Case of Movable Knee-joint Three and a Half Years after Operation for Extensive Tuberculous Disease. By F. J. Steward, M.S., F.R.C.S. 247

XXXVIII. Case of Polycythæmia with Enlarged Spleen and Chronic Erythromelalgia of the Left Foot. By F. Parkes Weber, M.D. 249

PAGE

XXXIX. Case of Firm Ankylosis and Contracture of Left Knee treated by Elastic Steel Bar Traction. By T. H. Openshaw, C.M.G. 251

XL. Case of Arthritis of Knee, following Fracture of Femur, improved after Removal of Pressure by means of Splint. By T. H. Openshaw, C.M.G. . . . 252

XLI. Case of Early Acromegaly. By Wilfred Harris, M.D. 253

XLII. A Case of Congenital Heart Disease. ? Patent Ductus Arteriosus. By Lee Dickinson, M.D. 253

XLIII. Case of Congenital Malformation, Upper Limb and Ear. By R. P. Rowlands, M.S. 256

XLIV. Case of Early Puberty. By R. P. Rowlands, M.S. 256

XLV. A Case of Gangrene of the Tips of the Fingers of Both Hands. By C. J. Symonds, M.S. 257

XLVI. Case of Spontaneous Fracture of the Neck of the Femur. By C. J. Symonds, M.S. . 257

LIST OF ILLUSTRATIONS.

PLATES.

TO FACE PAGE

PLATES I, II. ILLUSTRATING A CASE OF MYOSITIS FIBROSA. FREDERICK E. BATTEN, M.D. 22

PLATE III. ILLUSTRATING CASE OF CHRONIC INTUSSUSCEPTION. F. C. WALLIS 44

PLATE IV. ILLUSTRATING CASES OF LEUCOCYTHÆMIA. FREDERICK TAYLOR, M.D. 58

PLATE V. ILLUSTRATING CASE OF ATTEMPTED DIVISION OF THE EIGHTH NERVE WITHIN THE SKULL FOR THE RELIEF OF TINNITUS. C. S. WALLACE AND H. J. MARRIAGE . 166

PLATES VI—IX. ILLUSTRATING CASES ILLUSTRATING THE VALUE OF THE "X" RAYS AS A FACTOR OF DIAGNOSIS OF EARLY PULMONARY TUBERCULOSIS. A. STANLEY GREEN, M.B., AND W. H. B. BROOK, M.D. . . . 178

PLATE X. ILLUSTRATING CASES OF TUMOUR OF THE LEFT AURICLE OF THE HEART SIMULATING MITRAL STENOSIS. H. T. THOMPSON AND C. U. AITCHISON 204

PLATE XI. ILLUSTRATING CASE OF SPONTANEOUS FRACTURE OF THE NECK OF THE FEMUR. C. J. SYMONDS . . 258

ILLUSTRATIONS IN TEXT.

PAGE

CHART ILLUSTRATING CASE OF COMA WITH MEASLES IN AN ADULT. G. NEWTON PITT, M.D. 25

FACSIMILE OF HANDWRITING ILLUSTRATING CASE OF SEVERE CEREBRAL DEFECT FOLLOWING MEASLES. G. NEWTON PITT, M.D. 33

FIGS. 1, 2.—ILLUSTRATING CASES OF LEUCOCYTHÆMIA. FREDERICK TAYLOR, M.D. 47, 48

FIGS. 3, 4.—ILLUSTRATING CASE OF POLYCYTHÆMIA WITH ENLARGED SPLEEN. F. PARKES WEBER, M.D., AND J. H. WATSON, M.B. 123, 131

FIG. 5.—ILLUSTRATING INTRA-CRANIAL RESECTION OF THE SECOND DIVISION OF THE FIFTH NERVE FOR EPILEPTIFORM NEURALGIA. J. HUTCHINSON, JUN. 137

FIG. 6.—ILLUSTRATING FOREIGN BODY IMPACTED IN BRONCHUS AND REMOVED BY OPERATION. W. PASTEUR, M.D., AND T. H. KELLOCK 141

FIG. 7.—ILLUSTRATING INTESTINAL OBSTRUCTION IMMEDIATELY FOLLOWING AN ATTACK OF TYPHOID FEVER. E. W. GOODALL, M.D. 148

FIGS. 8, 9.—ILLUSTRATING CASES OF OSTEITIS DEFORMANS. HERBERT FRENCH, M.D. 213

FIGS. 10, 11.—ILLUSTRATING A PEDICLE TRIDENT FOR MULTIPLE LIGATURE OF PEDICLES AND OMENTUM. HAROLD L. BARNARD 218, 219

FIG. 12.—ILLUSTRATING CASE OF FRACTURE-DISLOCATION IN THE UPPER CERVICAL REGION, WITHOUT SYMPTOMS. WILLIAM HENRY BATTLE 233

FIG. 13.—ILLUSTRATING CONGENITAL ABSENCE OF THE SMALL MUSCLES OF THE HANDS. H. BATTY SHAW, M.D. 236

FIG. 14.—ILLUSTRATING CASE OF ACHONDROPLASIA WITH SPINAL CURVATURE. C. R. KEYSER 241

FIG. 15.—ILLUSTRATING CASE OF A VERY LARGE FEMORAL HERNIA. WILLIAM HENRY BATTLE 246

CLINICAL SOCIETY OF LONDON.

OFFICERS AND COUNCIL

ELECTED AT

THE GENERAL MEETING, MAY 27, 1904.

PRESIDENT.

FREDERICK TAYLOR, M.D.

VICE-PRESIDENTS.

SIR WILLIAM R. GOWERS, M.D., F.R.S.
F. DE HAVILLAND HALL, M.D.
J. KINGSTON FOWLER, M.D.
HENRY MORRIS, M.B.
C. H. GOLDING-BIRD, M.B.
H. T. BUTLIN.

TREASURER.

G. H. MAKINS, C.B.

COUNCIL.

F. E. BATTEN, M.D.
HARRY CAMPBELL, M.D.
J. WALTER CARR, M.D.
W. S. COLMAN, M.D.
NORMAN DALTON, M.D.
E. W. GOODALL, M.D.
F. H. HAWKINS, M.D.
PERCY KIDD, M.D.
HECTOR MACKENZIE, M.D.
F. W. STRUGNELL.
HERBERT W. ALLINGHAM.
ANTHONY A. BOWLBY, C.M.G.
WALTER EDMUNDS, M.C.
SIR ALFRED FRIPP, C.B., M.V.O., M.S.
J. HUTCHINSON, JUN.
T. H. KELLOCK, B.C.
B. G. A. MOYNIHAN, M.S.
C. S. WALLACE, M.B.
F. C. WALLIS, B.C.

HONORARY SECRETARIES.

WILLIAM PASTEUR, M.D.
W. G. SPENCER, M.S., M.B.

TRUSTEES.

SIR J. BURDON SANDERSON, BART., M.D., F.R.S.
JOHN HAMMOND MORGAN, C.V.O.
CHARTERS JAMES SYMONDS, M.S.

PRESIDENTS OF THE SOCIETY

(*From its Formation*).

ELECTED

1867 SIR THOMAS WATSON, BART., M.D., D.C.L., LL.D., F.R.S.

1869 SIR JAMES PAGET, BART., D.C.L., LL.D., F.R.S.

1871 SIR WILLIAM WITHEY GULL, BART., M.D., D.C.L., F.R.S.

1873 SIR PRESCOTT GARDNER HEWETT, BART., F.R.S.

1875 SIR WILLIAM JENNER, BART., M.D., K.G.C.B., D.C.L., F.R.S.

1877 GEORGE WILLIAM CALLENDER, F.R.S.

1879 EDWARD HEADLAM GREENHOW, M.D., F.R.S.

1881 SIR JOSEPH LISTER, BART., D.C.L., LL.D., F.R.S. [RIGHT HON. LORD LISTER].

1883 SIR ANDREW CLARK, BART., M.D., LL.D., F.R.S.

1885 THOMAS BRYANT.

1887 SIR WILLIAM HENRY BROADBENT, BART., M.D., F.R.S.

1889 CHRISTOPHER HEATH.

1891 SIR DYCE DUCKWORTH, M.D., LL.D.

1893 JOHN WHITAKER HULKE, F.R.S.

1895 THOMAS BUZZARD, M.D.

1897 JOHN LANGTON.

1899 SIR RICHARD DOUGLAS POWELL, BART., K.C.V.O., M.D.

1901 HOWARD MARSH.

1903 FREDERICK TAYLOR, M.D.

HONORARY MEMBERS.

ELECTED

1889 GAIRDNER, SIR WILLIAM TENNANT, K.C.B, M.D., LL.D., F.R.S., 32, George Square, Edinburgh.

1899 HEATH, CHRISTOPHER, F.R.C.S., LL.D., Consulting Surgeon to University College Hospital, 36, Cavendish Square, W. (C. 1867-71, V.-P. 1876-8. T. 1879-88. P. 1889-91.)

1902 HOLMES, TIMOTHY, M.A.Cantab., F.R.C.S., Treasurer of, and Consulting Surgeon to, St. George's Hospital, 6, Sussex Place, Hyde Park, W. (C. 1867-9. V.-P. 1873-5.) *Trans.* 16.

1889 LISTER, The Right Hon. LORD, P.C., O.M., D.C.L., LL.D., F.R.S., 12, Park Crescent, W. (P. 1881–2.)

1902 OSLER, WILLIAM, M.D., F.R.C.P., F.R.S., Regius Professor of Medicine, University of Oxford.

1895 SANDERSON, SIR J. BURDON, Bart., M.A. and D.M.Oxon., M.D. and LL.D.Edin., D.Sc.Trin. Coll. Dubl., D.C.L.Durham, F.R.C.P., F.R.S., Late Regius Professor of Medicine in the University of Oxford, 64, Banbury Road, Oxford. (S. 1867-9. C. 1870. V.-P. 1871-3.)

1904 SMITH, SIR THOMAS, Bart., K.C.V.O., 5, Stratford Place, W. (C. 1869–71. V.-P. 1880-82.) *Trans.* 14.

1895 WILKS, SIR SAMUEL, Bart., M.D., LL.D., F.R.S., F.R.C.P., Consulting Physician to Guy's Hospital, 8, Prince Arthur Road, Hampstead, N.W.

FOREIGN HONORARY MEMBERS.

ELECTED

1881 BILLINGS, JOHN S., M.D., D.C.L.Oxon., Brevet Lieut.-Col. and Surgeon U.S. Army; Librarian, Public Library, New York.

1902 ERB, WILHELM HEINRICH, M.D., Director of the Medical Clinic, Heidelberg.

1881 VON ESMARCH, FRIEDRICH, M.D., Professor of Surgery and Director of the Surgical Clinique in the University of Kiel.

1902 KEEN, WILLIAM WILLIAMS, A.M., M.D., LL.D., F.R.C.S.Eng.(Hon.), 1729, Chestnut Street, Philadelphia, U.S.A.

1895 KOCHER, Dr. THEODOR, Professor of Surgery in the University of Berne.

1902 VON LEYDEN, ERNST, M.D., Professor of Medicine in the University of Berlin, Bendlerstrasse 30, Berlin, W.

1895 LUCAS-CHAMPIONNIÈRE, Dr. JUST, Surgeon to the St. Louis Hospital, Paris.

1881 MAZZONI, COSTANZO, Professor of Surgery at the Royal University of Rome, and Surgeon to the Hospital of San Giacomo at Rome.

1902 MIKULICZ-RADECKI, JOH., Director of Surgical Clinic and Polyclinic, Breslau.

1889 MITCHELL, S. WEIR, M.D., LL.D., 1524, Walnut Street, Philadelphia.

1895 NOTHNAGEL, H., Professor of Clinical Medicine in the University of Vienna.

*** *Members are requested to inform the Secretaries of any Corrections when necessary.*

LIST OF MEMBERS.

(O.M.) *Original Member.*
(P.) *President.*
(V.P.) *Vice-President.*
(T.) *Treasurer.*
(S.) *Secretary.*
(C.) *Member of Council.*

The Surnames of Members who have compounded for their Subscriptions are printed in this type (TYPE). *The Surnames of Members who have paid the Composition Fee for the 'Transactions' are printed in this type* (Type). *The figures succeeding the word* Trans. *show the number of Papers contributed to the 'Transactions.'* C.C. *refers to the Clinical Cases exhibited.*

ELECTED

1879 ABERCROMBIE, JOHN, M.D., 23, Upper Wimpole Street, W. (C. 1890–2.) *C.C.* 3.

1896 ABRAHAMS, BERTRAM LOUIS, M.B., B.Sc., 14, Welbeck Street, W. *Trans.* 1, *C.C.* 3.

1895 ACKERLEY, RICHARD, Croft House, The Hill, Surbiton.

1889 ACLAND, THEODORE DYKE, M.D., 19, Bryanston Square, W. *Trans.* 1.

1883 ADAMS, WILLIAM COODE, M.B., 1, Eton Avenue, South Hampstead, N.W.

1888 ADDINSELL, AUGUSTUS W., M.B., C.M., 7, Upper Brook Street, W.

1884 ADENEY, EDWIN LEONARD, M.D., 3, Sion Terrace, Mount Sion, Tunbridge Wells.

1883 ALLCHIN, WILLIAM HENRY, M.D., 5, Chandos Street, W. (C. 1894–7.)

1885 ALLINGHAM, HERBERT WILLIAM, 25, Grosvenor Street, W. (C. 1903– .) *Trans.* 6.

1888 ANDERSON, JOHN, M.D., 9, Harley Street, W.

1868 ANDERSON, JOHN FORD, M.D., 41, Belsize Park, N.W. (C. 1897–8.)

1899 ANDREWS, EDWARD COLLINGWOOD, M.D., 110, Finchley Road, N.W.

1902 ARMOUR, DONALD JOHN, M.B., 89, Harley Street, W. *C.C.* 1.

1885 ARMSTRONG, HENRY GEORGE, Wellington College, Berkshire.

1888 ARMSTRONG, HUGH, Tamworth, New South Wales.

O.M. ARNOTT, HENRY, The Rectory, 32, High Street, Beckenham, Kent. (C. 1871–5.) *Trans.* 3.

1903 ATKINSON, THOMAS REUELL, M.D., Chadwell Heath, Essex.

1894 ATTLEE, JOHN, M.D., B.C., 58, Brook Street, W. *C.C.* 1.

1898 AVERY, LEONARD, 29, Chester Street, Grosvenor Place, S.W.

ELECTED

1880 **BAKER**, HENRY FRANCIS, 2, Mandeville Place, Manchester Square, W.

1895 BALDWIN, GERALD R., 166, Victoria Street, Melbourne, Australia. *Trans.* 1.

1883 BALLANCE, CHARLES ALFRED, M.B., M.S., 106, Harley Street, W. (C. 1894–6.) *Trans.* 3, *C.C.* 5.

1904 BALLANCE, H. A., 46, Prince of Wales Road, Norwich.

1888 BANHAM, HENRY FRENCH, M.D., Assington Vicarage, Colchester.

1868 BANTOCK, GEORGE GRANVILLE, M.D., 12, Granville Place, W.

1876 BARKER, ARTHUR E. J., 87, Harley Street, W. (C. 1883–5, V.P. 1901–3.) *Trans.* 17, *C.C.* 12.

1882 BARKER, FREDERICK CHARLES, M.D., Surgeon-Major, Bombay Medical Service, India.

1894 BARLING, HARRY GILBERT, 87, Cornwall Street, Newhall Street, Birmingham. (C. 1901–3.) *Trans.* 3.

1875 BARLOW, SIR THOMAS, Bart., K.C.V.O., M.D., 10, Wimpole Street, W. (C. 1880–2, 1891–4, S. 1888–90, V.P. 1895–8.) *Trans.* 11, *C.C.* 5.

1902 BARNARD, HAROLD L., 21, Wimpole Street, Cavendish Square, W. *Trans.* 2, *C.C.* 7.

1888 BARRS, A. G., M.D., 22, Park Place, Leeds.

1888 BARTON, EDWIN A., 56, Kensington Court, Kensington, W.

1891 BARTON, J. KINGSTON, 14, Ashburn Place, Courtfield Road, S.W. (C. 1901–4.)

1901 BARWELL, HAROLD SHUTTLEWORTH, 55, Wimpole Street, Cavendish Square, W.

O.M. BARWELL, RICHARD, 55, Wimpole Street, Cavendish Square, W. (C. 1872–5, V.P. 1877–9.) *Trans.* 21, *C.C.* 2.

O.M. **BASTIAN**, HENRY CHARLTON, M.D., F.R.S., 8A, Manchester Square, W. (C. 1876–8, V.P. 1891–3.) *Trans.* 7.

1896 BATTEN, FREDERICK E., M.D., 33, Harley Street, W. (C. 1903– .) *Trans.* 5, *C.C.* 6.

1899 BATTEN, RAYNER DERRY, M.D., B.S., 33, Harley Street, W. *C.C.* 1.

1888 BATTERHAM, JOHN WILLIAMS, M.B., B.S., Bank House, Grand Parade, St. Leonard's.

1886 BATTLE, WILLIAM HENRY, 49, Harley Street, W. (C. 1899–1902.) *Trans.* 7, *C.C.* 14.

1868 BÄUMLER, CHRISTIAN G. H., M.D., University of Erlangen. *Trans.* 4.

1903 BEAUMONT, EDGAR, "Claremont," Gipsy Hill, Upper Norwood, S.E. *C.C.* 2.

1898 BEDDARD, ARTHUR PHILIP, M.D., 44, Seymour Street, Portman Square, W.

1880 **BEEVOR**, CHARLES EDWARD, M.D., 135, Harley Street, W. (C. 1890–1.) *Trans.* 2, *C.C.* 9.

1901 BEEVOR, SIR HUGH REEVE, Bart., M.D., 17, Wimpole Street, Cavendish Square, W. *C.C.* 3.

ELECTED

1884 BENHAM, F. LUCAS, M.D., Campden House, nr. Exeter, Semaphore, South Australia. *Trans.* 4.

1883 BENHAM, ROBERT FITZROY, 11, Earl's Court Square, S.W.

1874 BENNETT, Sir WILLIAM HENRY, K.C.V.O., 1, Chesterfield Street, W. (C. 1889, 1892–4, S. 1890–1, V.P. 1895–8.) *Trans.* 4, *C.C.* 3.

1896 BENTHAM, EDWARD COOPER, 10, Princes Street, Cavendish Square, W.

1889 BENTLEY, ARTHUR J. M., M.D., Mena House, Pyramids, Cairo, Egypt.

1896 BERKELEY, G. H. A. COMYNS, M.B., 53, Wimpole Street, W.

1882 BERRY, FREDERICK HAYCRAFT, M.D., Watford, Herts.

1885 BERRY, JAMES, B.S., 21, Wimpole Street, W. (C. 1898–1901.)

1889 BIDWELL, LEONARD ARTHUR, 15, Upper Wimpole Street, W. (C. 1901–4.) *Trans.* 5, *C.C.* 1.

1882 BINDLEY, PHILIP HENRY, M.B. (Travelling).

1889 BISSHOPP, FRANCIS ROBERT BRYANT, M.A., M.B., B.S., Parham House, Tunbridge Wells.

1904 BOLTON, CHARLES, M.D., 22, Bentinck Street, Cavendish Square, W.

1893 BOND, JAMES WILLIAM, M.D., 26, Harley Street, W. *C.C.* 2.

1898 BOSANQUET, WILLIAM CECIL, M.D., 117A, Harley Street, Cavendish Square, W.

1888 BOSTOCK, ROBERT ASHTON, Cefn Mor, Penmaen, Glamorganshire.

1900 BOUSFIELD, ARTHUR, M.B., The Cheal, Hornsey Lane, N.

1899 BOWLAN, MARCUS MARWOOD, M.B., B.S., The Infirmary, Raine Street, St. George-in-the-East, E.

1883 BOWLBY, ANTHONY A., C.M.G., 24, Manchester Square, W. (C. 1891–3, 1904– , S. 1901–4.) *Trans.* 6, *C.C.* 4.

1883 Bowles, ROBERT LEAMON, M.D., 16, Upper Brook Street, W. (C. 1890–1.)

1896 BOX, CHARLES R., M.D., 2, Devonshire Place, Portland Place, W. *Trans.* 1.

1889 BOYD, STANLEY, B.S., 134, Harley Street, W. (C. 1899–1902.) *Trans.* 1, *C.C.* 7.

1890 BRADFORD, JOHN ROSE, M.D., F.R.S., 8, Manchester Square, W. (C. 1900–1902.) *Trans.* 2.

1878 BRIDGES, ROBERT, M.B., M.A., The Manor House, Yattendon, Berkshire. *Trans.* 1.

1868 BRIGHT, GEORGE CHARLES, M.D., Cannes, Alpes Maritimes, France.

O.M. BROADBENT, Sir WILLIAM HENRY, Bart., K.C.V.O., M.D., F.R.S., 84, Brook Street, W. (C. 1871–3, V.P. 1881–3, P. 1887–8.) *Trans.* 17.

1887 BROCK, J. H. E., M.D., B.S., 77, Fellows Road, South Hampstead, N.W.

1894 **BRODIE**, C. GORDON, Fernhill, Wootton Bridge, Isle of Wight. *C.C.* 1.

1898 Brook, WILLIAM HENRY BREFFIT, M.D., B.S., 33, Silver Street, Lincoln. *Trans.* 4, *C.C.* 1.

1890 BROWN, WALTER HENRY, 19, Queen Street, Leeds. *Trans.* 2.

ELECTED

1876 BROWNE, GEORGE BUCKSTON, 80, Wimpole Street, W. (C. 1891–3.) *Trans.* 3.

1904 BROWNE, H. S. D., M.B., B.C., 78, High Street, Winchester.

1893 BROWNE, JAMES WILLIAM, M.B., 37, Holland Park Avenue, W. *Trans.* 1.

1887 BROWNE, OSWALD AUCHINLECK, M.A., M.D., 7, Upper Wimpole Street, W.

1883 BRUCE, JOHN MITCHELL, M.D., 23, Harley Street, W. (C. 1901–4.)

1893 BRYANT, JOHN HENRY, M.D., 4, St. Thomas's Street, S.E., and 8, Mansfield Street, Portland Place, W. *Trans.* 2.

O.M. BRYANT, THOMAS, M.Ch., 27, Grosvenor Street, W. (C. 1872, V.P. 1876–7, P. 1885–6.) *Trans.* 9.

1890 BUCKLAND, FRANCIS O., B.A., M.B., C.M., Brockenhurst, Hants. *Trans.* 1.

1901 BUCKNALL, THOMAS RUPERT HAMPDEN, M.S., 35, Harley Street, W.

1891 BURGHARD, FREDERIC FRANÇOIS, M.D., M.S., 86, Harley Street, W.

1881 BURNET, ROBERT WILLIAM, M.D., 36, Grosvenor Street, W. *Trans.* 1.

1879 BURTON, WILLIAM EDWARD, 24, Wimpole Street, W.

1900 BUSCH, JOSEF PAUL ZUM, M.D., Chiswell House, 133, Finsbury Pavement, E.C. *Trans.* 1.

1881 BUTLIN, HENRY TRENTHAM, 82, Harley Street, W. (C. 1887–9, V.P. 1904- .) *Trans.* 8, *C.C.* 1.

1884 BUXTON, DUDLEY WILMOT, M.D., B.S., 82, Mortimer Street, W.

1902 BUZZARD, EDWARD FARQUHAR, M.D., 33, Harley Street, W. *Trans.* 1.

O.M. BUZZARD, THOMAS, M.D., 74, Grosvenor Street, W. (S. 1870–2, C. 1873–6, V.P. 1880–1, P. 1895–7.) *Trans.* 15, *C.C.* 3.

1901 CADDY, ADRIAN, M.B, 2/2, Harington Street, Calcutta.

1891 CADDY, ARNOLD, 2/2, Harington Street, Calcutta.

1893 CALEY, HENRY ALBERT, M.D., 24, Upper Berkeley Street, W. *C.C.* 1.

1890 CALVERT, JAMES, M.D., 113, Harley Street, Cavendish Square, W. *Trans.* 2, *C.C.* 2.

1893 CAMPBELL, HARRY, M.D., 23, Wimpole Street, W., and Coniston Cottage, Fox Lane, Upper Norwood, S.E. (*C.* 1904- .) *C.C.* 4.

1891 CARLESS, ALBERT, M.S., M.B., 10, Welbeck Street, W.

1890 CARR, JOHN WALTER, M.D., 19, Cavendish Place, W. (C. 1903- .) *Trans.* 2, *C.C.* 6.

1901 CARSON, HERBERT WILLIAM, 26, Welbeck Street, Cavendish Square, W.

1901 Carwardine, THOMAS, M.S., 16, Victoria Square, Clifton, Bristol. *Trans.* 1.

1885 CATON, RICHARD, M.D., 86, Rodney Street, Liverpool. *Trans.* 3.

1890 CHAPMAN, CHARLES WILLIAM, M.D., 21, Weymouth Street, W. (C. 1900–3.) *Trans.* 2, *C.C.* 2.

1884 CHAPMAN, PAUL M., M.D., 1, St. John's Street, Hereford. *C.C.* 1.

1893 CHARSLEY, ROBERT STEPHEN, "The Old Barn," Slough.

ELECTED

1885 CHEYNE, W. WATSON, C.B., M.B., C.M., F.R.S., 75, Harley Street, W. (C. 1894–6.) *Trans.* 2, *C.C.* 8.

1873 CHISHOLM, EDWIN, M.D., 44, Roslyn Gardens, Darlinghurst, Sydney, New South Wales.

O.M. **CHURCH**, Sir WILLIAM SELBY, Bart., K.C.B., M.D., 130, Harley Street, W. (C. 1874–6.)

1873 CHURTON, THOMAS, M.D., 35, Park Square, Leeds. (C. 1889–91.) *Trans.* 6.

O.M. CLAPTON, EDWARD, M.D., Towercroft, 41, Eltham Road, Lee, S.E. (C. 1872–4.) *Trans.* 1.

1874 CLARK, ANDREW, 71, Harley Street, W. *Trans.* 1.

1887 CLARK, FRANCIS WILLIAM, Hong-Kong.

1898 CLARKE, JAMES JACKSON, M.B., 18, Portland Place, W. *Trans.* 2, *C.C.* 8.

1885 Clarke, J. MICHELL, M.D., 28, Pembroke Road, Clifton, Bristol.

1885 CLARKE, WILLIAM BRUCE, M.B., 51, Harley Street, W. (C. 1894–7.) *Trans.* 2, *C.C.* 3.

1877 Clay, ROBERT HOGARTH, M.D., 4, Windsor Villas, Plymouth.

1887 CLEMOW, ARTHUR HENRY WEISS, M.D., C.M., 101, Earl's Court Road, W. *Trans.* 1, *C.C.* 1.

1877 **CLUTTON**, HENRY HUGH, M.A., 2, Portland Place, W. (C. 1885–7, V.-P. 1902–4.) *Trans.* 12, *C.C.* 3.

1898 COBB, ERNEST HERBERT, Belmont, Stevenage, Herts.

1893 COLE, ROBERT HENRY, M.D., Moorcroft, Hillingdon, Middlesex.

1882 COLLIER, HERBERT, M.D., 21, South Quay, Great Yarmouth, Norfolk.

1902 COLLINS, VICTOR EVELYN, M.B., Graaff Reinet, Cape Colony.

1896 COLMAN, WALTER STACY, M.D., 9, Wimpole Street, W. (C. 1903– .) *Trans.* 2, *C.C.* 3.

1882 COLQUHOUN, DANIEL, M.D., Dunedin, New Zealand.

1868 COOPER, FRANK W. (address uncommunicated).

1900 COOPER, HARRY, M.D., Fownhope, Surbiton Hill, Surrey.

1903 COOPER, PERCY ROBERT, M.D., "Glenthorn," The Downs, Bowdon, Cheshire.

1902 CORNER, EDRED MOSS, B.Sc., M.B., 126, Harley Street, W. *Trans.* 2, *C.C.* 3.

1880 COTTLE, WYNDHAM, M.D., 39, Hertford Street, W.

O.M. COUPER, JOHN, 80, Grosvenor Street, W. (C. 1874.)

1875 COUPLAND, SIDNEY, M.D., 16, Queen Anne Street, W. (S. 1882–4, C. 1885–7, V.-P. 1898–1901.) *Trans.* 5, *C.C.* 3.

1886 COUSINS, JOHN WARD, M.D., Riversdale, Kent Road, Southsea. *Trans.* 1.

1882 COXWELL, C. F., M.B., Brighton, Melbourne, Victoria. *Trans.* 2.

1897 CRAWFURD, RAYMOND H. P., M.D., 71, Harley Street, Cavendish Square, W. *C.C.* 3.

1879 CRIPPS, WILLIAM HARRISON, 2, Stratford Place, W. (C. 1886–8.) *Trans.* 3.

ELECTED

1872 CRITCHETT, Sir G. ANDERSON, 21, Harley Street, W.

1877 CROCKER, HENRY RADCLIFFE, M.D., 121, Harley Street, W. (C. 1884–5.) *Trans.* 16.

1896 CROOKE-LAWLESS, W. R., Surg.-Maj. A.M.S., M.D., Guards' Club, S.W.

1898 CROUCH, HERBERT CHALLICE, 31, Welbeck Street, Cavendish Square, W.

1893 CURTIS, HENRY JONES, M.D., B.S., 152, Harley Street, W. *C.C.* 1.

1902 CUTHBERT, CHARLES FIRMIN, 2, Barton Street, Gloucester.

1872 DALBY, Sir WILLIAM BARTLETT, M.B., 18, Savile Row, W. (C. 1879–81.) *Trans.* 4.

1896 DALTON, NORMAN, M.D., 4, Mansfield Street, Portland Place, W. (C. 1904.) *Trans.* 3, *C.C.* 7.

1898 DARLEY-HARTLEY, WILLIAM, M.D., Seapoints, Cape Town, South Africa.

1893 DAUBER, JOHN HENRY, M.B., B.Ch., 29, Charles Street, Berkeley Square, W.

1886 DAVIES, ARTHUR T., M.D., 23, Finsbury Square, E.C. (C. 1897–1900.) *C.C.* 13.

1879 DAVY, HENRY, M.D., 29, Southernhay, Exeter.

1889 DEAN, HENRY PERCY, M.B., 69, Harley Street, W.

1897 DEANE, JOHN HENRY, 50, Wallwood Road, Leytonstone, Essex.

1899 DE CHAZAL, EDMOND LUCIEN, M.D., Port Louis, Mauritius.

1903 DELBRUCK, RAOUL ERNEST, M.B., 13, Buckingham Gate, S.W.

1879 Dennis, FREDERIC S., M.D., 542, Madison Avenue, New York, U.S.A.

1875 DENT, CLINTON T., 61, Brook Street, W. (C. 1884–6.) *Trans.* 5. *C.C.* 1.

O.M. DICKINSON, WILLIAM HOWSHIP, M.D., 10, Stanhope Place, Marble Arch, W. (C. 1874–5, V.P. 1888–9.) *Trans.* 2.

1894 Dickson, THOMAS HUGH, M.B., B.C., H.M. Customs, Lower Thames Street, E.C.

1871 DIVER, EBENEZER, M.D., 7, Pittville Terrace, Stamshaw Road, Portsmouth. (C. 1890–2.) *Trans.* 1.

1901 DOUGLAS, JOHN J., M.D., 42, Central Hill, Norwood, S.E.

1868 DRAGE, CHARLES, M.D., Hatfield, Herts.

1896 DREW, DOUGLAS, M.D., B.S., 49, Devonshire Street, Portland Place, W.

O.M. DUCKWORTH, Sir DYCE, M.D., LL.D. 11, Grafton Street, Bond Street, W. (C. 1875–7, V.P. 1887–8, P. 1891–2.) *Trans.* 22, *C.C.* 7.

1902 DUDGEON, LEONARD S., 6, Powis Gardens, Bayswater, W. *C.C.* 2.

1884 DUKE, EDGAR, 11, Wilbury Road, Hove.

1869 DUKE, OLLIVER THOMAS, M.B., Surgeon, Bengal Army, India.

1899 DUNCAN, ANDREW, M.D., 24, Chester Street, Grosvenor Place, S.W. *Trans.* 1.

1889 DUNCAN, JOHN, M.D., St. Petersburg.

1889 DUNN, LOUIS ALBERT, M.S., 51, Devonshire Street, Portland Place, W. (C. 1899–1902.) *Trans.* 2, *C.C.* 2.

ELECTED

1884 EDMUNDS, WALTER, M. C., 2, Devonshire Place, Portland Place, W. (C. 1902– .) *Trans.* 2.

1899 EID, ALFRED, M.D., Cairo, Egypt.

1902 ELLIOT, ANDREW, M.D., 11, Upper Berkeley Street, Portman Square, W.

1882 EMOND, EMILE, M.D., 113, Boulevard Beaumarchais, Paris.

1902 ENGLISH, THOMAS CRISP, 1, Park Crescent, Portland Place, W. *C.C.* 1.

1868 EVANS, JULIAN, M.B., 123, Finborough Road, Redcliffe Square, S.W.

1893 EVANS, WILLMOTT H., M.D., B.S., 2, Upper Wimpole Street, Cavendish Square, W. *C.C.* 1.

1888 **EVE**, FREDERIC S., 125, Harley Street, Cavendish Square, W. (C. 1899–1902.) *Trans.* 5, *C.C.* 10.

1877 **EWART**, WILLIAM, M.D., 33, Curzon Street, W. (C. 1884–6.) *Trans.* 4, *C.C.* 4.

1899 FAGGE, CHARLES HERBERT, M.S., 22, St. Thomas's Street, London Bridge, S.E.

1868 **Fairbank**, FREDERICK ROYSTON, M.D., Westcott, Dorking, Surrey. *Trans.* 2.

1889 FARDON, EDWARD ASHBY, Middlesex Hospital, W.

1900 FAWCETT, JOHN, M.D., 26, St. Thomas's Street, London Bridge, S.E. *Trans.* 1.

1902 FEDDEN, WALTER FEDDE, M.B., 20, Lower Seymour Street, Portman Square, W.

1885 FENN, EDWARD LIVEING, M.D., Alston, Nayland, Colchester.

1902 FENNELL, CHARLES HENRY, M.D., Tooting Bec Asylum, S.W. *C.C.* 1.

1887 FENWICK, E. HURRY, 14, Savile Row, W. *Trans.* 2, *C.C.* 2.

1872 FENWICK, J. C. J., M.D., Long Framlington, Morpeth.

1893 FENWICK, WILLIAM SOLTAU, M.D., 29, Harley Street, W. *Trans.* 2.

1878 FIELD, GEORGE P., 34, Wimpole Street, W.

1876 FINLAY, Prof. DAVID WHITE, M.D., 2, Queen's Terrace, Aberdeen. (C. 1885–7, S. 1891.) *Trans.* 5.

1894 FLETCHER, HERBERT MORLEY, M.D., 98, Harley Street, W. *Trans.* 1.

1878 **FONMARTIN**, HENRY DE, M.D. (Travelling.)

1889 FORBES, DANIEL MACKAY, 5, Bedford Place, West Croydon.

1890 FOSTER, MICHAEL G., M.D., M.A., Villa San Giovanni, San Remo, Italy.

1899 FOWLER, CHARLES OWEN, M.D., Cotford House, Thornton Heath, Surrey.

1881 FOWLER, JAMES KINGSTON, M.D., 35, Clarges Street, W. (C. 1887–9, 1899–1902, S. 1896–9, V.-P. 1904– .) *Trans.* 4, *C.C.* 6.

1886 FOX, R. HINGSTON, M.D., 29, Weymouth Street, Portland Place, W. *C.C.* 1.

1878 FOX, THOMAS COLCOTT, M.B., 14, Harley Street, W. (C. 1888–90.) *Trans.* 7, *C.C.* 2.

1893 FOXWELL, ARTHUR, M.D., 22, Newhall Street, Birmingham.

1902 FRENCH, HERBERT, M.B., 26, St. Thomas's Street, London Bridge, S.E. *C.C.* 1.

ELECTED

1897 FRIPP, Sir ALFRED DOWNING, C.B., M.V.O., M.S., 19, Portland Place, W. (C. 1904– .) *Trans.* 3.

1899 FÜRTH, KARL, M.D., 39, Harley Street, W.

1890 FULLER, HENRY ROXBURGH, M.D., 45, Curzon Street, W.

1897 FURNIVALL, PERCY, 28, Weymouth Street, Portland Place, W.

1891 FYFFE, W. KINGTON, M.B., B.C., 19, Duke Street, Manchester Square, W. (Travelling, New Zealand.) *Trans.* 1.

1888 GAGE-BROWN, CHARLES HERBERT, M.D., 85, Cadogan Place, S.W.

1895 GALLOWAY, JAMES, M.D., 54, Harley Street, W.

1887 GARROD, ARCHIBALD EDWARD, M.A., M.D., 9, Chandos Street, Cavendish Square, W. (C. 1898–1901.) *Trans.* 4, *C.C.* 4.

1879 GARSTANG, THOMAS WALTER HARROPP, Edge Mount, Altrincham.

1903 GATES, EDWARD A., 11, Collingham Road, South Kensington, S.W.

1885 GIBBONS, ROBERT ALEXANDER, M.D., 29, Cadogan Place, S.W. *Trans.* 1.

1893 GIBBS, CHARLES, 115, Harley Street, W.

1868 GLOVER, JAMES GREY, M.D., 25, Highbury Place, N. (C. 1878–80. V.P. 1892–4.) *Trans.* 2.

1893 GLOVER, LEWIS G., M.B., B.C., 17, Belsize Park, Hampstead, N.W.

1875 GODLEE, RICKMAN JOHN, M.S., 19, Wimpole Street, W. (C. 1882–3, 1887–9, S. 1884–6, V.P. 1895–8.) *Trans.* 14, *C.C.* 10.

1901 GOFFE, ERNEST GEORGE LEOPOLD, M.D., Western Hospital, Seagrave Road, Fulham, S.W.

1882 GOLDIE, ROBERT WILLIAM, Hirst House, Hirst, Morpeth, Northumberland.

1878 GOLDING-BIRD, C. H., M.B., 12, Queen Anne Street, W. (C. 1887–9, V.-P. 1903– .) *Trans.* 18, *C.C.* 1.

1894 GOODALL, EDWARD WILBERFORCE, M.D., Eastern Hospital, Homerton, N.E. (C. 1904– .) *Trans.* 7.

1875 GOODHART, JAMES FREDERIC, M.D., 25, Portland Place, W. (C. 1880–2, V.P. 1897–1900.) *Trans.* 14, *C.C.* 2.

1891 GOODMAN, ROGER NEVILLE, M.B., Elmside, Kingston-on-Thames.

1869 GOODRIDGE, HENRY FREDERICK AUGUSTUS, M.D., 10, Brock Street, Bath.

1882 GOODSALL, D. H., 17, Devonshire Place, W.

1877 GOULD, A. PEARCE, M.S., 10, Queen Anne Street, W. (C. 1885–7, 1895–8, S. 1892–5, V.-P. 1898–1901.) *Trans.* 14, *C.C.* 9.

1901 GOWAN, BOWIE CAMPBELL, Raven Dene, Great Stanmore, Middlesex.

1875 GOWERS, Sir WILLIAM RICHARD, M.D., F.R.S., 50, Queen Anne Street W. (C. 1881–2, V.-P. 1903– .) *Trans.* 5, *C.C.* 1.

1891 GRANT, J. DUNDAS, M.D., 18, Cavendish Square, W.

1868 GREEN, T. HENRY, M.D., 74, Wimpole Street, W. (C. 1877–9.) *Trans.* 2, *C.C.* 1.

1875 Greenfield, WILLIAM SMITH, M.D., 7, Heriot Row, Edinburgh. (C. 1881.) *Trans.* 3.

ELECTED

1893 **GRIFFITH**, WALTER SPENCER ANDERSON, M.D., 96, Harley Street, W.

1895 **Grube**, KARL, M.D., Neuenahr, Germany. *Trans.* 1.

1895 GUTHRIE, LEONARD GEORGE, M.D., 15, Upper Berkeley Street, W. *Trans.* 1, *C.C.* 7.

1887 HABERSHON, SAMUEL HERBERT, M.D., 88, Harley Street, W. (C. 1901–4.) *C.C.* 1.

1900 HADLEY, WILFRED J., M.D., 58, Harley Street, Cavendish Square, W.

1875 HALE, C. D. B., 3, Sussex Place, W. *Trans.* 1.

1903 HALL, JOHN BASIL, M.C., 31, Manningham Lane, Bradford.

1878 **HALL**, F. DE HAVILLAND, M.D., 47, Wimpole Street, W. (C. 1885–7, V.-P. 1904– .) *Trans.* 8, *C.C.* 5.

1889 HALSTEAD, GEORGE EZRA, M.D., B.S., Albion Hill House, Ramsgate.

1888 HANDFIELD-JONES, MONTAGU, M.D., 35, Cavendish Square, W.

1886 **Handford**, HENRY, M.D., 6, Regent Street, Nottingham. (C. 1893–4.) *Trans.* 8, *C.C.* 1.

1886 HARDIE, JAMES, M.D., 15, St. John Street, Manchester.

1890 HARPER, JAMES, M.D., 25, Rosary Gardens, South Kensington, S.W.

1872 HARRIS, HENRY, M.D., Trengweath, Redruth, Cornwall.

1889 HARRIS, HERBERT ELWIN, M.B., 13, Lansdown Place, Victoria Square, Clifton, Bristol. *Trans.* 1.

1903 HARRIS, WILFRED, M.D., 37, Queen Anne Street, Cavendish Square, W. *C.C.* 2.

1881 HARRISON, CHARLES EDWARD, M.B., Grenadier Guards Hospital, Rochester Row, S.W.

1892 HARRISON, DAMER, 53, Rodney Street, Liverpool. *Trans.* 1.

1869 **HAWARD**, J. WARRINGTON, 57, Green Street, Grosvenor Square, W. (C. 1876–8, 1884–6, S. 1881–3, V.P. 1888.) *Trans.* 15.

1899 **Hawkes**, CLAUDE SOMERVILLE, Glencairn, Wickham Terrace, Brisbane, Queensland, Australia.

1886 HAWKINS, FRANCIS HENRY, M.D., 73, London Street, Reading. (C. 1902– .) *Trans.* 4, *C.C.* 3.

1889 HAWKINS, HERBERT PENNELL, M.D., B.Ch., 56, Portland Place, W. (C. 1900–3.) *Trans.* 1.

1890 HAWKINS-AMBLER, GEORGE ARTHUR, 30, Rodney Street, Liverpool.

1900 HAYWARD, JOHN ARTHUR, M.D., 23, The Grange, Wimbledon Common, S.W.

1903 HEATH, PHILIP MAYNARD, M.B., 36, Cavendish Square, W.

1879 HENDERSON, GEORGE COURTENAY, M.D., Kingston, Jamaica, West Indies.

1884 HERRINGHAM, WILMOT PARKER, M.D., 40, Wimpole Street, W. (C. 1894–7.) *Trans.* 6, *C.C.* 3.

1897 HILLIER, ALFRED P., M.D., C.M., 30, Wimpole Street, W.

1874 HOLDERNESS, WILLIAM BROWN, 15, Park Street, Windsor.

ELECTED

1868 **Holman**, Sir CONSTANTINE, M.D., 26, Gloucester Place, Portman Square, W. (C. 1894–7.)

1878 HOOD, DONALD WILLIAM CHARLES, M.D., 43, Green Street, Park Lane, W. (C. 1891–3.) *Trans.* 1.

1884 HORSLEY, Sir VICTOR, M.B., F.R.S., 25, Cavendish Square, W. (C. 1894.) *Trans.* 2, *C.C.* 1.

1901 HORTON-SMITH, PERCIVAL, M.D., 19, Devonshire Street, Portland Place, W.

1895 HOUGH, CHARLES HENRY, The Cottage, Clappersgate, Ambleside, Windermere.

1880 **HOVELL**, T. MARK, 105, Harley Street, W. *Trans.* 1.

1893 HOWARD, R. J. BLISS, M.D., 31, Queen Anne Street, W.

1876 HOWSE, Sir HENRY GREENWAY, M.S., 22, Grosvenor Street, Grosvenor Square, W. (C. 1881–3, V.P. 1890–2.) *Trans.* 3.

1902 HULBERT, ERNEST BEDDOE, M.D., 77, Welbeck Street, Cavendish Square, W.

1898 HULKE, SYDNEY BACKHOUSE, Ivy House, Walmer, Kent.

1897 HUMPHRYS, CHARLES B., Eagle House, Blandford, Dorset.

1897 HUNT, GEORGE BERTRAM, M.B., 47, Albemarle Crescent, Scarborough. *Trans.* 1, *C.C.* 1.

1892 HUNTER, WILLIAM, M.D., 103, Harley Street, W.

O.M. HUTCHINSON, JONATHAN, F.R.S., 15, Cavendish Square, W. (C. 1867–8, V.P. 1875–6.) *Trans.* 14, *C.C.* 1.

1896 HUTCHINSON, JONATHAN, jun., 15, Cavendish Square, W. (C. 1902– .) *Trans.* 5, *C.C.* 5.

1893 IONIDES, THEODORE HENRY, M.B., B.S., 25, First Avenue, Brighton.

1883 JACKSON, GEORGE HENRY, Ashburton, Carew Road, Eastbourne.

O.M. JACKSON, J. HUGHLINGS, M.D., F.R.S., 3, Manchester Square, W. (C. 1872–3, V.P. 1887.) *Trans.* 2, *C.C.* 1.

1888 JAMES, JAMES THOMAS, M.D., 30, Harley Street, W.

1901 JOHNSON, EDWARD ANGAS, M.B., B.S., St. Catherine's, Prospect, South Australia.

1889 JOHNSON, RAYMOND, M.B., B.S., 11, Wimpole Street, W. (C. 1900–3.) *Trans.* 5, *C.C.* 6.

1893 JOHNSTON, G. F., M.D., 3, Montagu Place, Montagu Square, W.

1903 JONES, ERNEST LLOYD, 59, Trumpington Street, Cambridge.

1902 JONES, LAWRENCE, 63, Addison Road, W.

1898 Jones, ROBERT, 11, Nelson Street, Liverpool. *Trans.* 2.

1872 JONES, THOMAS RIDGE, M.D., 4, Chesham Place, S.W. (C. 1892–3.)

1876 JORDAN, FURNEAUX, Harborne, Birmingham. *Trans.* 1.

1902 JOWERS, REGINALD F., 55, Brunswick Square, Brighton.

ELECTED

1878 KEETLEY, CHARLES ROBERT BELL, 56, Grosvenor Street, W. (C. 1895–8.) *Trans.* 2.

1898 KELLOCK, THOMAS HERBERT, 8, Queen Anne Street, Cavendish Square, W. (C. 1903– .) *Trans.* 3, *C.C.* 6.

1901 KELYNACK, THEO. N., M.D., 120, Harley Street, W.

1901 KEOGH, Lieut.-Col. ALFRED, C.B., M.D., 18, Victoria Street, S.W.

1897 KEYSER, CHARLES RALPH, 29, Hamilton Terrace, N.W. *C.C.* 3.

1883 KIDD, PERCY, M.D., 60, Brook Street, W. (C. 1891–2, 1902– , S. 1899–1902.) *Trans.* 5, *C.C.* 10.

1887 Knaggs, R. LAWFORD, B.C., 27, Park Square, Leeds. *Trans.* 2.

1878 LACEY, THOMAS WARNER, 196, Burrage Road, Plumstead.

1897 LAMPLOUGH, CHARLES, Chatteris, Cambridgeshire.

1890 LANCASTER, ERNEST LE CRONIER, M.B., B.Ch., Winchester House. Swansea, S. Wales. *Trans.* 2.

1895 LANE, JAMES ERNEST, 46, Queen Anne Street, W. *Trans.* 1.

1883 LANE, WILLIAM ARBUTHNOT, M.B., M.S., 21, Cavendish Square, W. (C. 1893–6.) *Trans.* 29, *C.C.* 10.

O.M. LANGTON, JOHN, 62, Harley Street, W. (C. 1878–80, V.P. 1892–4, P. 1897–9.) *Trans.* 5.

1886 LANKESTER, HERBERT, M.D., Ingleborough, Woking, Surrey.

1885 LARDER, HERBERT, Whitechapel Infirmary, Vallance Road, E. *C.C.* 1.

1893 LAWSON, ARNOLD, M.D., 12, Harley Street, W.

1900 LEAF, CECIL H., M.B., 75, Wimpole Street, Cavendish Square, W.

1877 Lediard, HENRY AMBROSE, M.D., 35, Lowther Street, Carlisle. (C. 1889, V.-P. 1902–4.) *Trans.* 5, *C.C.* 1.

1896 Leech, PRIESTLEY, M.D., King Cross, Halifax.

1877 LEES, DAVID B., M.D., 22, Weymouth Street, W. (C. 1885, V.-P. 1902–4.) *Trans.* 6.

1902 LEGG, THOMAS PERCY, M.B., 141, Harley Street, Cavendish Square, W.

1899 LESLIE, R. MURRAY, M.D., 26, Harley Street, Cavendish Square, W. *C.C.* 1.

1901 LEWERS, ARTHUR HAMILTON NICHOLSON, M.D., 72, Harley Street, Cavendish Square, W.

1892 LEWIS, EDWARD JOHN, M.B., B.C., 74, Hamilton Terrace, N.W.

1895 LEWIS, ERNEST E., M.D., 30, Weymouth Street, W.

1903 LITTLE, E. GRAHAM, M.D., 61, Wimpole Street, W.

1890 LITTLE, JOHN FLETCHER, M.B., 32, Harley Street, W. *C.C.* 5.

1891 LITTLEWOOD, HARRY, 25, Park Square, Leeds. *Trans.* 1.

1875 LIVEING, EDWARD, M.D., 52, Queen Anne Street, W.

1885 LOCKWOOD, CHARLES BARRETT, 19, Upper Berkeley Street, W. (C. 1896–9.) *Trans.* 7.

1876 LONGHURST, ARTHUR EDWIN TEMPLE, M.D., 26, Lower Belgrave Street, Eaton Square, S.W. (C. 1889–91.) *Trans.* 1.

ELECTED

1904 LONGHURST, FREDERIC W., 26, Lower Belgrave Street, Eaton Square, S.W.

1897 LOW, HAROLD, M.B., 10, Evelyn Gardens, South Kensington, S.W.

1899 LOW, V. WARREN, M.D., B.S., 27, Queen Anne Street, Cavendish Square, W.

1881 LUBBOCK, MONTAGU, M.D., 19, Grosvenor Street, W.

1876 LUCAS, R. CLEMENT, M.B., B.S., 50, Wimpole Street, W. (C. 1883–5, V.P. 1901–3.) *Trans.* 11. *C.C.* 1.

1894 LUFF, ARTHUR PEARSON, M.D., 9, Queen Anne Street, Cavendish Square, W.

1879 LUNN, JOHN REUBEN, St. Marylebone Infirmary, Rackham Street, Ladbroke Grove Road, W. (C. 1890–1.) *Trans.* 8, *C.C.* 19.

1893 LYS, HENRY GRABHAM, M.D., Southbrook, Suffolk Road, Bournemouth.

1889 MACBRIDE, P., M.D., 16, Chester Street, Edinburgh.

1891 MACDONALD, GRENVILLE, M.D., 85, Harley Street, W.

1901 MCGAVIN, LAURIE HUGH, 6, Mansfield Street, Cavendish Square, W. *Trans.* 2, *C.C.* 3.

1881 MCHARDY, MALCOLM MACDONALD, 5, Savile Row, W. *Trans.* 1.

1891 MACKENZIE, HECTOR W. G., M.A., M.D., 34, Upper Brook Street, W. (C. 1902– .) *Trans.* 6, *C.C.* 1.

1879 MACKENZIE, SIR STEPHEN, M.D., 18, Cavendish Square, and Merry-court, Gt. Bookham, Leatherhead. (C. 1884, 1888–90, S. 1885–7. V.P. 1900–2.) *Trans.* 9, *C.C.* 10.

1884 MACKERN, JOHN, M.B., St. German's Lodge, Shooter's Hill Road, Blackheath, S.E.

1885 MACLAREN, RODERICK, M.D., Portland Square, Carlisle. *Trans.* 1.

1898 MACREADY, JONATHAN F. C. H., 42, Devonshire Street, Portland Place, W.

1879 MAGILL, JAMES, M.D., M.C., Coldstream Guards, Queen Anne's Mansions, S.W.

1885 MAGUIRE, ROBERT, M.D., 4, Seymour Street, W. *Trans.* 1.

1881 MAKINS, GEORGE HENRY, C.B. (*Treasurer*), 47, Charles Street, Berkeley Square, W. (C. 1892–4, 1898–1901, S. 1895–8, T. 1903– .) *Trans.* 5, *C.C.* 7.

1887 MALCOLM, JOHN D., M.B., C.M., 13, Portman Street, W. (C. 1900–3.) *Trans.* 1, *C.C.* 2.

1890 MANSON, SIR PATRICK, K.C.M.G., M.D., C.M., F.R.S., 21, Queen Anne Street, W. (C. 1895–7.) *C.C.* 1.

1902 MARRIOTT, CECIL, M.B., M.C., 11, Welford Road, Leicester.

1888 Marriott, HYDE, M.B., Dial House, Stockport.

1868 MARSH, Professor F. HOWARD, 14, Hertford Street, Mayfair, W. (C. 1876–7, 1881–3, S. 1878–80, V.P. 1887–8, T. 1899–1901, P. 1901–3.) *Trans.* 18, *C.C.* 7.

1887 MARTIN, SIDNEY, M.D., B.S., F.R.S., 10, Mansfield Street, W. (C. 1896–9.)

1888 MASON, DAVID JAMES, M.D., C.M., Rosemont, Maidenhead.

ELECTED

1892 MASTERS, JOHN ALFRED, M.D., 94, Knightsbridge, S.W.
1884 MAUDSLEY, HENRY CARR, M.D., 22, Collins Street, Melbourne, Victoria.
1897 MAY, CHICHESTER GOULD, M.D., 59, Cadogan Place, S.W.
1868 May, EDWARD HOOPER, M.D., High Cross, Tottenham, Middlesex.
1888 MAY, WILLIAM PAGE, M.D., B.Sc., 9, Manchester Square, W.; and Helouan, nr. Cairo, Egypt (October to April).
1901 MENZIES, F. U., Edinburgh University Union, Edinburgh.
1888 MENZIES, J. HERBERT, 47, Earl's Court Square, S.W.
1893 MERCER, WILLIAM BRACEWELL, M.B., B.C., Cliffe Cottage, Ripponden, near Halifax, Yorks.
1878 MEREDITH, WILLIAM APPLETON, C.M., 21, Manchester Square, W. (C. 1887–9.) *Trans.* 2.
1894 MICHELS, ERNST, M.D., 48, Finsbury Square, E.C.
1873 MICKLE, WILLIAM JULIUS, M.D., Grove Hall Asylum, Bow, E. (C. 1897–1900.)
1890 MILEY, MILES, M.A., M.B., 21, Belsize Avenue, Hampstead, N.W.
1896 MILLS-ROBERTS, ROBERT HERBERT, Llanberis, North Wales. *Trans.* 1.
1882 MONEY, ANGEL, M.D., Hunter Street, Sydney, New South Wales. (C. 1888–90.) *Trans.* 3.
1902 MOON, R. O., M.D., 50, Green Street, Grosvenor Square, W.
1874 MORGAN, JOHN HAMMOND, C.V.O., 68, Grosvenor Street, W. (C. 1883–5, V.P. 1898–1901.) *Trans.* 2, *C.C.* 8.
1888 MORISON, ALEXANDER, M.D., 14, Upper Berkeley Street, W. *Trans.* 2, *C.C.* 1.
1899 MORISON, RUTHERFORD, 14, Saville Row, Newcastle-on-Tyne. *Trans.* 1.
1903 MORLEY, ARTHUR S., 29, Gower Street, W.C.
1877 MORRIS, HENRY, M.A., M.B., 8, Cavendish Square, W. (C. 1884–6, V.P. 1903– .) *Trans.* 9.
1877 MORRIS, MALCOLM ALEX., 8, Harley Street, W. (C. 1890–2.) *Trans.* 1, *C.C.* 1.
1901 MORSE, THOMAS HENRY, All Saints' Green, Norwich. *Trans.* 1.
1902 MORTON, CHARLES ALFRED, 14, Vyvyan Terrace, Clifton, Bristol. *Trans.* 1.
1885 MOTT, FREDERICK WALKER, M.D., F.R.S., 25, Nottingham Place, W. (C. 1895–8.) *Trans.* 1, *C.C.* 4.
1899 MOUAT-BIGGS, CHARLES E. FORBES, 2, Fauconberg Villas, Bayshill, Cheltenham. *C.C.* 2.
1879 MOULLIN, CHARLES W. MANSELL, 69, Wimpole Street, W. (C. 1888–90.) *Trans.* 11, *C.C.* 4.
1900 MOYNIHAN, BERKELEY GEORGE ANDREW, M.S., 33, Park Square, Leeds. (C. 1904– .) *Trans.* 2.
1875 MURPHY, SHIRLEY F., 9, Bentinck Terrace, Regent's Park, N.W. (C. 1888–90.) *C.C.* 1.
1885 MURRAY, ALEXANDER DALTON, M.B., Colombo, Ceylon.

ELECTED

1893 MURRAY, GEORGE REDMAYNE, M.D., 11, Ellison Place, Newcastle-on-Tyne.

1883 MURRAY, HUBERT MONTAGUE, M.D., 25, Manchester Square, W. (C. 1893–6.) *Trans.* 1.

1894 MURRAY, JOHN, 110, Harley Street, W. *C.C.* 1.

1872 MYRTLE, ANDREW S., M.D., 10, Park Parade, Harrogate. (C. 1892.)

1902 NABARRO, DAVID, M.D., 6, Crown Office Row, Inner Temple, E.C.

1892 NASH, WALTER GIFFORD, 31, St. Peter's, Bedford.

1889 Newman, D., M.D., 18, Woodside Place, Glasgow. *Trans.* 4.

O.M. NORTON, ARTHUR TREHERN, C.B., Leyfields Wood, Ashampstead, Berks. (C. 1874–6.) *Trans.* 7.

1880 O'CONNOR, BERNARD, M.D., 25, Hamilton Road, Ealing, W. *Trans.* 1.

1899 OGLE, CYRIL, M.B., 96, Gloucester Place, Portman Square, W. *Trans.* 1.

O.M. OGLE, JOHN WILLIAM, M.D., 96, Gloucester Place, Portman Square, W. (C. 1867–8, V.P. 1884–5.) *Trans.* 6.

1868 Ogle, WILLIAM, M.D., The Elms, Driffield Road, Derby.

1887 Oliver, THOMAS, M.D., 7, Ellison Place, Newcastle-upon-Tyne.

1887 OPENSHAW, THOMAS HORROCKS, M.B., C.M.G., 16, Wimpole Street, W. *Trans.* 1, *C.C.* 4.

1868 OPPERT, FRANZ, M.D., 128, Leipzigerstrasse, Friedenau, Germany. *Trans.* 1.

1889 ORD, W. WALLIS, M.D., B.Ch., The Hall, Salisbury. *Trans.* 1, *C.C.* 1.

1887 ORMEROD, JOSEPH ARDERNE, M.D., 25, Upper Wimpole Street, W. (C. 1899–1902.) *C.C.* 2.

1884 ORMSBY, LAMBERT HEPENSTAL, M.D., 92, Merrion Square West, Dublin.

1877 OWEN, Sir ISAMBARD, M.D., 40, Curzon Street, W. (C. 1888–90.) *Trans.* 4.

1888 OXLEY, ALFRED RICE, M.D., 7, Courtfield Road, South Kensington, S.W.

1888 PAGE, FREDERICK, M.D., 1, Saville Place, Newcastle-on-Tyne.

1875 PAGE, HERBERT W., M.C., M.B., 146, Harley Street, W. (C. 1882–4, V.P. 1899–1902.) *Trans.* 8, *C.C.* 2.

1884 PAGET, STEPHEN, 70, Harley Street, W. (C. 1898–1901.) *Trans.* 8, *C.C.* 3.

1881 PARKER, RUSHTON, M.B., B.S., 59, Rodney Street, Liverpool. (C. 1896–9.) *Trans.* 1, *C.C.* 2.

1890 PARKIN, ALFRED, M.S., 24, Albion Street, Hull. *Trans.* 2.

1894 PARKINSON, JOHN PORTER, M.D., 57, Wimpole street, W. *Trans.* 1, *C.C.* 5.

1898 PARTRIDGE, ARTHUR A. H., M.D., M.Ch., St. Germans, Sutton, Surrey.

1881 PASTEUR, WILLIAM, M.D. (*Hon. Secretary*), 4, Chandos Street, W. (C. 1891–3, S. 1902– .) *Trans.* 7, *C.C.* 5.

ELECTED

1893 PATERSON, DONALD ROSE, M.D., C.M., 15, St. Andrew's Crescent, Cardiff

1900 PATON, EDWARD PERCY, M.S., 84, Park Street, Grosvenor Square, W. *Trans.* 1.

1892 PAUL, FRANK THOMAS, 38, Rodney Street, Liverpool. *Trans.* 1.

1893 PAUL, JOHN ERNEST, M.B., 26, Queensborough Terrace, Kensington Gardens, W. *Trans.* 1.

O.M. PAVY, FREDERICK WILLIAM, M.D., F.R.S., 35, Grosvenor Street, W. (C. 1869–71, V.P. 1882–4.) *Trans.* 3.

1902 PEARSON, S. VERE, M.B., B.C., 31, Grosvenor Street, W. *C.C.* 2.

1879 PEEL, ROBERT, 120, Collins Street East, Melbourne, Victoria.

1886 Penny, WILLIAM JOHN, Coombe, West Crewkerne, Somerset.

1887 PENROSE, FRANCIS GEORGE, M.D., 84, Wimpole Street, W. (C. 1896–9.) *Trans.* 1, *C.C.* 2.

1882 PEPPER, AUGUSTUS JOSEPH, M.S., M.B., 13, Wimpole Street, W, *Trans.* 1.

1900 PERKINS, GEORGE STEELE, M.D., 85, Wimpole Street, W.

1898 PERKINS, J. J., M.D., 41, Wimpole Street, Cavendish Square, W. *Trans.* 1, *C.C.* 1.

1895 PHEAR, ARTHUR G., M.D., B.C., 47, Weymouth Street, Portland Place W. *Trans.* 2.

1895 PHILLIPS, F. B. WILLMER, M.B., 7, Harper Place, Bedford.

1885 PHILLIPS, SIDNEY, M.D., 62, Upper Berkeley Street, W. (C. 1893–6.) *Trans.* 8, *C.C.* 6.

1885 PITT, GEORGE NEWTON, M.D., 15, Portland Place, W. (C. 1894–6.) *Trans.* 7, *C.C.* 5.

1883 PITTS, BERNARD, M.A., M.C., 109, Harley Street, W. (C. 1893.) *Trans.* 5.

1871 Playne, ALFRED, M.B., Maidenhead.

1884 POLLARD, BILTON, B.S., 24, Harley Street, W. (C. 1895–8.) *Trans.* 2.

1868 POLLOCK, JAMES EDWARD, M.D., 37, Collingham Place, S.W. (C. 1878–80.)

1881 POWELL, H. A., M.A., 44, Sandgate Road, Folkestone.

O.M. POWELL, Sir R. DOUGLAS, Bart., K.C.V.O., M.D., 62, Wimpole Street, W. (C. 1874–6, V.P. 1889–90, P. 1899-1901.) *Trans.* 4.

1868 PRENTIS, CHARLES, Surgeon-Major, Bengal Medical Service; India.

1902 PRICE, F. W., M.B., 77, Wimpole Street, W. (C. 1904.)

1884 PRINGLE, JOHN JAMES, M.B., 23, Lower Seymour Street, W. (C. 1890-2, 1897–1900.) *Trans.* 1, *C.C.* 3.

1884 PYE-SMITH, PHILIP HENRY, M.D., F.R.S., 48, Brook Street, W. (C. 1890–2.) *Trans.* 1.

1896 PYE-SMITH, RUTHERFORD JOHN, 350, Glossop Road, Sheffield.

1893 RAKE, ALFRED THEODORE, M.B., B.S., 58, Delancey Street, Regent's Park, N.W.

ELECTED

1895 RAMSAY, HERBERT MURRAY, 35A, Hertford Street, Mayfair, W.
1889 RANKING, JOHN E., M.D., Hanover House, Tunbridge Wells.
1883 READ, THOMAS LAURENCE, 11, Petersham Terrace, Queen's Gate, S.W.
1902 REID, Sir JAMES, Bart., G.C.V.O., K.C.B., 72, Grosvenor Street, Grosvenor Square, W.
1901 REISSMANN, CHARLES, M.D., Knutsford, Glenelg, South Australia.
1899 Rennie, GEORGE EDWARD, M.D., College Street, Hyde Park, Sydney, N.S.W.
1868 RICE, MICHAEL W., M.D., Elmbank, Hargrave, Northamptonshire, (C. 1876–8.)
1898 RICHARDS, JOSEPH STEWART, M.D., B.S., The Infirmary, East Dulwich, S.E. *C.C.* 2.
1903 RIGBY, HUGH, M.S., 7, Wimpole Street, Cavendish Square, W.
O.M. RINGER, SYDNEY, M.D., F.R.S., 15, Cavendish Place, W. (C. 1871–2.) *Trans.* 1.
1896 RISDON, WILLIAM ELLIOT, M.D., 4, Etchingham Park Road, Church End, Finchley, N.
1903 RIVIERE, CLIVE, M.D., 19, Devonshire Street, W. *C.C.* 1.
1873 Roberts, DAVID LLOYD, M.D., 11, St. John Street, Manchester.
1888 ROBERTS, FRANK ERNEST, Tulse Dale Villa, Lower Norwood, S.E.
1883 ROBERTS, FREDERICK THOMAS, M.D., 102, Harley Street, W. (C. 1892–4.)
1900 ROBERTS, GRIFFITH LLOYD, M.B., C.M., Castle Square, Carnarvon, North Wales.
1890 ROBERTSON, ROBERT, M.D., Belgrave Road, Ventnor, Isle of Wight.
1885 ROBINSON, ARTHUR HENRY, M.D., St. Mary's Infirmary, Highgate Hill, N. *C.C.* 3.
1890 ROBINSON, GEORGE SOMERVILLE, Surgeon-Major, Hayes Barton, Bedford Well Road, Eastbourne.
1892 ROBINSON, HENRY BETHAM, M.D., M.S., 1, Upper Wimpole Street, W. (C. 1901–4). *Trans.* 8, *C.C.* 10.
1885 ROBSON, A. W. MAYO, 8, Park Crescent, W., (C. 1893–6.) *Trans.* 15.
1897 ROGER-SMITH, HUGH, M.D., 1, College Terrace, Fitzjohn's Avenue, N.W. *Trans.* 1.
1889 ROLLESTON, HUMPHRY DAVY, M.A., M.D., 55, Upper Brook Street, Grosvenor Square, W. (C. 1899–1902.) *Trans.* 10. *C.C.* 9.
1897 ROSS, FREDERICK WILLIAM FORBES, M.D., 15, Gower Street, W.C.
1877 ROTH, BERNARD, 38, Harley Street, Cavendish Square, and "Wayside," Preston Park Avenue, Brighton. *Trans.* 1, *C.C.* 4.
1890 ROUGHTON, EDMUND WILKINSON, B.S., 38, Queen Anne Street, W. *Trans.* 1, *C.C.* 1.
1874 ROWLAND, EDWARD ROGER, Dordrecht, Wodehouse, S. Africa.
1904 ROWLANDS, R. P., M.S., the College, Guy's Hospital, S.E. *C.C.* 2.
1898 RUSSELL, ALFRED ERNEST, M.D., B.S., 107, Lambeth Palace Road, Albert Embankment, S.E. *C.C.* 1.

ELECTED

1900 RUSSELL, J. S. RISIEN, M.D., 44, Wimpole Street, Cavendish Square, W. *Trans.* 1, *C.C.* 1.

1903 RUSSELL, JAMES WILLIAM, M.D., 72, Newhall Street, Birmingham.

1887 RUTHERFOORD, H. T., M.B., Salisbury House, Taunton.

1885 RYLE, REGINALD JOHN, M.D., 15, German Place, Brighton.

1882 SAINSBURY, HARRINGTON, M.D., 52, Wimpole Street, W. (C. 1898–1901.)

1899 SANDIFER, HENRY STEPHEN, M.D., B.S., 11, Porchester Gardens, W.

1893 SANSOM, ARTHUR ERNEST, M.D., 84, Harley Street, W. *Trans.* 1, *C.C.* 1.

1873 SAVAGE, GEORGE HENRY, M.D., 3, Henrietta Street, W. (C. 1882–3.)

1886 SAVILL, THOMAS DIXON, M.D., 60, Upper Berkeley Street, W. *Trans.* 1, *C.C.* 5.

1899 SCHORSTEIN, GUSTAVE, M.B., 11, Portland Place, W.

1886 SCOTT, ALFRED, 15, German Place, Brighton.

1894 SCOTT, BERNARD, "Hartington," Poole Road, Bournemouth.

1900 SCOTT, KENNETH, M.D., 7, Manchester Square, W.

1892 SCOTT, RICHARD JAMES HERBERT, 28, Circus, Bath. *C.C.* 1.

1902 SEARS, ALFRED ERNEST, 33, Lee Terrace, Blackheath, S.E. *Trans.* 1.

1869 SEDGWICK, LEONARD WILLIAM, M.D., 69, Gloucester Terrace, Hyde Park, W. (C. 1879–81, V.P. 1897–1900.)

1897 SEGUNDO, CHARLES SEMPILL DE, M.B., B.S., 6, Brook Street, Hanover Square, W.

1892 SELWYN-HARVEY, JOHN STEPHENSON, M.D., 1, Astwood Road, S.W.

1878 SEMON, Sir FELIX, C.V.O., M.D., 39, Wimpole Street, W. (C. 1885–7.) *Trans.* 8, *C.C.* 3.

1884 SHARKEY, SEYMOUR J., M.D., 22, Harley Street, W. (C. 1895–8.)

1898 SHAW, HAROLD BATTY, M.D., 7, Devonshire Street, Portland Place, W. *C.C.* 5.

1889 SHAW, LAURISTON ELGIE, M.D., 64, Harley Street, W. *C.C.* 1.

1875 SHERWOOD, ARTHUR PAUL, 8, Seaside Road, Eastbourne.

1886 SILCOCK, ARTHUR QUARRY, M.D., B.S., 52, Harley Street, W. (C. 1896–9.) *Trans.* 5. *C.C.* 2.

1903 SIMPSON, GRAHAM, 1, Bartlett's Passage, Holborn Circus, E.C. *C.C.* 1.

1879 SKERRITT, EDWARD MARKHAM, M.D., Edgecumbe House, Richmond Hill, Clifton, Bristol. (C. 1895–8.) *Trans.* 2.

1872 SLIGHT, GEORGE, M.D., 14, Old Burlington Street, W.

1882 SMITH, E. NOBLE, 24, Queen Anne Street, W. *Trans.* 1.

1896 SMITH, EBENEZER STANLEY, M.D., 68, Wimpole Street, Cavendish Square, W.

1888 SMITH, FREDERICK J., M.D., 138, Harley Street, W. *Trans.* 2.

1884 SMITH, R. PERCY, M.D., 36, Queen Anne Street, Cavendish Square, W. (C. 1898–1901.)

1894 SMITH, THOMAS RUDOLPH, M.B., B.C., 25, Bridge Road, Stockton-on-Tees.

ELECTED

1893 SNAPE, ERNEST ALFRED, M.D., 41, Welbeck Street, W.
1868 SNOW, WILLIAM V., M.D., Richmond Gardens, Bournemouth.
1890 SOLLY, ERNEST, M.B., Strathlea, Harrogate, Yorks. *C.C.* 1.
1888 SPENCER, WALTER GEORGE, M.S., M.B. (*Hon. Secretary*), 35, Brook Street, W. (C. 1896–9. S. 1904– .) *Trans.* 12, *C.C.* 12.
1885 SPICER, FREDERICK, M.D., 17, Wimpole Street, Cavendish Square, W.
1888 SPICER, ROBERT HENRY SCANES, M.D., 28, Welbeck Street, W. *C.C.* 1.
1882 SPOONER, FREDERICK HENRY, M.D., 4, Maitland Place, Lower Clapton, N.E.
1896 SPURRELL, CHARLES, Medical Superintendent, Poplar and Stepney Sick Asylum, Devon's Road, Bromley-by-Bow, E.
1876 SQUIRE, A. BALMANNO, 24, Weymouth Street, W. *Trans.* 5, *C.C.* 4.
1892 STABB, EWEN CARTHEW, 57, Queen Anne Street, W. *C.C.* 1.
1879 STAPLES, FRANCIS PATRICK, Brigade-Surgeon, Army (retired). (Address uncommunicated.)
1896 STEWARD, FRANCIS JAMES, M.B., B.S., 133, Harley Street, W. *Trans.* 2, *C.C.* 1.
1874 Stirling, EDWARD C., M.D. [care of Messrs. ELDER & Co., 7, St. Helen's Place, E.C.], Adelaide, South Australia.
1899 STONE, WILLIAM GREAM, M.D., 93, Denmark Hill, S.E. *C.C.* 1.
1884 STONHAM, CHARLES, C.M.G., 4, Harley Street, W. *C.C.* 3.
1878 STRUGNELL, FREDERICK WILLIAM, Grove End House, Highgate Road, Highgate, N.W. (C. 1903– .) *C.C.* 1.
1878 Sturge, WILLIAM ALLEN, M.D., 29, Boulevard Dubouchage, Nice, France.
1894 SUTHERLAND, GEORGE A., M.D., 73, Wimpole Street, Cavendish Square, W. *Trans.* 1.
1882 SYMONDS, CHARTERS JAMES, M.S., 58, Portland Place, W. (C. 1888–9, 1901–4, S. 1898–1901.) *Trans.* 12, *C.C.* 19.
1876 SYMONDS, HORATIO PERCY, 35, Beaumont Street, Oxford.
1885 TAIT, EDWARD SABINE, M.D., 48, Highbury Park, N.
1885 TAIT, HENRY BREWER, Lincluden, Sunnyside Road, Hornsey Lane, N.
1891 TATE, WALTER WILLIAM HUNT, M.D., 32, Queen Anne Street, W.
1886 TAY, WAREN, 4, Finsbury Square, E.C.
1897 TAYLOR, E. CLAUDE, M.D., B.S., Eland House, Rosslyn Hill, Hampstead, N.W.
1875 TAYLOR, FREDERICK, M.D., (*President*), 20, Wimpole Street, W. (S. 1879–81, C. 1882–4, V.P. 1894–7, T. 1901–3, P. 1903– .) *Trans.* 16, *C.C.* 3.
1889 Taylor, HENRY HERBERT, 10, Brunswick Place, Hove, Sussex.
1890 TAYLOR, JAMES, M.D., 49, Welbeck Street, W. *C.C.* 3.
1882 TAYLOR, SEYMOUR, M.D., 16, Seymour Street, W. *Trans.* 1, *C.C.* 4.
1885 Taylor, W. C. EVERLEY, 34, Queen Street, Scarborough.

ELECTED

1886 TEALE, THOMAS PEIDGIN, M.B., F.R.S., 38, Cookridge Street, Leeds. (C. 1897–1900.)

1896 TEMPLETON, GEORGE, M.B., 10, Seymour Street, Portman Square, W.

1890 THANE, EDGAR HERBERT, M.D., Wagga-Wagga, New South Wales.

1886 THOMPSON, CHARLES HERBERT, M.D., 133, Harley Street, Cavendish Square, W.

O.M. THOMPSON, EDMUND SYMES, M.D., 33, Cavendish Square, W. (C. 1880–2.) *Trans.* 1.

1897 THOMSON, H. CAMPBELL, M.D., 34, Queen Anne Street, Cavendish Square, W. *C.C.* 1.

1894 THOMSON, STCLAIR, M.D., 28, Queen Anne Street, W. *Trans.* 2, *C.C.* 8.

1896 THORNE, WILLIAM BEZLY, M.D., 53, Upper Brook Street, W. *C.C.* 2.

1872 THORNTON, WILLIAM PUGIN, 35, St. George's Road, Canterbury. *Trans.* 5.

1885 THURSFIELD, THOMAS WILLIAM, M.D., Selwood, Beauchamp Square, Leamington.

1899 TILLEY, HERBERT, M.D., 89, Harley Street, Cavendish Square, W. *C.C.* 2.

1891 TOMSON, W. BOLTON, M.D., Park Street West, Luton, Bedfordshire.

1897 TOOGOOD, F. SHERMAN, M.D., The Infirmary, 282, High Street, Lewisham, S.E.

1892 TOOTH, HOWARD HENRY, C.M.G., M.D., 34, Harley Street, W. *Trans.* 1.

1887 TOTSUKA, KANKAI, Tokio, Japan.

1874 TRAVERS, WILLIAM, M.D., 2, Phillimore Gardens, Kensington, W.

1897 TUBBY, ALFRED HERBERT, M.S., 25, Weymouth Street, Portland Place, W. *Trans.* 2, *C.C.* 3.

1900 TULLIS, GEORGE AUGUSTUS, M.D., Holmbush, Grove Road, Southsea.

1882 TURNER, GEORGE ROBERTSON, 41, Half Moon Street, W. (C. 1897–1900.) *Trans.* 9. *C.C.* 6.

1904 TURNER, PHILIP, M.S., 8, St. Thomas's Street, London Bridge, S.E.

1888 TURNER, PHILIP DYMOCK, M.D., Sudbury, Isle of Wight. *Trans.* 1.

1898 TURNER, WILLIAM, M.B., 53, Queen Anne Street, Cavendish Square, W.

1893 TURNEY, HORACE GEORGE, M.D., 68, Portland Place, W. *C.C.* 4.

1878 TYSON, WILLIAM JOSEPH, M.D., 10, Langhorne Gardens, Folkestone. (C. 1886–8, V.-P. 1900–2.) *Trans.* 8.

1881 UHTHOFF, JOHN CALDWELL, M.D., Wavertree House, Brunswick Place, Brighton. (C. 1898–1901.)

1868 VENNING, EDGCOMBE, 30, Cadogan Place, S.W. (C. 1876–8.) *Trans.* 2.

1890 VOELCKER, ARTHUR FRANCIS, M.D., B.S., 101, Harley Street, W. (C. 1900–3.) *Trans.* 2, *C.C.* 2.

1868 WAGSTAFFE, WILLIAM WARWICK, Purleigh, St. John's Hill, Sevenoaks. (C. 1878.)

1886 **WAINEWRIGHT**, BENJAMIN, M.B., C.M. (address uncommunicated).

1885 WAKLEY, THOMAS, jun., 16, Hyde Park Gate, S.W.

ELECTED

1899 WALKER, HENRY ROE, 8, Harley Street, W.

1896 WALLACE, CUTHBERT SYDNEY, M.B., 26, Upper Wimpole Street, W. (C. 1902– .) *Trans.* 6, *C.C.* 5.

1890 WALLIS, FREDERICK CHARLES, M.B., B.C., 107, Harley Street, W. (C. 1902– .) *Trans.* 5, *C.C.* 10.

1888 WALTERS, FREDERICK RUFENACHT, M.D., Crooksbury Sanatorium, Farnham, Surrey. *C.C.* 2.

1896 WARD, EDWARD, M.B., 22, Park Place, Leeds. *Trans.* 1.

1904 WARING, HOLBURT J., M.S., 37, Wimpole Street, Cavendish Square, W.

1888 Warner, PERCY, Rydal, Woodford Green, Essex.

1891 WATERHOUSE, HERBERT FURNIVALL, M.D., C.M., 81, Wimpole Street, W.

1902 WATSON, CHARLES GORDON, 44, Welbeck Street, Cavendish Square, W. *C.C.* 1.

1896 WEBER, FRED. PARKES, M.D., 19, Harley Street, W. *Trans.* 2, *C.C.* 10.

O.M. WEBER, Sir HERMANN D., M.D., 10, Grosvenor Street, W. (C. 1867–71, V.P. 1873–5.) *Trans.* 9.

1882 WEST, SAMUEL, M.D., 15, Wimpole Street, W. (C. 1887–9.) *Trans.* 16, *C.C.* 5.

1895 WETHERED, FRANK J., M.D., 83, Harley Street, W.

1874 WHEELHOUSE, CLAUDIUS GALEN, Cliffe Point, Filey, Yorks. *Trans.* 1.

1891 WHITE, CHARLES PERCIVAL, M.B., B.C., 22, Cadogan Gardens, S.W.

1882 WHITE, EDWIN FRANCIS, Westlands, 280, Upper Richmond Road, Putney, S.W.

1890 WHITE, GILBERT B. MOWER, M.B., B.S., 112, Harley Street, W.

1883 WHITE, WILLIAM HALE, M.D. 65, Harley Street, W. (C. 1887–9, 1896–9, S. June, 1893–6.) *Trans.* 16, *C.C.* 4.

1883 WHITE, WILLIAM HENRY, M.D., 43, Weymouth Street, W. *Trans.* 1. *C.C.* 1.

1894 WHITELOCKE, RICHARD HENRY ANGLIN, M.B., C.M., 6, Banbury Road, Oxford.

1897 WHITFIELD, ARTHUR, M.D., 21, Bentinck Street, Manchester Square, W.

1897 WHITING, ARTHUR JOHN, M.D., 142, Harley Street, W.

1882 WHITTLE, EDWARD GEORGE, M.D., 9, Regency Square, Brighton.

1871 WIGHT, GEORGE, M.B., C.M., 428, Liverpool Road, N.

1879 WILCOX, HENRY, M.B., Newlyn, Fleet, Hants.

1894 WILKIN, GRIFFITH CHARLES, Conway House, Paignton, South Devon.

1884 WILLCOCKS, FREDERICK, M.D., 14, Mandeville Place, W. *C.C.* 1.

O.M. WILLETT, ALFRED, 36, Wimpole Street, W. (C. 1872–5, V.P. 1889–91.) *C.C.* 2.

1890 WILLETT, EDGAR, M.B., 22, Queen Anne Street, Cavendish Square, W.

1888 WILLIAMS, CAMPBELL, 18, Queen Anne Street, Cavendish Square, W. *Trans.* 2.

ELECTED

O.M. WILLIAMS, CHARLES THEODORE, M.D., 2, Upper Brook Street, W. (C. 1877–9, V.P. 1889–90.) *Trans.* 8.

1888 WILLIAMS, DAWSON, M.D., 2, Agar Street, Strand, W.C. (C. 1893–7.)

1903 WILLIAMS, LEONARD, M.D., 8, York Street, Portman Square, W. *C.C.* 1.

1890 WILLIAMS, W. ROGER, Beaufort House, Clifton Down, Clifton, Bristol.

O.M. WILLIS, FRANCIS, M.D., The Spa, Braceborough, Stamford.

1893 WILLS, JOSEPH PEARCE BUDGETT, M.D., Chintings, Bexhill-on-Sea.

1889 WILLS, WILLIAM ALFRED, M.D., 29, Lower Seymour Street, W.

1886 WILSON, ALBERT, M.D., Minto House, South Woodford, Essex. *Trans.* 1, *C.C.* 2.

1888 Wilson, CLAUDE, M.D., C.M., Belmont, Tunbridge Wells. *Trans.* 2.

1891 WILSON, THEODORE STACEY, M.D., C.M., 27, Wheeley's Road, Edgbaston, Birmingham. *Trans.* 2.

1890 WOOD, NEVILLE, 42, Elvaston Place, Queen's Gate, S.W.

1883 WOODCOCK, JOHN ROSTRON, Darlington Court, North Road, Bath.

1879 WOODWARD, GEORGE P. M., M.D., Deputy Surgeon-General; Sydney, New South Wales.

1894 WOOLLETT, CHARLES JEROME, "Ambleside," Streatham, S.W.

1884 WORTS, EDWIN, 6, Trinity Street, Colchester.

1892 WYNTER, WALTER ESSEX, M.D., B.S., 27, Wimpole Street, Cavendish Square, W. *C.C.* 4.

1872 YEO, I. BURNEY, M.D., 44, Hertford Street, W. (C. 1881–3.) *Trans.* 8.

[*It is requested that any change of Title or Residence be communicated to the Secretaries before the* 1*st of July in each year, in order that the list may be made as correct as possible.*]

LIST OF MEMBERS.

ORIGINAL MEMBERS (ALPHABETICALLY).

Henry Arnott.
Richard Barwell.
Henry Charlton Bastian, M.D., F.R.S.
Sir Wm. Henry Broadbent, Bart., K.C.V.O., M.D., F.R.S.
Thomas Bryant.
Thomas Buzzard, M.D.
Sir William Selby Church, Bart., K.C.B., M.D.
Edward Clapton, M.D.
John Couper.
William Howship Dickinson, M.D.
Sir Dyce Duckworth, M.D.
Christopher Heath.
Timothy Holmes.
Jonathan Hutchinson, F.R.S.
J. Hughlings Jackson, M.D., F.R.S.
John Langton.
Arthur Trehern Norton, C.B.
John William Ogle, M.D.
Frederick William Pavy, M.D., F.R.S.
Sir Richard Douglas Powell, Bart., M.D., K.C.V.O.
Sydney Ringer, M.D., F.R.S.
Sir Thomas Smith, Bart., K.C.V.O.
Edmund Symes Thompson, M.D.
Sir Hermann D. Weber, M.D.
Alfred Willett.
Charles Theodore Williams, M.D.
Francis Willis, M.D.

ARRANGED ACCORDING TO DATE OF ELECTION.

1868 Sir Constantine Holman, M.D.
Christian G. H. Bäumler, M.D.
James Grey Glover, M.D.
T. Henry Green, M.D.
Howard Marsh.
Charles Prentis.
Edgcombe Venning.
John Ford Anderson, M.D.

1868 George Granville Bantock, M.D.
George Charles Bright, M.D.
Frank W. Cooper.
Julian Evans, M.B.
Edward Hooper May, M.D.
William Warwick Wagstaffe.
William Ogle, M.D.
James Edward Pollock, M.D.

1868 Franz Oppert, M.D.
William V. Snow, M.D.
Charles Drage, M.D.
Frederick Royston Fairbank, M.D.
Michael W. Rice, M.D.
1869 Leonard William Sedgwick, M.D.
J. Warrington Haward.
Henry Frederick Augustus Goodridge, M.D.
Olliver Thomas Duke, M.B.
1871 Alfred Playne, M.B.
George Wight, M.B.
Ebenezer Diver, M.D.
1872 I. Burney Yeo, M.D.
Henry Harris, M.D.
William Pugin Thornton.
Sir G. Anderson Critchett.
J. C. J. Fenwick, M.D.
Andrew S. Myrtle, M.D.
Sir William Bartlett Dalby.
Thomas Ridge Jones, M.D.
George Slight, M.D.
1873 William Julius Mickle, M.D.
David Lloyd Roberts, M.D.
George Henry Savage, M.D.
Edwin Chisholm, M.D.
Thomas Churton, M.D.
1874 John Hammond Morgan, C.V.O.
Edward R. Rowland.
Claudius Galen Wheelhouse.
Edward C. Stirling, M.D.
Sir William Henry Bennett, K.C.V.O.
William Travers, M.D.
William Brown Holderness.
Andrew Clark.
1875 Sir Thomas Barlow, Bart., K.C.V.O., M.D.
Sidney Coupland, M.D.
Clinton T. Dent.
C. D. B. Hale.
Edward Liveing, M.D.
Rickman John Godlee, M.S.
Arthur Paul Sherwood.
James Frederic Goodhart, M.D.
Sir William Richard Gowers, M.D., F.R.S.
William Smith Greenfield, M.D.
Shirley F. Murphy.
Herbert W. Page.
Frederick Taylor, M.D.
1876 Arthur E. J. Barker.
1876 Horatio Percy Symonds.
A. Balmanno Squire.
David White Finlay, M.D.
Sir Henry Greenway Howse, M.S.
Furneaux Jordan.
R. Clement Lucas, B.S.
George Buckston Browne.
Arthur Edwin Temple Longhurst, M.D.
1877 Robert Hogarth Clay, M.D.
A. Pearce Gould, M.S.
Henry Radcliffe Crocker, M.D.
David B. Lees, M.D.
Sir Isambard Owen, M.D.
William Ewart, M.D.
Henry Morris, M.B.
Henry Ambrose Lediard, M.D.
Bernard Roth.
Henry Hugh Clutton.
Malcolm Alex. Morris.
1878 George P. Field.
Thomas Warner Lacey.
Thomas Colcott Fox, M.B.
Sir Felix Semon, C.V.O., M.D.
Henry de Fonmartin, M.D.
C. H. Golding-Bird, M.B.
Donald William Charles Hood, M.D.
Lord Lister, P.C., O.M., F.R.S.
F. de Havilland Hall, M.D.
William Allen Sturge, M.D.
William Joseph Tyson, M.D.
Charles Robert Bell Keetley.
William Appleton Meredith, C.M.
Robert Bridges, M.B., M.A.
Frederick William Strugnell.
1879 William Edward Burton.
James Magill, M.D.
Edward Markham Skerritt, M.D.
Henry Wilcox, M.B.
John Abercrombie, M.D.
Sir Stephen Mackenzie, M.D.
William Harrison Cripps.
Francis Patrick Staples.
Geo. Courtenay Henderson, M.D.
Henry Davy.
Thos. Walter Harropp Garstang.
Charles W. Mansell Moullin.
John Reuben Lunn.
George P. M. Woodward, M.D.
Robert Peel.
Frederic S. Dennis, M.D.

1880 T. Mark Hovell.
Wyndham Cottle, M.D.
Henry Francis Baker.
Bernard O'Connor, M.D.
Charles Edward Beevor, M.D.
1881 George Henry Makins, C.B.
Robert William Burnet, M.D.
James Kingston Fowler, M.D.
Charles Edward Harrison, M.B.
Malcolm Macdonald McHardy.
Rushton Parker.
Montagu Lubbock, M.D.
William Pasteur, M.D.
John Caldwell Uhthoff, M.D.
Henry Treutham Butlin.
H. A. Powell, M.A.
1882 George Robertson Turner.
E. Noble Smith.
Robert William Goldie.
Frederick Charles Barker, M.D.
Daniel Colquhoun, M.D.
Seymour Taylor, M.D.
Philip Henry Bindley, M.B.
Edward George Whittle, M.D.
D. H. Goodsall.
Frederick Henry Spooner, M.D.
Frederick Haycraft Berry, M.D.
Herbert Collier, M.D.
Samuel West, M.D.
Emile Emond, M.D.
Charters James Symonds, M.S.
Angel Money, M.D.
C. F. Coxwell, M.B.
Augustus Joseph Pepper, M.B.
Harrington Sainsbury, M.D.
Edwin Francis White.
1883 Anthony A. Bowlby, C.M.G.
Percy Kidd, M.D.
William Henry White, M.D.
Hubert Montague Murray, M.D.
Robert Fitzroy Benham.
William Henry Allchin, M.D.
John Mitchell Bruce, M.D.
William Arbuthnot Lane, M.S.
Bernard Pitts.
William Hale White, M.D.
William Coode Adams, M.B.
Robert Leamon Bowles, M.D.
George Henry Jackson.
Thomas Laurence Read.
Frederick Thomas Roberts, M.D.
Charles Alfred Ballance, M.B., M.S.
John Rostron Woodcock.
1884 Frederick Willcocks, M.D.
R. Percy Smith, M.D.
Edgar Duke.
John Mackern, M.B.
Paul M. Chapman, M.D.
Wilmot Parker Herringham, M.D.
Philip Henry Pye-Smith, M.D., F.R.S.
Charles Stonham, C.M.G.
Dudley Wilmot Buxton, M.D.
Edwin Worts.
Seymour J. Sharkey, M.D.
John James Pringle, M.B.
Frederick Lucas Benham, M.D.
Walter Edmunds, M.C.
Stephen Paget.
Lambert Hepenstal Ormsby, M.D.
Edwin Leonard Adeney, M.D.
Sir Victor Horsley, F.R.S.
Henry Carr Maudsley, M.D.
Bilton Pollard, B.S.
1885 Frederick Spicer, M.B.
Herbert Larder.
James Berry, B.S.
Fred. Walker Mott, M.D., F.R.S.
George Newton Pitt, M.D.
W. C. Everley Taylor.
Sidney Phillips, M.D.
A. W. Mayo Robson.
Thomas Wakley, jun.
Herbert William Allingham.
Thomas William Thursfield, M.D.
Alexander Dalton Murray, M.B.
Robert Maguire, M.D.
Robert Alexander Gibbons, M.D.
Henry Brewer Tait.
Richard Caton, M.D.
Arthur Henry Robinson, M.D.
Edward Sabine Tait, M.B.
William Bruce Clarke, M.B.
Charles Barrett Lockwood.
Reginald J. Ryle, M.D.
J. Michell Clarke, M.D.
Henry George Armstrong.
Roderick Maclaren, M.D.
W. Watson Cheyne, C.B.. F.R.S.
Edward Liveing Fenn, M.D.
1886 Thomas Dixon Savill, M.D.
Benjamin Wainewright, M.B.
Waren Tay.
William John Penny.
William Henry Battle.
James Hardie, M.D.

1886 Francis Henry Hawkins, M.D.
R. Hingston Fox, M.D.
John Ward Cousins, M.D.
T. Pridgin Teale, F.R.S.
H. Lankester, M.D.
Arthur T. Davies, M.D.
Charles Herbert Thompson, M.D.
Arthur Quarry Silcock, M.D., B.S.
Henry Handford, M.D.
Alfred Scott.
Albert Wilson, M.D.

1887 Archibald E. Garrod, M.D.
H. T. Rutherfoord, M.B.
Kankai Totsuka.
Thomas Oliver, M.D.
Francis George Penrose, M.D.
Samuel Herbert Habershon, M.D.
Oswald Auchinleck Browne, M.D.
Joseph Arderne Ormerod, M.D.
J. H. E. Brock, M.D., B.S.
Francis William Clark.
A. H. Weiss Clemow, M.D., C.M.
E. Hurry Fenwick.
R. Lawford Knaggs, B.C.
John D. Malcolm, M.B., C.M.
Sidney Martin, M.D., B.S., F.R.S.
Thomas Horrocks Openshaw, C.M.G., M.B.

1888 A. G. Barrs, M.D.
J. W. Batterham, M.B., B.S.
Montagu Handfield-Jones, M.D.
Alfred Rice Oxley, M.D.
Robert Henry Scanes Spicer, M.D.
Campbell Williams.
Frederic S. Eve.
Alexander Morison, M.D.
Frederick Page, M.D.
Frederick J. Smith, M.D.
Frederick R. Walters, M.D.
Claude Wilson, M.D., C.M.
Charles H. Gage-Brown, M.D.
J. H. Menzies.
Frank Ernest Roberts.
Robert Ashton Bostock.
Hugh Armstrong.
Hyde Marriott, M.B.
Percy Warner.
J. T. James, M.D.
Edwin A. Barton.
W. Page May, M.D.
Philip D. Turner, M.D.
Dawson Williams, M.D.
Augustus W. Addinsell, M.B., C.M.

1888 John Anderson, M.D.
Henry French Banham, M.D.
David James Mason, M.D., C.M.
Walter G. Spencer, M.B., M.S.

1889 Theodore Dyke Acland, M.D.
Raymond Johnson, M.B., B.S.
H. D. Rolleston, M.A., M.D.
P. MacBride, M.D.
D. Newman, M.D.
Herbert Elwin Harris, M.B.
John E. Ranking, M.D.
William Alfred Wills, M.D.
Edward Ashby Fardon.
Stanley Boyd, B.S.
George Ezra Halstead, M.D., B.S.
Henry Herbert Taylor.
John Duncan, M.D.
Wm. Wallis Ord, M.D., B.Ch.
Leonard Arthur Bidwell.
Arthur J. M. Bentley, M.D.
Francis R. B. Bisshopp, M.B., B.Sc.
Henry Percy Dean, M.B.
Louis Albert Dunn, M.S.
Daniel Mackay Forbes.
Herbert Pennell Hawkins, M.D., B.Ch.
Lauriston Elgie Shaw, M.D.

1890 John Rose Bradford, M.D., F.R.S.
J. Fletcher Little, M.B.
Robert Robertson, M.D.
Ernest Solly, M.B.
James Taylor, M.D.
Francis O. Buckland, B.A., M.B., C.M.
G. Somerville Robinson.
Edmund W. Roughton, B.S.
Edgar Willett, M.B.
James Calvert, M.D.
H. Roxburgh Fuller, M.D.
Arthur F. Voelcker, M.D.
Neville Wood.
W. Roger Williams.
Gilbert B. M. White, M.B., B.S.
Frederick Charles Wallis, M.B., B.C.
Alfred Parkin, M.S.
George A. Hawkins-Ambler.
James Harper, M.D.
Walter Henry Brown.
John Walter Carr, M.D.
Ernest Le Cronier Lancaster, M.B., B.Ch.

1890 Sir Patrick Manson, K.C.M.G., M.D., F.R.S.
Miles Miley, M.A., M.B.
Edgar Herbert Thane, M.B.
Charles William Chapman, M.D.
Michael G. Foster, M.A., M.D.
1891 Frederic François Burghard, M.D., M.S.
Roger Neville Goodman, M.B.
Herbert Furnivall Waterhouse, M.D., C.M.
Walter William Hunt Tate, M.D.
Greville MacDonald, M.D.
J. Kingston Barton.
J. Dundas Grant, M.D.
W. Kington Fyffe, M.B., B.C.
Albert Carless, M.B., M.S.
W. Bolton Tomson, M.D.
Harry Littlewood, M.D.
Hector W. G. Mackenzie, M.A., M.D.
Chas. Percival White, M.B., B.C.
Arnold Caddy.
Theodore Stacey Wilson, M.D., C.M.
1892 William Hunter, M.D.
Frank Thomas Paul.
Walter Essex Wynter, M.D., B.S.
Damer Harrison.
John Alfred Masters, M.D.
Walter Gifford Nash.
John Stephenson Selwyn-Harvey, M.D.
Ewen Carthew Stabb.
Edward John Lewis, M.B., B.C.
Henry Betham Robinson, M.D. M.S.
Richard James Herbert Scott.
Howard Henry Tooth, C.M.G., M.D.
1893 John Ernest Paul, M.B.
James William Bond, M.D.
Harry Campbell, M.D.
W. Soltau Fenwick, M.D.
Ernest Alfred Snape, M.D.
Lewis G. Glover, M.B., B.C.
William Bracewell Mercer, M.B., B.C.
Robert Henry Cole, M.D.
Donald Rose Paterson, M.D., C.M.
Walter Spencer Anderson Griffith, M.D.
1893 Alfred Theodore Rake, M.B., B.S.
James William Browne, M.B.
George Redmayne Murray, M.D., M.A.
R. J. Bliss Howard, M.D.
Henry Jones Curtis, M.D., B.S.
Henry Albert Caley, M.D.
John Henry Dauber, M.B.
Theodore Henry Ionides, M.B., B.S.
Arthur Foxwell, M.D.
Horace George Turney, M.D.
Henry Grabham Lys, M.D.
Arthur Ernest Sansom, M.D.
John Henry Bryant, M.D.
G. F. Johnston, M.D.
Willmott H. Evans, M.D., B.S.
Charles Gibbs.
Robert Stephen Charsley.
Joseph Pearce Budgett Wills, M.D.
Arnold Lawson, M.D.
1894 Herbert Morley Fletcher, M.D.
Edward Wilberforce Goodall, M.D.
Harry Gilbert Barling.
Ernst Michels, M.D.
Charles Jerome Woollett.
StClair Thomson, M.D.
George A. Sutherland, M.D.
John Murray.
Richard Henry Anglin Whitelocke, M.B., C.M.
John Attlee, M.D., B.C.
Griffith Charles Wilkin.
Thomas Hugh Dickson, M.B., B.C.
C. Gordon Brodie.
Bernard Scott.
John Porter Parkinson, M.D.
Thomas Rudolph Smith, M.B., B.C.
Arthur Pearson Luff, M.D.
1895 Herbert Murray Ramsay.
Arthur G. Phear, M.D., B.C.
Ernest E. Lewis, M.D.
Karl Grube, M.D.
Gerald R. Baldwin.
James Galloway, M.D.
F. B. Willmer Phillips, M.B.
Charles Henry Hough.
Leonard George Guthrie, M.D.
James Ernest Lane.
Frank J. Wethered, M.D.

1895 Richard Ackerley.
1896 Charles Spurrell.
Cuthbert Sidney Wallace, M.B.
Charles R. Box, M.D.
Walter Stacy Colman, M.D.
Edward Ward, M.B.
Norman Dalton, M.D.
Fred. Parkes Weber, M.D.
Francis James Steward, M.B., B.S.
William Bezly Thorne, M.D.
Douglas Drew, M.D., B.S.
Surg.-Capt. W. R. Crooke-Lawless, A.M.S., M.D.
William Elliot Risdon, M.D.
Priestley Leech, M.D.
Ebenezer Stanley Smith, M.D.
G. H. A. Comyns Berkeley, M.B.
Edward Cooper Bentham.
Robert Herbert Mills-Roberts.
Jonathan Hutchinson, jun.
Frederick E. Batten, M.D.
Rutherford John Pye-Smith.
George Templeton.
Bertram Louis Abrahams, M.B., B.Sc.
1897 Raymond H. P. Crawfurd, M.D.
John Henry Deane.
Percy Furnivall.
Arthur Whitfield, M.D.
Frederick William Forbes Ross, M.D.
Harold Low, M.B.
Charles Ralph Keyser.
George Bertram Hunt, M.B.
Hugh Roger-Smith, M.D.
Alfred Herbert Tubby, M.S.
Charles Lamplough.
H. Campbell Thomson, M.D.
Alfred P. Hillier, M.D., C.M.
F. Sherman Toogood, M.D.
E. Claude Taylor, M.D.
Charles Humphrys.
Charles Sempill de Segundo, M.B.
Arthur John Whiting, M.D.
Sir Alfred Downing Fripp, C.B., M.V.O, M.S.
Chichester Gould May, M.D.
1898 J. J. Perkins, M.D.
James Jackson Clarke, M.B.
Ernest Herbert Cobb.
Sydney Backhouse Hulke.
Thomas Herbert Kellock.
1898 William Darley-Hartley.
Robert Jones.
Arthur Philip Beddard, M.D.
Alfred Ernest Russell, M.D. B.S.
William Cecil Bosanquet, M.D.
Jonathan F. C. H. Macready.
Arthur A. H. Partridge, M.B., M.Ch.
Leonard Avery.
Herbert Challice Crouch.
William Turner, M.B., B.S.
Harold Batty Shaw, M.D.
Joseph Stewart Richards, M.D., B.S.
William Henry Breffit Brook, M.D., B.S.
1899 George Edward Rennie, M.D.
V. Warren Low, M.D., B.S.
Rayner Derry Batten, M.D., B.S.
Charles E. Forbes Mouat-Biggs.
Rutherford Morison.
R. Murray Leslie, M.D.
Herbert Tilley, M.D.
Charles Owen Fowler, M.D.
Cyril Ogle, M.B.
Charles Herbert Fagge, M.S.
Claude Somerville Hawkes.
Henry Stephen Sandifer, M.D., B.S.
Marcus Marwood Bowlan, M.B., B.Sc.
Alfred Eïd, M.D.
Karl Fürth, M.D.
Wm. Gream Stone, M.D.
Andrew Duncan, M.D.
Edmond Lucien De Chazal, M.D.
Henry Roe Walker.
Gustave Schorstein, M.B.
Edward Collingwood Andrews, M.D.
1900 Berkeley George Andrew Moynihan, M.S.
Harry Cooper, M.D.
George Augustus Tullis, M.D.
Griffith Lloyd Roberts, M.B., C.M.
Edward Percy Paton, M.S.
Kenneth Scott, M.D.
George Steele Perkins, M.D.
John Arthur Hayward, M.D.
Wilfred J. Hadley, M.D.

1900 John Fawcett, M.D.
Arthur Bousfield, M.B.
J. S. Risien Russell, M.D.
Cecil H. Leaf, M.B.
Josef Paul Zum Busch, M.D.
1901 Ernest George Leopold Goffe, M.D.
Arthur Hamilton Nicholson Lewers, M.D.
Charles Reissmann, M.D.
Adrian Caddy, M.B.
Herbert William Carson.
Thomas Henry Morse.
Laurie Hugh McGavin.
F. U. Menzies.
Thomas Rupert Hampden Bucknall, M.S.
Edward Angas Johnson, M.B.
Percival Horton-Smith, M.D.
Sir Hugh Reeve Beevor, Bart., M.D.
Theo. N. Kelynack, M.D.
Thomas Carwardine, M.S.
Bowie Campbell Gowan.
John J. Douglas, M.D.
Lieut.-Col. Alfred Keogh, C.B., M.D.
Harold Shuttleworth Barwell.
1902 Charles Henry Fennell, M.D.
Harold L. Barnard.
Thomas Percy Legg, M.B.
Andrew Elliot, M.D.
Sir James Reid, Bart., G.C.V.O., K.C.B.
F. W. Price, M B.
Alfred Ernest Sears.
Reginald F. Jowers.
Cecil Marriott, M.B.
Edward Farquhar Buzzard, M.D.
1902 Donald John Armour, M.B.
Edred Moss Corner, B.Sc., M.B.
Herbert French, M.B.
S. Vere Pearson, M.B., B.C.
Lawrence Jones, M.B.
Thomas Crisp English.
Ernest Beddoe Hulbert, M.D.
Walter Fedde Fedden, M.B.
David Nabarro, M.D.
Charles A. Morton.
Victor Evelyn Collins, M.B.
Leonard S. Dudgeon.
R. O. Moon, M.D.
Charles Gordon Watson.
Charles Firmin Cuthbert.
1903 Raoul Ernest Delbruck, M.B.
Clive Riviere, M.D.
Edward A. Gates, M.D.
E. Graham Little, M.D.
Percy Robert Cooper, M.D., B.Sc.
Leonard Williams, M.D.
Ernest Lloyd Jones, M.D.
John Basil Hall, M.C.
Thomas Reuell Atkinson, M.D.
Graham Simpson.
Edgar Beaumont.
James William Russell, M.D.
Philip Maynard Heath, M.B.
Wilfred Harris, M.D.
Arthur S. Morley.
Hugh Rigby, M.S.
1904 Holburt J. Waring, M.S.
Charles Bolton, M.D.
R. P. Rowlands, M.S.
H. A. Ballance, M.S.
Frederic W. Longhurst.
H. S. D. Browne, M.B., B.C.
Philip Turner.

REPORT

OF THE

COUNCIL OF THE CLINICAL SOCIETY,

MAY, 1904.

THE COUNCIL has to report the continued prosperity of the Society.

The number of Ordinary Members now stands at 599. Fourteen new Members have been elected during the current year.

Sir Thomas Smith, Bart., K.C.V.O., until lately one of the Original Ordinary Members, has been elected an Honorary Member.

Thirteen other Ordinary Members have resigned, and the Society has to regret the loss of five members through death, namely, Sir Henry Thompson, an Original Member and a former Vice-President; Mr. George Lawson, an Original Member; Mr. W. J. Walsham, a former Vice-President; Mr. Knowsley Thornton; and Mr. C. H. Wade.

The finances of the Society remain in a satisfactory condition, the receipts again showing a small balance on the credit side.

THE CLINICAL SOCIETY OF LONDON.

Statement of Cash Receipts and Payments from the 1st May, 1903, to the 30th April, 1904.

G. H. MAKINS, Esq., C.B., *Treasurer.*

RECEIPTS.	£	s.	d.
Balance, 1st May, 1903	131	9	0
172 Subscriptions received by Collector £180 12 0			
185 „ „ Bank 194 5 0			
357	374	17	0
15 Subscriptions at 10*s.* 6*d.*	7	17	6
10 Admission Fees at £2 2*s.*	21	0	0
3 „ „ at £1 1*s.*	3	3	0
1 Composition Fee	5	5	0
Sale of *Transactions*	13	19	1
Dividend on Consols (£640)	15	5	4
	£572	15	11

PAYMENTS.	£	s.	d.	£	s.	d.
Cost of *Transactions*, Vol. XXXVI:						
Printing, paper, binding, delivery, &c.	£140	17	1			
Illustrations	23	15	6			
				164	12	7
Meetings:						
Rent of Rooms	105	0	0			
Hire of Microscopes and Lanterns	6	18	6			
Hire of Epidiascope	1	6	0			
A. Tapson (attendance)	7	0	0			
Refreshments	33	8	0			
				153	12	6
Treasurer and Hon. Secretaries:						
Secretarial assistance	26	5	0			
Commission to Collector	15	15	0			
				42	0	0
Printing and Stationery				64	12	1
Petty Cash Expenditure				9	2	7
Balances:						
At Bank	136	1	4			
Petty Cash	2	14	10			
				138	16	2
				£572	15	11

FREDERICK TAYLOR, *President.*
G. H. MAKINS, *Treasurer.*
ANTHONY A. BOWLBY, *Hon. Secretary.*

Examined with the vouchers and found correct,
LEONARD G. GUTHRIE,
E. PERCY PATON, } *Auditors.*

May 5th, 1904.

COMMUNICATIONS.

I.—*A case of Erosive Gastric Ulceration with Severe Hæmatemesis; Operation; Recovery.* By Sir Dyce Duckworth, M.D., LL.D., and H. T. Butlin, D.C.L., F.R.C.S. *Read October* 9, 1903.

E. W., æt. 29, a book-stitcher, was admitted to John Ward in St. Bartholomew's Hospital on November 21, 1902, suffering from repeated attacks of hæmatemesis. She was a fairly nourished woman, and had been complaining of pain occurring soon after taking food for about three weeks before admission. This pain lasted for an hour, and was not associated with vomiting. After her dinner, which consisted mainly of a mutton chop, on the 21st she vomited, and the rejected meal was mixed with blood. She came to the hospital, but refused to be warded. Later in the day she vomited four times, each time bringing up about a teacupful of blood. She returned to the hospital and was admitted. Eighteen months previously she had suffered from "indigestion," and had been treated as an out-patient for two months. There had then been pain after food, but no vomiting. She had had no other illnesses. The family history was unimportant.

She was manifestly blanched. The temperature on admission was 99·4°; her pulse 108, regular, of moderate volume, and rather low tension; the respirations were 30 per minute. The thorax was well formed and moved freely. The abdomen was not distended, and no viscera were felt. There was tenderness at the epigastrium on gentle pressure.

The catamenia were regular. The urine presented no abnormal characters. There had never been any pyrosis.

The treatment consisted of rectal feeding by nutrient enemata every four hours, the large bowel being previously washed out by a soap enema. Five minims of adrenalin chloride (1 in 1000) were given and repeated at intervals, and teaspoonfuls of water were given to sip. The bowels acted on November 22, a very dark motion being passed. There was no nausea or vomiting, and the epigastric tenderness subsided. A pint of normal saline solution was given each day by rectum after the 23rd, and two ounces of whey were given three times a day, increased to four ounces each time on the 24th. On the 27th the bowels acted three times. The second stool was large and very black. She took four ounces of whey every two hours, and four nutrient injections were given daily. On the 30th the pulse-rate increased to 116, and headache was complained of. There was no abdominal pain or sickness. The amount of whey was decreased to two ounces for each feed. Her temperature, which had fallen to normal, now rose again to 99·4°, and there was increasing pallor. Small quantities of beef essence were given on December 1, but these caused nausea and discomfort, and were therefore withheld. Some small dark motions were passed. On December 3 she vomited twelve ounces of blood mixed with watery fluid, bright red in colour. Two hours later she vomited ten ounces of similar fluid. Adrenalin chloride was again given.

It appeared certain that a continuous hæmorrhage was in progress, and Mr. Langton, who had been so good as to see the patient with me on the previous evening, now saw her again, together with Mr. Butlin, to whose ward the patient was presently transferred.

Continuation by Mr. Butlin.

On seeing the patient with Sir Dyce Duckworth and Mr. Langton, we came to the unanimous conclusion that the hæmorrhage was probably continuous, and would almost certainly prove fatal, unless active measures were taken to arrest it. We also felt that the patient, who was still in very fair condition to bear an operation, would not be so in the course of a few hours if the hæmorrhage continued, and that she further ran the risk of rapid decline and death if the bleeding should become suddenly more severe. It was therefore de-

cided to operate at once, in the hope that a bleeding ulcer or growth might be found and dealt with successfully.

Operation (in which I was assisted by Mr. Lockwood).—After preparation of the skin, and under a general anæsthetic, an incision three and a half inches long was made in the middle line, the stomach exposed and drawn up through the wound. No induration was felt of any part of its wall. It was therefore opened by an incision in its long axis, and its interior was examined. Nothing which could be called an ulcer was discovered, but in the greater curve, and near the pyloric end, the mucous membrane over several square inches was of a pale pink colour, apparently from congestion, and differed markedly from the rest of the mucous membrane, which presented a curious ivory-yellow surface. At various points on this pink area were slight excoriations, little fissures, and tiny points, and from several of these blood was actually oozing. They were not indurated, and, with the exception of those which were bleeding, were so trivial and so insignificant that they might have been overlooked, or, in any case, they might not and perhaps would not have been regarded as the source of such severe loss of blood. But fortunately I had only a few days previously read Mr. Mansell Moullin's excellent paper in the *Clinical Journal* (vol. xxi, p. 72, November, 1902), so that I not only felt sure they were the source of all the hæmorrhage when I saw them, but I was actually looking out for them. As I thrust each one of these unsound places up through the wound in the stomach, Mr. Lockwood passed a fine silk (00) thread round it so as to enclose and strangle it by means of a purse-string suture. Nine places were thus rapidly dealt with, and they appeared to be all those which had bled or were likely to bleed. The opening in the stomach was closed by a continuous silk suture (3) which embraced all three coats, and this was buried by several Czerny-Lembert sutures of (00) silk. The wound of the abdominal wall was closed by three layers of continuous silk sutures, the ends of which were left out at each end of the wound.

The operation lasted three quarters of an hour, and not more than about a drachm of blood was lost from the actual incisions, as every vessel was secured, as far as possible, before it was divided.

After the operation the patient, who was in very good condition, vomited an ounce and a half.

On December 5 her pulse was 108 to 120; her temperature

101°, but it quickly fell to 99.° In the middle of the morning she vomited three ounces of acid green fluid, which did not contain any trace of blood. She was fed entirely by the bowel, while saline solution (one pint) containing one drachm of Liquor Calcis Saccharatus was also administered. From this time her progress was uneventful. By January 9 she was taking boiled fish, and by the 14th minced meat. On February 4 she was sent, quite recovered and looking very well, to the convalescent home at Swanley.

The source of the bleeding in this case was supposed to be an ordinary acute ulcer. It was found to be due to what is now described as an erosive ulceration. The bleeding points appeared as small chaps or fissures in the mucous membrane, and each one of these had to be dealt with. Mr. Butlin remarked on the similarity of these lesions to those sometimes met with on the septum of the nose and, very rarely, on the tongue. Such lesions (sometimes called nævoid) may and often do bleed profusely, and demand in these situations the application of the galvano-cautery, but, as this styptic method may be required several times to close the vessels, it is inapplicable to the interior of the stomach. This erosive condition is believed by Dr. F. J. Smith * to be the starting-point of most if not of all gastric ulcers. Mr. Mansell Moullin † well describes the appearances presented by these lesions, and notes the occurrence of linear or stellate fissures with soft and swollen edges. The blood oozes from a raw granular surface, slightly depressed below the level of the rest, and the surface appears as if the upper layers of the mucosa had been scraped away.

These appearances are of particular interest because they are only recognisable during life, and they would almost certainly fail to be detected *post mortem*, as in most cases some degree of digestion of the membrane has taken place after death, and the more characteristic appearances of an acute ulcer are not yet assumed. This case, then, affords excellent confirmation of Dr. Smith's and Mr. Mansell Moullin's observations.

* *Clinical Journal*, Nov. 17, 1902, vol. xxi, p. 72.
† *Ibid.*

II.—*A case of Acute Hæmorrhagic Pancreatitis.* By Anthony Bowlby, C.M.G. *Read October* 9, 1903.

THE patient was a man, æt. 41, who had apparently enjoyed good health previously, but his past history could not be satisfactorily obtained.

He stated that on November 19, 1902, he was seized suddenly with abdominal pain and vomiting.

The next day the pain continued, and he suffered much from flatulence. The bowels did not act.

On November 21st he was admitted to St. Bartholomew's Hospital under the care of Mr. Howard Marsh. He then complained of severe abdominal pain and a feeling of distension. The bowels had not acted since the 19th, in spite of purgatives and enemata. His temperature was 97·6°; pulse 80; respirations short and rather jerky, 24 to the minute. The abdomen was slightly distended, and generally tender everywhere. Examination *per rectum* revealed nothing. He was sick several times in the afternoon, but merely vomited the contents of the stomach. An enema resulted in a copious action, and later on the bowels were again emptied. He had a restless night, and next morning, at about 5 P.M., became delirious and wandering. His temperature also rose to 100°. The urine was very scanty, only two ounces being passed in the first twelve hours he was in hospital.

During November 22, being the third day of his illness, he became more quiet mentally. The bowels acted, and the distension of the abdomen passed away. He still continued to be sick at intervals, but the vomit was merely the contents of the stomach.

The next two days were uneventful, but the man was not improving. He continued to pass very little urine, about sixteen ounces in twenty-four hours, and was still sick at intervals. The mental disturbance continued, and he had many delusions, with occasional attacks of violent delirium, but there was no evident pain or tenderness.

On November 25, the sixth day of his illness, violent retching set in with a return of severe abdominal pain, and the urine became still more scanty, only four ounces being secreted in twelve hours.

The next day, which was the seventh day of his illness,

he was seen by Dr. Gee and transferred to a medical ward, being very much better in every way. On the following night, however, all the symptoms returned with increased intensity, and the abdomen became rapidly distended. The patient was again quite delirious.

On the 27th the distension had further increased, sickness and retching were continuous, and there was no passage of flatus. The patient had become desperately ill, and Mr. Marsh and Dr. Gee decided that, as there might be some cause of obstruction which operation might relieve, the abdomen should be opened at once, and, as Mr. Marsh was prevented from staying at the hospital, this operation was done by myself.

I found some blood-stained fluid in the abdomen, and some general distension of all the intestine, together with recent general early peritonitis. There were also a good many old peritoneal adhesions, but at no place was there any strangulation. The great distension of the bowels made manipulation difficult, but no tumour could be felt. A coil of the ileum was opened in the left groin and sutured to the skin. The operation gave no material relief, and the patient gradually sank, and died the same evening.

A *post-mortem* examination showed a large extravasation of blood enveloping the pancreas and extending down as far as the iliac fossa. The pancreas itself was immensely swollen and full of extravasated blood and clot. There was a little fat necrosis in the transverse mesocolon, but the great omentum was not affected. The liver was fatty, but the other viscera were normal.

In this case, as in many others of pancreatitis, the diagnosis was not made, and the distension due to a secondary peritonitis suggested that after all the patient was suffering from some mechanical obstruction of the intestines.

There are several points deserving attention. In the first place, the delirium and the hallucinations constituted a very unusual condition, and also materially obscured the diagnosis, for they quite prevented any assistance being obtained from the patient himself, his answers to questions being altogether misleading. The very marked suppression of urine was a striking feature, and one not usually observed in this disease; whilst the quiet pulse and normal temperature in the early days of the attack did not seem compatible with acute pancreatitis. There was also a notable absence of any abdominal tumour or of special pain or tenderness in the pancreatic region, and although there were severe sickness and retching,

there was no definite obstruction until, on about the eighth day, peritonitis supervened.

The man was of about the age at which pancreatitis appears to be most common, and he was stoutly built. There was in him no history of previous gastric or intestinal catarrh, nor had he suffered from gall-stones as have some other patients. The only instance of previous abdominal trouble was to be found in the peritoneal adhesions encountered at the operation, and on the whole he was a sound man. Nothing in his kidneys explained the scanty and almost suppressed urine.

I am afraid that this case does not throw much additional light on a very obscure disease, but it is only by recording cases in which unusual symptoms are noted that fresh facts are obtained on which to base further investigation. It is also to be remembered that although intestinal obstruction is often simulated by acute pancreatitis, this simulation is most commonly met with and is most marked at the very onset of the illness. In the case under consideration the obstruction which called for operation evidently resulted from a secondary peritonitis, but at the onset there were the usual violent and sudden pain and vomiting, followed by collapse, which so often ushers in acute pancreatitis, and simulates strangulation of bowel. Although this mode of onset has been now frequently described, I think that even now it is hardly sufficiently recognised, and even if recognised it is at present in no way explained. Inflammation does not commence in this sudden and violent way in even its most acute forms, and although, as its name implies, "pancreatitis" is supposed to be an inflammatory lesion, I am much inclined to doubt whether it is really inflammatory in its origin. At one time, indeed, I was tempted to think it might be due to embolism of the main pancreatic artery with secondary effusion of blood, but I have not been able to find any evidence in support of this theory, and have therefore abandoned it. What the pathology of pancreatitis may be is a matter for the future, but in the meantime I think we are gradually acquiring more knowledge of its clinical features, and are consequently better able to recognise it when we meet with typical cases.

III.—*A case of Hæmorrhagic Pancreatitis.* By Fredk. Taylor, M.D. *Read October* 9, 1903.

JAMES B., æt. 68, a fishmonger, was admitted into Guy's Hospital on February 3, 1899; he was at first under Dr. Pitt's care and subsequently under my own.

He was in a public-house in Billingsgate, and ordered some rum. He filled up his glass from a bottle on the counter and drank the whole. This bottle was said afterwards to contain oxalic acid of unknown strength. He was immediately given salt and water and vomited freely; he was then brought up to the hospital, when 30 grains of sulphate of zinc was given, and after free vomiting half an ounce of chalk and water.

When he first arrived at the hospital he did not seem to be much affected by the poison, but after about twenty minutes his pulse became weak and rapid, 130, and he was very tremulous and rather blue. He was sent into the ward, and some brandy was subcutaneously injected. ℞ Liq. Calcis Saccharati ʒiv, Aquam ad ʒij, to be taken twice hourly.

He was fed on gruel and milk. He soon became warmer, his pulse improved, and by night he seemed to have recovered, except for some soreness in the epigastrium. The mouth and lips were a little excoriated, and there was some glossitis (believed to be chronic).

The cardiac sounds were very faint, but free from murmurs; the lungs were emphysematous with a few rhonchi; the urine was normal and free from albumen.

On February 4 he appeared to be quite well, and left at his own urgent request. He went by train to Notting Hill, and arrived home in a very feeble condition. He went to bed, and remained there during February 5 and the morning of the 6th, with a bad appetite, difficulty of breathing, and much cough. In the afternoon he returned to the hospital. On admission his face was pinched and somewhat cyanosed; the pulse was small, 110; he was breathing rapidly, 32, and was very cold and feeble.

The condition of the lungs appeared unaltered. The impulse of the heart could not be felt or seen; the heart-sounds were feeble and best heard in the fifth space in the

nipple-line. All soreness of the mouth and pain in the epigastrium had disappeared, and there was no pain on swallowing. The urine showed a trace of albumen, and had a specific gravity of 1010.

He was tremulous, but no other sign was obvious in the neuro-muscular apparatus.

He was ordered Tincture of Strophanthus, Liq. Strychninæ, Barium Chloride, and Tincture of Serpentary.

Râles and rhonchi became marked in both lungs; his appetite was bad, and he even refused food, and was very despondent about himself.

During the first week the temperature ranged between 99° and 101°, occasionally rising to 102°, the pulse from 104 to 120, and the respirations from 28 to 40.

On February 11 some râles were heard in the right axilla and below the right nipple. That evening he became more cyanosed, and was breathing very badly. He was bled to ten ounces, with some improvement in his colour, breathing, and pulse; and he passed a better night.

During the next three days he became steadily worse. The pulse was that of an unfilled artery, the respiration was laboured, and the râles persisted. He was very weak and very despondent about himself, but took nourishment well. The temperature had been somewhat lower, and on February 16 it was normal. But he continued to get feebler, with failing pulse, feebler respiration and vesicular murmur, a normal or subnormal temperature, and on February 23, without any further physical sign or local manifestation, he died. The epigastric region was frequently examined, but there was no tenderness over the stomach nor any other sign of serious abdominal lesion. On February 14 and 15 albumen was absent from the urine.

The *post-mortem* results were as follows:

There was recent pleurisy over both lungs in front and over the left lung behind. Both lungs were markedly emphysematous; they were also œdematous, and the bronchial tubes contained pus.

There was slight atheroma of the aorta, and slight thickening of the mitral valve. The other valves, the coronary arteries, and the cardiac muscle were healthy.

About ten ounces of recent blood-clot were found in the substance of the great omentum, shut off from the peritoneal cavity. In the posterior part of the mass was the pancreas. This organ was in a state of interstitial hæmorrhagic pan-

creatitis, being enlarged, hard, and infiltrated with blood. There was no peritonitis and no fat necrosis. The kidneys were slightly granular, with thin cortex, thickened arteries, and a few cysts. The spleen was the subject of old capsulitis.

Remarks.—I have ventured to record the above case as a contribution to the subject of diseases of the pancreas; but it may perhaps be admitted that the exact sequence of events is not entirely clear, and the bearing of the case may have to be left open until it can be compared with other similar cases. It may be considered under the following heads:

The nature of the lesion.—It is to be regretted that no histological examination has been recorded, so that it might be doubted even whether it was really a case of hæmorrhagic pancreatitis, or only one of hæmorrhage into the pancreas without inflammation.

The patient for some time before death was suffering from emphysema of the lungs and purulent bronchitis; that is, a thoracic condition which would lead to retardation of blood in the abdominal circulation, and to that extent would favour a hæmorrhage into the pancreas. And diseases of the heart and lungs are conditions predisposing to pancreatic hæmorrhage. Moreover, there was no fat necrosis, a condition which has so often been described in cases of pancreatitis, and is much more often absent where hæmorrhage occurs alone. But Dr. W. N. East, who made the *post-mortem* examination, came to the conclusion, from the altered size and texture of the gland, that it was really inflamed.

Duration of the illness.—This amounted to twenty days, and I think it must be regarded as one continuous illness. It is true that he insisted on leaving the hospital the day after his first admission, having apparently recovered from the immediate effects of the poison; but he even then had bronchitis. He arrived home in a very feeble condition, took to his bed at once, and returned to the hospital two days later.

On his re-admission the gastro-intestinal symptoms had disappeared and his chief troubles were on the side of the respiratory system. From this time till his death the same features were observed, with the addition of a gradually increasing collapse. This long duration of the case is very different from what has been recorded in so many cases, where a fatal result has ensued in three, four, or five days. Some cases, however, in which a laparotomy has been per-

formed have afterwards recovered, so that in this case it may be considered that the prolongation was due to a less severe lesion than in most other cases, but that the failure of the respiratory organs contributed to the fatal termination in a patient of rather advanced years.

The relation to the oxalic-acid poisoning.—This is another difficulty in the case. The onset of his illness appeared to be determined by the accidental mixture of a solution of oxalic acid with the rum he ordered at the bar of a public-house.

It seems incredible that a publican should be so careless of his goods as to leave a solution of oxalic acid within reach of his customers; but that some corrosive poisoning was ingested seems to be shown by the condition of his lips on admission. On the other hand, it could not have been much; the action of oxalic acid in quantity is very prompt, and it is expressly stated that on admission into the hospital he did not seem to be much affected by the poison, but that he became collapsed afterwards. It is of course conceivable that the ingestion of a rather mild dose of oxalic acid almost coincided with the natural and spontaneous onset of a hæmorrhagic or inflammatory lesion of the pancreas. A cursory glance at text-books on forensic medicine does not show me that the pancreas is known to be affected by oxalic-acid poisoning; and it is, I think, much more reasonable to suppose that the effects of the poison, being in very dilute solution, quickly passed off, and that the pancreatic lesion began to come into operation within twelve hours after it.

Latency of later symptoms.—This is not a greater difficulty than others discussed above. Pancreatic hæmorrhage at any rate has been found *post mortem* without corresponding symptoms, and if we remember that the final symptoms were those of a severe emphysema or purulent bronchitis, it can be understood that some local abdominal sensations might have been disregarded by him; and the examinations which were made in view of the poison ingested were quite negative. In the absence of such symptoms there was nothing to direct attention to the pancreas, and the failure to recognise a lesion of this organ before death is in part explained.

IV.—*Case of Myositis Fibrosa, with pathological examination.* By Frederick E. Batten, M.D. *Read November* 13, 1903.

THE following case is one which should have been shown at this Society during the last session. Unfortunately the patient was taken seriously ill before the meeting of the Society and died some few days later.

The case was clinically one of myositis fibrosa, and the pathological examination has confirmed that diagnosis. The number of such cases reported clinically is small, and those in which a pathological examination has been made is limited to two or three cases, and in these a portion of the muscle had been removed during life. I have been unable to find the exact counterpart of this case either clinically or pathologically. In the *Transactions* of this Society a description of no such case exists.

I propose therefore to give, *firstly*, a description of the clinical aspect of the case; *secondly*, a decription of the pathological conditions found; and *thirdly*, to discuss the morbid anatomy *and* pathology.

G. W., æt. 6, was the second of five children, all the others being healthy. The mother and father were healthy and were not blood relations. The mother had had no miscarriages.

The mother stated that the boy had been well till nine months old. She then noticed that the back was growing out and the legs were drawn up. The child was taken to the Children's Hospital, Great Ormond Street, when two years old, but the child was not admitted, and no note of its condition at that time is obtainable. The condition had slowly and steadily progressed, the child becoming more bent and the legs more flexed.

There had been no acute onset of the disease, and the child suffered no pain. The child was first seen by my colleague, Mr. Horace Collier, and his assistant, Mr. Howard, who kindly transferred the case to my care. The boy was poorly nourished and thin. He sat up in bed with the legs flexed, the back curved, and the head flexed on the chest with the face turned towards the left, owing to the contraction

of the right sterno-mastoid muscle (Pl. I, fig. 1). The arms were flexed and held close to the trunk.

The boy was fairly intelligent; he took notice of his surroundings, and could talk. He was clean in his habits. The right side of the face appeared larger than the left, and there was marked asymmetry.

All movements of the face and lips were well performed. The eyes moved well in all directions, and the pupils reacted to light, and the fundus was normal. The tongue was well protruded. The boy experienced no difficulty in mastication or in deglutition. The head was drawn down on the right side by the contraction of the right sterno-mastoid muscle, which was so shortened that it measured less than three inches. Owing to this contraction the bodies of the vertebræ protruded on the left side and formed a hard tumour. The left sterno-mastoid was not contracted.

The spine was fixed in a curved position and could not be straightened. There was no lateral curvature except that produced by the contraction of the right sterno-mastoid muscle. The abdominal muscles were extremely hard and contracted and shortened to such a degree that the total length between the epigastrium and pubes was three inches; the right abdominal rectus muscle appeared somewhat shorter than the left, and the edges of the muscle could be felt as a hard cord-like structure. The lateral muscle of the abdomen did not appear to be affected.

The arms could not be fully abducted from the thorax, owing to the shortening of the pectoral muscle. The elbow could not be fully extended, owing to the shortening of the biceps, but both the shoulder- and elbow-joints could be freely moved within a certain limited range. The arms could be moved at the elbow-joints, and no resistance occurred until the forearm came beyond an angle of 135° with the upper arm, and then it was suddenly checked from further extension. The abrupt check in passive movements of the limbs was present not only in the arms, but also in the legs. The movements of the wrist and fingers were free.

The legs were flexed on the abdomen and flexed at the knee, and could not be extended beyond a little more than a right angle. The feet and toes could be moved well. The great toes were shorter than the second and third and fourth toes. The muscles were all small and firm, but none except the right sterno-mastoid had the extreme hardness of the abdominal muscles. The boy moved as a whole; if the legs

were pulled upon the boy was brought into a sitting position. The joints were unaffected. No ossification of muscles could be detected. No disease could be detected in the visceral organs.

Sensation was normal.

The knee-jerks were obtained with some difficulty and were equal. The plantar reflexes gave flexor responses.

Electrical reaction.—All the muscles of the legs and arms contracted well to a weak faradic current; the left sterno-mastoid contracted well, but the right gave no contraction. The galvanic reactions were normal in the leg muscles, which were alone tested by this current. The boy was on one occasion placed under chloroform, but no relaxation of the contracted muscles took place.

No alteration occurred in the child's condition from this time, November, 1902, until death, which took place on April 26th, 1903.

At the autopsy, performed twenty-four hours after death, the body remained in the same flexed position which it had assumed during life. The abdominal muscles retained their hardness, and there was no relaxation. The arms and legs could be freely moved for a certain distance, but were then brought up sharp by the contracted muscle and tendon.

Muscles.—The recti abdominis muscles were very short, measuring less than three inches in length. The right, on section, was composed almost entirely of fibrous tissue of the hardness of cartilage, which, when cut, grated under the knife like tendon. The left rectus was very similar to the right, but the condition was not quite so marked. Some few muscle-bundles could be seen in both muscles. The tendinous intersection of the rectus abdominis muscles could be easily recognised, and section through them showed no muscle-fibres. Section through the muscle midway between the tendinous insertions showed that at least half the muscle was occupied by tendon and the remainder by muscle and fat. The right sterno-mastoid was extremely contracted, and was composed, so far as the naked eye could see, only of dense fibrous tissue. The left sterno-mastoid was a thin red muscle presenting a normal appearance. The pectoral muscles were thin and pale, but showed no obvious fibrous change to the naked eye. The biceps muscles of the arms were normal-looking muscles, but rather paler than natural. The psoas and iliacus muscles were pale, but not obviously abnormal, although extension of the legs very soon puts them

on the stretch, showing that they were contracted. Nothing obviously wrong could be seen in the biceps of the legs—the semitendinosus,—the extensor quadriceps, or in the muscles of the back. The biceps muscle of the leg floated when placed into Müller's fluid, owing presumably to the amount of fat which was present in that muscle.

Bones.—No alteration could be detected in the bones of the body except the skull, which was somewhat smaller on the right side than the left, and there was marked thinning of the bone on that side. The vertebral column could not be completely straightened even when the recti abdominis muscles were divided, although this procedure allowed of considerable extension. No abnormality could be detected in the joints nor in the bodies of the vertebræ.

Brain.—The surface of the brain, the membrane, and convolutions showed nothing abnormal. The sinuses were natural.

The spinal cord was well formed, and of good size. The peripheral nerves were natural in appearance.

Lungs.—There were a few fine adhesions over the left pleura, and almost complete collapse of the middle and lower lobe of the right lung. There were some ecchymoses over the left pleura.

Heart.—Few ecchymoses over the surface of the heart. The muscular substance of the heart wall appeared normal. The valves were natural.

Abdomen.—The liver was pale, but not fatty. The spleen and kidney were natural. The stomach and intestines showed nothing abnormal.

Microscopical examination.—The brain, spinal cord, and peripheral nerves were examined by the Marchi, Nissl, Weigert-Pal, and van Gieson methods. Nothing abnormal could be detected in any portion of the nervous system by any of these methods. The cells of the anterior horns were possibly rather more pigmented than is normal in cord of a child of this age, but they showed no diminution in size or number.

The pathological examination of the nervous system was most kindly carried out for me by my friend, Dr. Farquhar Buzzard.

Examination of the muscles and the nerves within the muscles.—The following muscles were examined microscopically:—The right and left sterno-mastoid, the right and left recti abdominis, the right and left biceps of the arms

the right quadriceps extensor, the left complexus, the left supinator longus, and the biceps of the left leg.

The muscles were examined by the Marchi, Weigert-Pal, and van Gieson methods, and were cut both in longitudinal and transverse section.

It will be unnecessary to describe the pathological changes in detail in each muscle, but the following four muscles, which may be taken as representing the changes occurring in all the muscles, will be fully described, viz. (1) left sterno-mastoid; (2) biceps of arm; (3) right rectus abdominis; (4) right sterno-mastoid.

The left sterno-mastoid.—Transverse section of this muscle stained by Marchi method did not show any excess of the interstitial fat above that present in the normal muscle. The muscle-fibres were fairly uniform in size, varying from about ·03 mm. to ·05 mm. (normal child ·03 to ·04 mm). The fibres were separated from one another by a small amount of interstitial tissue. The muscle-fibres themselves were for the most part round in shape, and many of them showed fine fatty degeneration.

Sections stained by the Weigert-Pal method for the demonstration of the nerves showed a fair number of nerve-bundles in transverse and longitudinal section which were well stained, and exhibited no abnormality.

Sections of the left sterno-mastoid stained by van Gieson method showed an increase of the interstitial tissue between the muscle-fibre, with numerous nuclei. The muscle-fibres were normal in appearance, and the normal transverse striation was present. The muscle-spindles were normal, and the intrafusal muscle-fibres were of natural size. The nerves to the spindles were well stained, and appeared perfectly normal.

The left biceps muscle of the arm.—The biceps muscle showed more change than the left sterno-mastoid; there was considerably more of interstitial tissue between the individual muscle-fibres, and the amount of interstitial fat was also considerable. The muscle-fibres which remained were large and well formed, and well striated. The muscle-fibres measured from ·05 mm. to 1 mm. in diameter (normal child ·03 to 0·4 mm.). The muscle-spindles were normal. The transverse striation of the muscle-fibre was normal, and no longitudinal striation was present (Pl. II, fig. 2).

Section stained by the Marchi method showed some fine fatty change within a certain number of the muscle-fibres.

Right rectus abdominis.—In section through the belly of the muscle it was seen that fully one half of the muscle was replaced by a dense mass of fibrous tissue, which resembled tendon in appearance. The dense tendinous mass was gathered up into two large rounded bundles (see Pl. II, fig. 1). On microscopical examination the tendinous portion was seen to be composed of dense fibrous tissue, with scattered, elongated nuclei. This tendinous portion was arranged in oval or rounded bundles, and not in flat bands such as occur in the normal muscles.

In close proximity to the tendinous masses are seen the muscle-fibres, surrounded and separated from one another by a considerable quantity of interstitial tissue. At no point could a transition between fibrous tissue and tendon be seen. The muscular portion of this muscle closely resembled that seen in the biceps muscle, although the amount of interstitial fat was considerably less than in the former muscle (Pl. II, fig. 2).

The right sterno-mastoid muscle.—The whole of this muscle, from origin to insertion, was replaced by dense tendinous tissue. In sections made through the belly of the muscle a small band of muscular tissue could be seen lying on the outer side of the tendinous tissue. In sections made near the origin and insertion of the muscles no muscular tissue could be found. The muscle-fibres which remain were atrophied, measuring ·01 to ·03 mm. in diameter, and were separated from one another by connective tissue and interstitial fat. At no point was there any tendency for the muscle to undergo ossification.

With regard to the other muscles examined, the left rectus abdominis presented a condition very similar to that described in the right rectus. The right biceps of arm closely resembled the left. The quadriceps extensor showed considerable fibrosis and interstitial fat, but no increase, either actual or relative, of the tendinous structure. The biceps of the leg contained a large amount of interstitial fat. The left supinator longus and the complexus muscle were not much affected.

In the description of the four muscles here given it will be noted that whereas in the left sterno-mastoid but little change was to be found, in the right there was profound alteration, so that the whole muscle, from its origin to insertion, was replaced by tendon; between these two extremes come all the other muscles examined, and two have been chosen, viz. the biceps of the arm and the abdominal rectus, to illustrate

the intermediate condition. The biceps exhibited a great increase of interstitial tissue between the muscle-fibres and a large amount of interstitial fat, but neither at the belly of the muscle nor at the tendinous end could it be asserted that there was any undue increase of the tendinous material. There was an interstitial fibrosis, but not an increased tendinous formation.

With regard to the rectus abdominis, however, fully one half of its substance was occupied by dense tendinous material, and the remaining half by muscle, with a considerable amount of interstitial fibrous tissue and fat. The only muscles in the body which exhibited an apparent increase of tendinous material were the right sterno-mastoid and both recti abdominis; nearly all the other muscles examined showed an increased interstitial fibrosis, but at no point could it be shown that this fibrous tissue became converted into tendinous tissue.

Pathology.—The cause of the disease is obscure; there was no evidence pointing to injury at birth or subsequently; there was no history of acute illness, consanguinity of parents, syphilis, or rheumatism. The gradual onset, the slow progress of the disease, the fixed position which the trunk and the limbs gradually assumed form a clinical picture which bears a striking resemblance to myositis ossificans.

One further point in favour of the condition being allied to myositis ossificans was the fact that the great toes were shorter than the second, third, and fourth toes. The complete absence of any bony formation in the muscles does not allow of the case being regarded as one of myositis ossificans.

In comparing the muscles in this condition with that found in pseudo-hypertrophic paralysis, one is struck by the fact that there is a close pathological similarity between the two conditions, with this notable exception, viz. that in the muscles of pseudo-hypertrophic paralysis there is no muscle in which the tendinous tissue predominates as it does in some muscles of the present case.

The condition of muscle differs considerably from that found in infantile paralysis, for in that disease the fibrosis is much more complete in certain portions of the muscle, while in other portions the muscle-fibres are perfectly normal, and do not show any interstitial fibrosis.

If the sterno-mastoid muscle be compared with the condition of muscle found in congenital contraction of the sterno-mastoid, it will be seen that whereas in the present case the

whole muscle was converted into tendon, in congenital contraction of the sterno-mastoid there was a general fibrosis of the muscle in which isolated muscle-fibres could be seen.

Two chief points seem to present themselves for discussion: firstly, is there an actual increased growth of the tendinous structure in the muscles involved? secondly, is the tendinous structure only relatively increased in relation to the muscle, owing to the interstitial fibrosis and subsequent contraction and destruction of the muscle-fibres?

With regard to the first point there does not seem to be any evidence that tendon tissue ever proliferates or replaces muscular tissue. Mr. Shattock has, however, pointed out to me that some muscles in certain animals are occasionally replaced by tendon. There would seem to be, however, no reason why, from some constitutional abnormality of the individual, the tendency to tendon formation should not occur, just as the tendency to ossification occurs in myositis ossificans. In the present case, however, it is difficult to see why the tendon formation should occur only in three muscles, while the general fibrosis affects nearly all the muscles of the body.

The more reasonable explanation would certainly seem to be that which is suggested under the second heading, viz. that the tendinous structure in the muscle is only relatively increased to the size of the muscle owing to the extreme shortening which the right sterno-mastoid and the abdominal recti have undergone.

Myositis fibrosa as a primary disease.—The clinical picture of "myositis fibrosa" drawn by Lorenz is shortly as follows:

Myositis fibrosa starts as a subacute inflammation of muscles and produces a chronic myositis. It may affect one muscle or group of muscles, and the development of the disease lasts many months. The lower extremities are most frequently affected, but in the case described by Janicke the disease started in the sterno-mastoid muscle, spread to neck, back, and intercostal muscles, and later to the abdominal muscles.

The general condition of the patient is but little disturbed, and there is no fever.

Some patients have sharp pain in the affected muscles, and this compels them to keep in bed. After a short time rigidity of the affected limbs occurs, which become typically contracted, the flexor muscles being especially affected.

In some cases the affected muscles become swollen, and develop slowly into a hard solid tumour which involves the

skin and surrounding tissue. The skin is often thickened and pigmented brown. In other cases the muscle feels like a hard tendinous band.

The electrical irritability is markedly affected, and in some cases there is complete loss of faradic irritability.

The pathology of the condition is given as follows, and is derived from cases in which a muscle has been excised.

Macroscopically the muscle is found to consist of a tissue, which, when cut, grates the knife, and in the most marked stage of the disease exhibits white, hard surface on section.

In the less affected portion the tissue appears spotty, for in the white substance are remains of muscular tissue in the shape of reddish-yellow points.

On microscopical examination the specimens show an increase of the interstitial tissue between the muscle-fibres.

The muscle-fibres have in part undergone granular degeneration, in part simple atrophy; the transverse striation has disappeared, while the longitudinal striation is marked.

The most severely affected portion of the muscle was almost entirely composed of tendinous tissue, in which a few atrophied muscle-fibres were to be recognised (Linden and Hackenbruch).

The published cases of myositis fibrosa bear but a very superficial likeness to the clinical features of the present case, but as both the following resemble the present case in some points it may be well to quote them.

Janicke's case of myositis interstitialis.—K. B., three years old, first had swelling of left sterno-mastoid. Fourteen days later swelling appeared in left trapezius, the latissimus dorsi, intercostals, and erector spinæ, and later still in both pectoral muscles and the right sterno-mastoid.

Three months later the muscles of the upper arm were affected, but by this time the other muscles had improved. The right trapezius was then affected for a second time.

Cultures were made from these muscles but with negative results.

Portion of the muscles excised showed swelling of fibres, atrophy and granular degeneration of others,—loss of transverse striation and marked longitudinal striation, *i. e.* a degenerative process of the muscle parenchyma, but the interstitial tissue was also affected. The muscle bundles were separated from one another by broad bands of solid connective tissue, resembling a hard nucleated fibroma, but

a true cell infiltration could not be seen. The symptoms disappeared under treatment.

The second case is published by Lindner, and is of especial interest owing to its pathological examination. In a paper, "Ueber Myositis," he describes a case of a woman aged fifty-three who had painful swelling in the left lower extremity. For ten years previous she had had some weakness in the extremity and pain, which was worse at night. For two years the patient had been bedridden. When first seen the whole of the left leg from the knee to the ankle was thickened, very hard, and gave the impression that the bones of the lower leg were surrounded by tumour. The skin was adhered to the subcutaneous tissue, infiltrated, and the veins were dilated. The limb was not tender on pressure, but the patient complained of great pain. Incisions were made into the leg, and portions of the calf muscle removed. The tissue removed was very hard, grated under the knife, and in the part which had undergone most change, viz. the peronei muscle, was almost white with only pale red spots and lines. In the less affected areas the muscles had simply a spotty appearance.

The microscopical examination showed in the portion of the muscle excised almost only tendinous connective tissue, in which could be recognised only a few atrophied muscle-fibres, while in the gastrocnemius muscle there were muscle bundles separated by broad bands of connective tissue, which also passed between the individual muscle fibres and separated them. The muscle fibres were atrophied and for the most part had lost their structure, but the longitudinal striation was marked.

The number of nuclei between the fibres seemed to be increased, but this was probably accounted for by the contraction of the tissue.

The patient did not improve. The pain was explained by the view that the nerves were involved in the fibrous tissue produced.

In one case published by Gies, and in one by Kreiss, the patients recovered under massage and electricity.

The presence of this tendinous material in the muscle closely resembles the pathological condition found in the present case.

Summary.—A boy, the second of five children, was healthy till nine months old, when the mother noticed that the back became curved and the legs drawn up. The condition steadily progressed, so that at six years old he was

rigidly fixed in a flexed position, the right sterno-mastoid being greatly contracted. No evidence of disease of the nervous system could be detected. The boy died when six years old.

Post-mortem examination showed extensive contraction of muscles, especially the right sterno-mastoid and the recti abdominis, and these muscles were of cartilaginous hardness.

Microscopical examination revealed a general interstitial fibrosis of all muscles examined. The right sterno-mastoid was almost wholly, and the right and left recti abdominis were to half their bulk, composed of tendon. The case is regarded as one of primary fibrous myositis, and closely related to myositis ossificans.

The increase of tendon in the muscle is regarded as relative only, and due to the extensive contraction which has taken place in the muscle.

Bibliography.

GIES.—"Ueber Myositis chronica," *Deutsche Zeitschrift für Chirurgie*, 1878, 11, S. 161.

HACKENBRUCH.—"Ueber interstitielle Myositis und deren Folgezustände die sogenannte rheumatische Muskelschwiele," *Beiträge zur klinischen Chirurgie*, 1893, 10, S. 73.

JANICKE.—"Myositis Interstitialis," *Deutsche Med. Wochensch.*, 1895, S. 117.

KREISS.—"Ein Fall vom primärer schwieliger Myositis der Wadenmusculatur (rheumatisch Muskelschwiele Froriep's)," *Berliner klinische Wochenschrift*, 1886, 23, S. 877.

LINDNER.—*Berl. Klin. Woch.*, 1891, S. 1173.

LORENZ.—"Die Muskelerkränkungen," *Specielle Pathologie und Therapie*, Nothnagel, p. 240 et seq.

PLATE I.

Illustrating Dr. Frederick E. Batten's Case of Myositis Fibrosa.

Photograph of a boy with myositis fibrosa.—The photograph shows the position in which the boy habitually sat.

The back was curved and could not straighten; the arms and the legs were flexed and could not be fully extended. The head was drawn down to the right side owing to the contraction of the right sterno-mastoid muscle.

FIG. 1.

UofM

Bale and Danielsson, Ltd.

Mail

PLATE II.

Illustrating Dr. Frederick E. Batten's Case of Myositis Fibrosa.

FIG. 1.—A drawing of a microscopical specimen of a transverse section of the right rectus abdominis muscle. The drawing is a reproduction in colour of a specimen stained by van Giesson's method, and shows a large amount of tendinous tissue (*a*) occupying the substance of the muscle. This tendinous material extends the whole length of the muscle from origin to insertion.

In the field are seen normal muscle-fibres (*b*), somewhat separated from one another by the increase of connective tissue (*c*). A considerable increase in the interstitial fat (*d*) is also to be noted.

Below and to the left of the above reproduction is a smaller drawing (*e*) representing the actual size of the rectus abdominis in transverse section. The portion surrounded with a dark line indicates the portion of the muscle which was occupied by tendon.

FIG. 2.—A drawing of a microscopical specimen of a transverse section of the left biceps of the arm stained by van Giesson's method.

The specimen shows irregular-sized muscle-fibres (*a*) surrounded by a considerable amount of connective tissue (*b*).

In the section of the muscle there is also a very considerable amount of fat (*c*).

No increase of the tendinous material can be found in the specimen. The pathological condition in this muscle was simply an interstitial fibrosis.

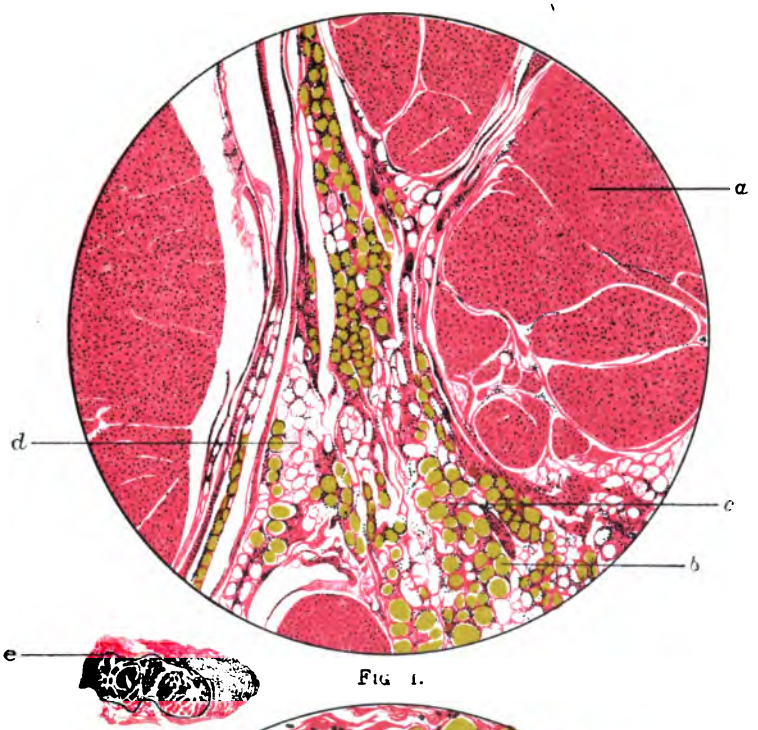

FIG. 1.

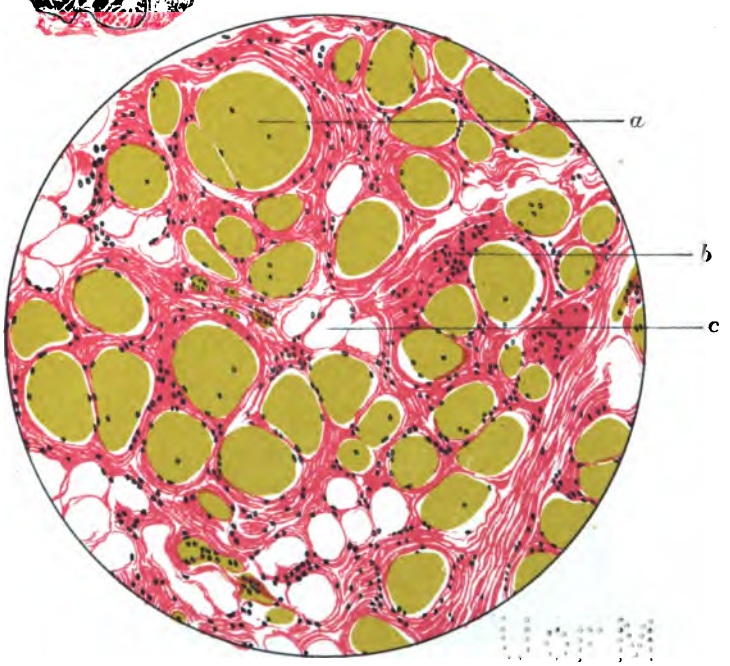

FIG. 2.

Del. and Chromo-Lith. by Bale & Danielsson, Ltd.

Mau

V. *Case of Coma with Measles in an Adult, followed by recovery.* By G. Newton Pitt, M.D. *Read November* 13, 1903.

M. L., æt. 19, medical student. He was in the enjoyment of good health, but did not feel very well on March 10, 1899. On the 11th he felt very chilly when watching a football match in a cold east wind. On the 12th, thinking he had taken a chill, he took a hot bath, and noticed that he was very flushed and had a rash on his face. He went out for a walk. Next day his temperature was 102°, and he was seen by his medical man, Mr. Frederick Burton, of Blackheath, who found a well-marked eruption of measles fully out. He had some soreness in his throat. His temperature ran up to nearly 105° F. He had a shivering fit on the afternoon of the 15th. He became very violent, shouting and struggling, and there was some difficulty in feeding him. On the 16th his water had to be drawn off with a catheter. On the morning of the 17th he became collapsed and comatose, looking very anæmic, and his condition was alarming. I saw him in consultation that evening. He was quite comatose, with widely dilated pupils, but his conjunctiva was not absolutely insensitive. He had had incontinence of urine and fæces during the day. The optic discs were normal, the tongue covered with a thick fur, but not very dry. The conjunctivæ were hyperæmic. The rash was abundant over the face, well marked over the body, but less so over the legs. His pulse was 110, temperature 103·4°. The chest was practically free from râles. He had been shouting out all day, was incessantly restless, tossing himself about frequently and holding his limbs rigid. There does not appear to have been any definite convulsion, and no evidence of any pain in his ears. He does not respond to any questions. He has only been able to take about half a pint of milk and a little brandy daily for the last three days.

March 18.—Temperature during the day has fallen, and in the evening was subnormal. He has slept a good deal, although very restless, and has been able to get a little more food down. He still passes his evacuations unconsciously. He puts out his tongue, although he won't answer, and does not seem to recognise anybody. His tongue is dry; his pulse

has dropped to 68, and is very small and irregular, but he has improved considerably.

On the 19th his temperature ran up again to 102·4°; in the early morning he became extremely cold and collapsed, but with stimulation that passed off, and he recovered more consciousness. Still great difficulty in feeding him, and the use of the catheter is necessary. The rash is fading, the tongue is less dry. He gradually became more conscious, and made a good recovery.

He says he has no recollection of anything between the evening of the 13th and the 21st, although for the first two or three days he answered questions, and was apparently quite conscious. During convalescence he had great insomnia, and frequently had persistent and uncomfortable sensations about his face and lips. For many months his memory was very defective. There was a loss especially of the names of things and of people, for he did not know the names of some of his neighbours when he recovered. He found that after reading a book he had no recollection of its contents a few hours later, and reading brought on a frontal headache. He went for a voyage to Australia, and came back absolutely well.

The interesting feature of this case was that, apart from the coma and the incontinence, the symptoms were not indicative of grave toxæmia. When it was clear that there was no evidence of any ear trouble it was possible to give a hopeful prognosis in spite of the coma.

The pulse was 110, and with the onset of the coma it fell to 68, and did not again become rapid. At times the pulse was feeble, but during most of the time it was of good volume. The tongue was dry for only about a day.

An examination of the temperature chart will show that neither the temperature nor the pulse indicated great gravity in the case.

Coma in measles is very rare, and but little can be learned either by inquiries from friends or from a search through the literature.

The causes of coma in measles would appear to be:

1. Toxæmia.
2. Meningitis due to either ear disease or tuberculosis.
3. Cerebral thrombosis often leading to hemiplegia.
4. Acute anterior poliomyelitis (in which coma and delirium sometimes appear).
5. Disseminated encephalitis.
6. Disseminated myelitis.

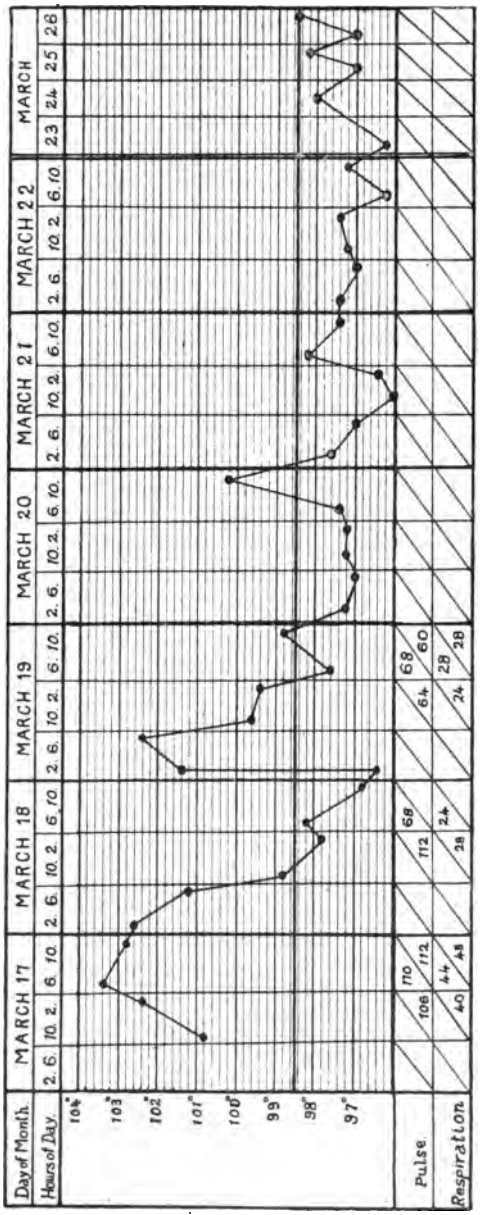
Day of Month.
Hours of Day.
MARCH 17
MARCH 18
MARCH 19
MARCH 20
MARCH 21
MARCH 22
MARCH
2. 6. 10. 2. 6. 10.
104°
103°
102°
101°
100°
99°
98°
97°
Pulse
Respiration
106 110 112
40 44 48
112 68
28 24
64 68 60
24 28 28
23 24 25 26

1. *Toxæmia.*—Coma may be present with extreme bronchopneumonia in a small child, and in the last stages of very toxic cases; these latter are now much more infrequent than formerly as patients are no longer shut up in close unventilated rooms and allowed no fresh air. As Corlett says, the nerve-centres may be profoundly impressed by the specific toxin, and repeated convulsions are not infrequent in children, while in adults delirium, either low or boisterous and violent, is sometimes observed. This is followed by great prostration, and the patient not infrequently passes into a comatose state, which terminates in death; this is most likely to occur on the third or fourth day of the eruption.

Both Drs. Goodall and Caiger tell me they have not met with cases of coma except as the terminal scene of such toxic cases.

Dr. D. Drummond, of Newcastle, tells me the following is the only case he has met with:

Young lady, æt. 21, developed measles December 30, 1899. Delirium set in on the third day. Her temperature was very high, and on the fourth day Dr. Drummond saw her in consultation, when she was becoming drowsy and comatose, and the coma deepened and became pronounced about the sixth day, and she died on the eighth. Four days after her death her sister developed measles which ran the ordinary course.

2. *Meningitis.*—I should like to raise the question whether there is any *post-mortem* evidence that meningitis is ever met with in measles or in mumps, independently of either otitis or tubercle? The possibility of such lesion is alluded to and copied from book to book; is there any justification for this?

Meigs and Pepper refer to the following case which had come under their notice, in which coma developed:

A girl, just over 5 years old, of a tuberculous family, developed measles, and the rash came out well. No abdominal symptoms developed during the first two days; but on the third day the child vomited, and at night was very restless. Next day she was very drowsy, hardly answering any questions, and protruding the tongue very slowly. Pulse and respiration were normal. On the fifth day she was comatose, and there were irregular convulsive movements. In the evening the right arm was rigidly fixed at the elbow and the left stiffly extended. The child died that night.

The symptoms are very suggestive of a tuberculous meningitis.

3. *Hemiplegia due to cerebral softening.*—Out of 200 cases

of hemiplegia in children there were eleven cases associated with measles. In some of these the lesion has been probably a thrombosis.

The remaining groups are of more interest to us in connection with the present case. The evidence is, however, rather clinical than pathological; but in Sir Thomas Barlow's case acute myelitis was found at the inspection.

5. *Local encephalitis.*—This may be due to a local infection or to a thrombotic necrosis, probably secondary to the measles. In this category I should include those in which there was (1) marked defect of speech, probably true aphasia; (2) the cases of prolonged or permanent mental failure; the cases (3) of deafness; (4) of laryngeal paralysis; and the series of cases (5) of ocular paralysis, of which I have been able to collect several, and they are probably not so very rare as would at present appear.

Besides the present case I have met with a woman, who, at the age of eleven, was in a prolonged stupor with measles; for many months after she was aphasic, and instead of being an exceptionally bright child she was looked upon as half-witted, and was unable to learn at school. Her speech ultimately became normal, but she is rather slow, and mentally she is inferior to her sisters.

(*a*) Dr. Goodhart saw the following case with Mr. Kingsford, of Brondesbury, to whom I am indebted for the following notes:

"May J., æt. 5 years 9 months, developed measles on February 5, 1898. The disease ran an ordinary course for the first few days, and seemed to be of a mild type. On February 10 the child seemed fairly well, and had a prolonged romp with her father in the evening. The next morning (February 11) the temperature had gone up, and the child was excitable and delirious. Before bed-time she was quite comatose, but was able to swallow what was given her. The coma persisted till the 19th, that is for some nine days, and then she gradually recovered. For the first twelve hours or so she persistently called "Emily," her nurse, and went on calling for her whether she were present at the bedside or not. Before the coma set in, "Emily" was the last word she said. From February 20 onward she made an uninterrupted recovery, and the only apparent residual weakness from the disease is some slight want of co-ordination in the fingers of her right hand. The child has enjoyed much better health since the attack than before. I have no

doubt that she suffered from meningitis, which happily did not go beyond a certain "depth," if I may use such a term (? encephalitis). The treatment was practically masterly inactivity and most careful nursing. Dr. Goodhart saw the patient on February 11 and 13, and Dr. Cheadle saw her every day from the 14th to the 19th.

Mr. Kingsford also writes to tell me that in 1897 he saw a girl æt. 7 with measles who was comatose for several days, and a boy æt. 13 who was similarly affected, and that they both recovered, but have remained permanently deaf.

(*b*) Dr. Dawson Williams' well-known case is that of a girl æt. 4 who became comatose on the third day after the eruption of the measles rash, and remained so for ten days. On recovering consciousness she could not speak and had lost the use of her limbs. There was incontinence of urine and fæces with considerable anæsthesia. Two years later she was able to walk, but all her limbs were spastic, and her movements tremulous and unsteady, her speech slow, and at the age of ten she could only just read and write.

(*c*) He also refers to a case of Dr. Colcott Fox's of a girl æt. 4 who had inco-ordination, with nystagmus, slow, laboured speech, and a vacant expression after an attack of measles.

(*d*) Dr. Schepers reports the case of a girl æt. 8 who was comatose on the fourth day of a mild attack of measles. When she recovered from the coma she was unable to speak, was paretic, with great impairment of memory and marked ataxia.

(*e*) Professor Raymond reports the case of a child of eight who, during the course of an ordinary attack of measles, was found one morning to have weakness of the right hand, and on the fifteenth day there was ataxia with defective movement of both eyes upwards and laterally, associated with a right hemiplegia. This was considered to be due to an infective arteritis involving the posterior part of the nuclei of the third nerves and the left pyramidal tract.

(*f*) Dr. Lermoyez showed a case of permanent laryngeal paralysis following measles at the age of three in 1898, before the Société Médicale des Hôpitaux de Paris.

(*g*) Finxelstein reported two cases of psychosis during measles, but whether such indicated any local cerebral lesion is uncertain, more probably only a toxic condition.

A boy, æt. 13, who on the twenty-first day developed a noisy delirium, with loss of consciousness and attacks of

terror, terrifying visual hallucinations of a black man, a tendency to fly, was noisy, and had insomnia. He improved after a week, and was well in a month.

A girl of 14 developed, in the prodromal period of measles, terror, abuse, excitement, and violence. She refused to reply to questions, and would only utter the one word "unjust." Two days later there was mental depression with a rapid pulse and respiration; four days afterwards the rash was fully out. The depression increased, and the patient died from a pulmonary complication.

(*h*) Dreisch has recorded three cases of ocular paralysis affecting the third nerve in children aged respectively nine, eight, and fourteen, which developed some days after convalescence during an epidemic of measles at Ansbach.

(*i*) Fage reports, in a case of moderate measles in a child of 3, that optic neuritis developed twelve days after the onset of measles, without any meningitis, otitis, or pulmonary complication, and passed on to blindness.

(*j*) Simonin reports the case of a man of 21 who, on the third day of measles, developed paralysis of the sixth and of the external muscles of the third nerve on the left side, which cleared up in twenty days.

The similarity of the symptoms presented by my patient to those recorded in these cases of disseminated mischief is most striking, and makes it clear that it belongs to the same category. It is probable that whether the mischief is in the brain or in the cord, whether it is slight or severe, whether the symptoms are those of acute ascending paralysis, myelitis, encephalitis, or infantile paralysis, the pathology of all is alike, viz. a localised infective lesion in the nervous system. The attack in several cases is stated to have been otherwise a slight one; the coma has developed about the third or fourth day, with incontinence of urine and fæces; the subsequent symptoms have depended upon the locality of the lesion, but generally in the cerebral cases, speech has been affected, headache has been severe, and memory for a long time afterwards defective. In my patient the pulse rate was definitely lowered with the onset of the symptoms, and fortunately the recovery has ultimately been perfect.

I should conclude, therefore, that the lesion in my case is a slight encephalitis, which affected the left temporo-sphenoidal area at any rate.

Dr. Dawson Williams points out that, although some of the cases present many of the symptoms of disseminate

sclerosis, they differ in the important particular that the symptoms tend to improve and not to progress.

6. *Myelitis.*—Sir Thomas Barlow's case is of great importance on account of the full pathological account. Briefly, the case is that of a man æt. 23, who, on the third day of measles, had retention of urine; on the fourth he was drowsy; next day he was clear mentally, but paraplegia had developed, and he died with respiratory paralysis.

Post mortem there was a disseminated myelitis extending over the greater part of the cord, with extensive vascular disturbance.

In the same paper is a reference to three cases of paralysis published by Lucas, Liégard, and Bergeron.

Dr. Monro reports a case of peripheral neuritis after measles which recurred with an attack of influenza in the autumn.

A woman, æt. 31, was weak after a slight attack of measles in the spring. She had some pains, which were severe for a couple of months, in her hands; there was diminished power, so that there was difficulty in buttoning her clothes. The tingling pain was worse at night. The tactile sensation was impaired, and the knee-jerks were normal. She was quite well by August, but after an attack of influenza in September the symptoms returned more severely, and lasted till December.

Cioffi attempts to show that most of the pulmonary and grave cardiac phenomena which occur in connection with measles are due to changes set up in the vagus by the poison.

Acute ascending paralysis.—A boy, æt. 12, always delicate and subject to catarrh, developed measles on February 6, 1903. He was very well on the 8th, but on the 9th his temperature ran up to 105°, and fell the next day, but he remained very drowsy. Retention of urine, and on the 11th a catheter was tied in. When I saw him in the evening, in consultation with Mr. J. B. Howell, the abdomen was distended, and moved but slightly; the respiration was shallow and rapid, and he had been unconscious since 3 P.M. The temperature was 103°; at 7 P.M. he was much more feeble, and there were râles in his chest. At 9 P.M. there was universal paresis, but not absolute paralysis. It was impossible to rouse him, and when food was put into his mouth it remained there for some time. There was no squint. The pulse was 140. There were loud râles all over the chest, and the note at the apex of the left lung was impaired, and the breathing coarser than else-

where. He was unable to cough, and the mucus, therefore, accumulated. There were no knee-jerks and no superficial reflexes. The pupils were widely dilated, and the discs normal. The condition was one of acute ascending paralysis. There was no evidence of diphtheria. He died early the next morning, but no inspection could be obtained.

Bibliography.

Dawson Williams.—"A Case of 'False' Disseminated Sclerosis due to Measles (with references to literature)," *Med.-Chir. Trans.*, vol. lxxvii, p. 57.

Barthez et Sanne.—*Traité clinique et pratique des maladies des Enfants*, vol. iii, p. 38, Paris, 1891.

Schepers.—*Ibid.*

Sir Thomas Barlow.—"On a Case of Early Disseminated Myelitis occurring in the Exanthem Stage of Measles, with Report on the Spinal Cord," by Dr. F. G. Penrose, *Med.-Chir. Trans.*, vol. lxx, p. 77.

Corlett.—*Acute Infectious Exanthemata*, 1902, p. 292.

Raymond.—"Ophthalmoplégie external bilaterale et hemiplegie droité consecutive à la rougeole," *Nouvelle Iconographié de la Salpetriere*, Septembre, 1895.

Lermoyez.—"Paralysie récurrentiélle incurablé bénigne consecutive à la rougeole," Société Médicale des Hôpitaux de Paris, February 25, 1898.

Prat.—"Hémorrhagie sous-méningée dans la rougeole," *Bullétins*, p. 809, *Société Anatomique de Paris*, November 12, 1897.

Finxelstein, L. O.—"Deux cas de Psychose au cours de la rougeole chez l'enfant," Société de Psychiatrie de Petersbourg, December 20, 1897.

Dreisch.—"Ueber einige Storungen in Oculomotoriusgebeit nach Masern," *Munchener Med. Wochenschrift*, 1898, p. 627.

Monro, T. R.—"Peripheral Neuritis after Measles," *Lancet*, 1894, vol. i, p. 929.

Alessin, S. T.—"Sur un cas de rugeole et d'Hemiplègie totale," *Revué Neurologique*, vol. x, 1902, p. 1112.

Fage.—"La Neurite consecutive à la rougeole," *Congrés d'Ophtalmologie*, Paris, 1902.

Simonin.—"Ophtalmoplegie externé partièlle dissociée et transitoire d'origine périphérique au début d'une rou-

geole," *Bullétins de la Société Médicale des Hôpitaux de Paris*, 1901, p. 712.

Gowers, Sir W.—*Diseases of the Nervous System*, vol. ii, p. 898.

Ross and Bury.—*On Peripheral Neuritis*, p. 248.

Lop, M.—"Des paralysies morbilleuses," *Gazette des Hôpitaux*, Septembre, 1893, pp. 995 and 1915.

Cioffi, E.—"Le Nerve Vague dans ses rapports avec les formes malignes, et les complications de la rougeole," *Revue Neurologique*, 1900, p. 917.

Lucas, J.—*London Medical Journal*, 1790, p. 325.

Liégard.—*Gazette des Hôpitaux*, 1859, p. 562.

Bergeron.—*Ibid.*, 1868, p. 5.

Whipham, T., and Myers, A. T.—"On some Chronic Nervous Sequelæ of Smallpox, especially affecting the Speech," *Clin. Trans.*, 1886, vol. xix, p. 164.

(This paper with references to nineteen cases in all deals with the occurrence of encephalitis in smallpox.)

APPENDIX.

Case of severe Cerebral Defect following Measles.

G. H—, æt. 19. At the age of two and a half he had fits on and off occasionally for about five months. When four and a half years old he had a very severe attack of measles, with delirium while the eruption was out, but no convulsions. After this he was found to have general paresis of both arms and legs, but he had some power in his back. His speech was seriously affected, and he became reduced to the condition of a child of two years; he also developed an internal strabismus. For nearly two years he did not improve. He was able to understand what was said to him, and he began to talk before he recovered the power of walking. When he was six he began to walk a little with support. He developed very slowly, and was extremely nervous. At the age of seven he could feed himself; he was unable to hold a pencil or to write, and it was very difficult to educate him. At the present time he is tall, and extremely thin, with very small muscles. The development of the muscles of his arms and legs does not exceed that of a boy of ten. Still, no paralysis of any muscles can be made out, nor any special wasting,

except perhaps the supinator longus on both sides. He breathes through his mouth; his chest is very small owing to his defective respiration. He has a very high palate; his head is very small; his hands are large and long, and his

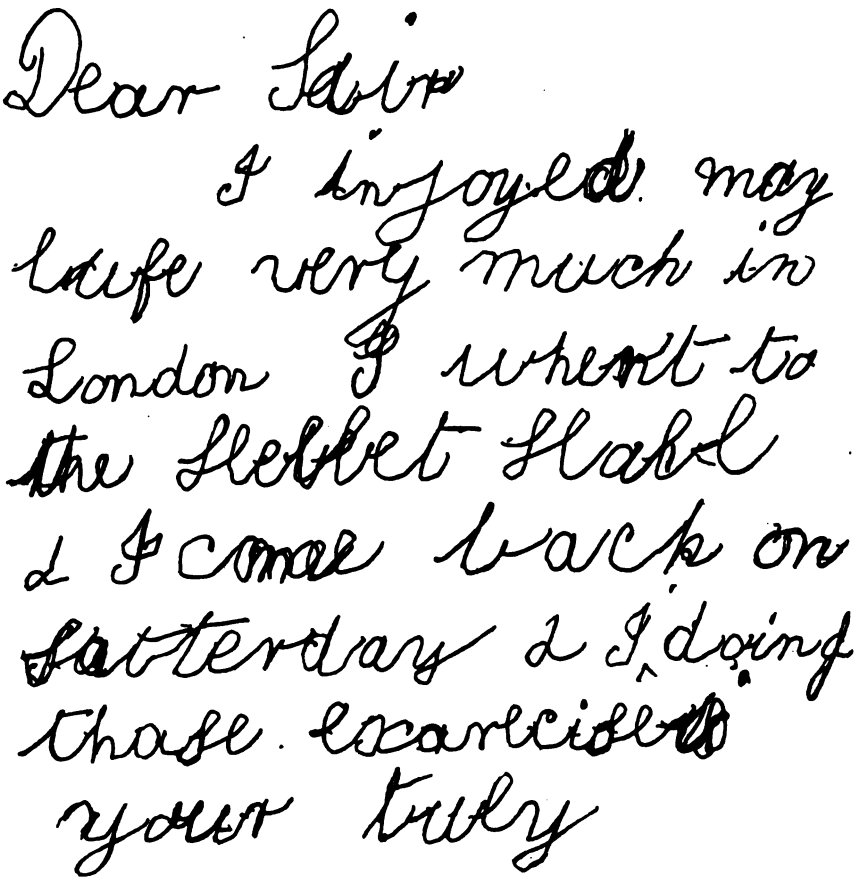

Dear Sir
I injoyed my
life very much in
London I whent to
the Hebbet Hall
& I come back on
Satterday & I doing
thase excarcised
your truly

arms very thin. He has no incontinence of urine. He talks very slowly, and does everything with great deliberation. He has no obvious aphasia, and understands what is said to him. He can read with difficulty, but understands very little of it. His vision is defective; the movements of the eyeball, like all other movements, are very slow. He has an internal strabismus with paresis of his right external rectus.

He has a good memory for past events if anything beyond the average. He is extremely slow in all his movements, and has to have help in fastening up his clothes as he says his fingers are so weak. His writing is very defective. The subjoined specimen of an original letter shows that the spelling is extremely defective, his hand is tremulous, and the writing not superior to that of a child of six. A letter from dictation is equally defective, and even an attempt to copy is not done accurately. He writes extremely slowly and with very great labour. He is able when entrusted with a message to remember it and to deliver it correctly. There can be very little doubt that he has a somewhat extensive encephalitis involving the left side of his brain, which has resulted in retardation of development, partial paralysis, and aphasia.

VI. '*A Case of Pernicious Anæmia presenting unusual features.* By WILLIAM PASTEUR, M.D. *Read November* 13, 1903.

SAMUEL B., æt. 24, an auctioneer's porter, was admitted under my care on June 24th, 1903. He had lost his father quite suddenly eighteen years before, and one sister and two brothers were also dead, but he was unable to give any information as to the causes of death. His mother was living, and was subject to rheumatism, and his two surviving sisters were delicate, one of them also a sufferer from rheumatism.

The patient himself was of fine physique, and had enjoyed excellent health until three weeks before admission. He was of temperate habits, free from syphilis, and always equal to his work, which was somewhat heavy. He had never suffered from rheumatism, nor was there any evidence of any previous gastric or intestinal troubles. He had never had much colour.

He felt faint whilst at work three weeks ago, and experienced a sense of dull pain at the pit of the stomach. He was compelled to leave his work, and has not been able to resume it on account of breathlessness, aggravated by the least exertion. There has been oozing of blood from the gums since the onset. There is no history of epistaxis or of bleeding elsewhere. The bowels have acted naturally throughout, and he had not suffered from headache or sickness before admission to hospital.

State on admission.—General nutrition good. There are a few small cutaneous hæmorrhages below the clavicles. There is profound anæmia of the skin and mucous membranes. The complexion is muddy and sallow, not lemon-tinted. The sclerotics are very slightly yellow. The superficial lymphatic glands are not enlarged. With the exception of marked pallor of the gums and tongue, and the slight oozing of blood at the insertion of the teeth, the mouth appears healthy, nor is there any history of previous trouble in this region. The teeth are in very fair condition. The lungs are healthy. The heart is slightly enlarged towards

the left, the impulse of fair strength, rather irregular and "quivering." The apex beat is in the nipple line behind the fifth rib. At the apex a soft systolic bruit is audible; at the base a systolic and a diastolic murmur are made out, the latter being heard as low as the fourth left cartilage, and occasionally at the apex. The pulmonary second sound is accentuated. The pulse, 108, is irregular and of low tension. The abdomen is natural. There is no enlargement of the liver and spleen, nor can any enlarged glands be felt. The bowels act regularly, and the stools present nothing abnormal. Urine: clear, light yellow, sp. gr. 1020, acid, contains no albumen nor sugar.

The patient had noticed a gradual failure of sight since his illness began, and on examination extensive hæmorrhagic neuro-retinitis of both eyes was revealed.

Progress of the case.—This can be told in a very few words. There were next to no objective symptoms beyond the anæmia, which did not vary appreciably. The patient was fairly comfortable as long as he kept quiet, but any movement, such as sitting up in bed, brought on marked shortness of breath. Towards the end he became more drowsy, and was slightly delirious at night. He took nourishment pretty well at first, but suffered frequently from attacks of vomiting, often twice a day. The diastolic murmur heard on admission proved not to be constant; it disappeared after a few days, and was only heard again once or twice. On July 16 the note is to the effect that "there is a short localised superficial diastolic bruit at the apex, probably exocardial."

The systolic (hæmic) murmur at the base was audible throughout.

The bowels acted fairly regularly throughout the illness, and the stools never contained blood.

The bleeding from the gums gradually diminished, and ceased on the sixth day after admission. Various local applications (adrenalin chloride, tannic acid) were employed, but their efficacy was doubtful. The bleeding recurred during the last week of illness.

The temperature on admission was 98° F. It was slightly above the normal on most evenings, 99° to 99·4°, and on one occasion, four days before death, reached 100° F. The morning temperatures were normal. The pulse varied between 92 and 120, and was often irregular.

The daily quantity of urine passed was frequently above

normal, 70, 80, 90, and once 108 oz. being recorded for the twenty-four hours. The specific gravity varied from 1011 to 1015. The colour was usually a light amber. On one occasion only it is described as being dark yellow. An analysis of the urine passed on July 20 showed total absence of albumen and albumose, while the total amount of chlorides excreted in the twenty-four hours was much below the average, measuring only 2·4 grammes.

The blood was examined by Mr. C. E. Lakin, M.B., on June 26, July 9, and July 13, with the results given in the accompanying table.

	Red corpuscles.	White corpuscles.	Hæmo-globin.	Colour ind.	Poikilo-cytes.	Megaloblasts and normoblasts.
June 26	1,550,000	5400	25 %	·8	None	None.*
July 9	1,040,000	3900	20 %	Slightly below 1	None	None.
July 13	1,090,000	2600	20 %	·9	None	None.

Leucocyte count.

	Total leucocytes.	Lympho-cytes.	Hyalin and transitl.	Polymorpho-nuclears.	Eosinophil myelocytes, mast cells.
June 28	5400	—	—	—	—
July 9	3900	60 % (2340)	24 % (936)	16 % (624)	None.
July 13	2600	74 % (1924)	6 % (156)	20 % (520)	None.

The following report on the condition of the eyes was furnished by Mr. W. Lang on July 22.

"There is well-marked hæmorrhagic neuro-retinitis in

* On another film taken by Dr. O. K. Williamson on June 26th, eight normoblasts were seen during the count of 581 white cells, but no megaloblasts. Some variation in size of blood corpuscles was also observed, but little, if any, alteration in shape. There was also marked relative lymphocytosis.

both eyes. Discs show about eight dioptres of swelling; margins ill-defined. Papillæ grey white in colour. Retinal vessels completely hidden at disc and very small in retina, which is filled with flame-shaped hæmorrhages and a few white patches of exudation."

Death occurred quietly on July 23, the total duration of the illness being just seven weeks.

Liquor Arsenicalis in 4 minim doses was given every four hours, but was interrupted twice on account of the sickness.

P.M. (twenty-one hours after death).—Rigidity moderate. Well built. Fair muscular development. Body well covered. No abnormal appearances externally. Skull and meninges healthy. Brain: Red points increased in lateral lobes of cerebellum and to a less extent in the medulla. Tongue, larynx, and trachea normal. No pleural adhesions; some soft exudation at back on left side. Lungs: œdematous. A few interstitial extravasations of blood; no scars at apices. Pericardium healthy; 2 to 3 oz. of clear fluid. Heart: 14 oz. Aortic and pulmonary valves competent and healthy looking. Mitral and tricuspid orifices both dilated. Heart wall the seat of rather extensive extravasation of blood, chiefly beneath the epicardium, but also, to a slight extent, beneath the endocardium. The anterior surface of the right ventricle is studded with petechial spots, but both anterior and posterior surfaces of the left ventricle show hæmorrhagic areas of some extent, which, when cut into, are found to penetrate the heart muscles to a depth of 3 or 4 mm. The muscle is firm, and does not exhibit any signs of fatty change to the naked eye. The thyroid is of good size, and appears healthy. The peritoneum is healthy. The stomach appears healthy. The solitary follicles are enlarged both in the small and large intestines. The mesenteric glands are slightly enlarged. The liver is brown in colour and of moderate firmness. The lobules are indistinct. Weight 56 oz. The cut section gives a good blue reaction with Pot. Ferrocyanide and hydrochloric acid. The gall bladder and ducts are healthy. The pancreas on section shows hæmorrhagic points, but otherwise seems healthy: the duct of Santorini is apparently not patent. The adrenals appear healthy. The spleen weighs 3½ oz., and gives a slight prussian blue reaction, but seems otherwise normal. The kidneys look healthy; right 7, left 8¾ oz. They give a slight prussian blue reaction. The testes give a very marked prussian blue reaction. The tubules can only with difficulty

be pulled out. There is no microscopical evidence of old interstitial inflammation.

Sections of the liver examined by Mr. Lakin in the Clinical Laboratory showed iron-containing pigment (prussian blue reaction) occupying the centres of the hepatic cell columns in the outer two thirds of the lobules. No pigment was to be seen in the capillary spaces. No free iron was found in the spleen, kidneys, or brain by micro-chemical methods. Sections of the testis,* however, showed the presence of coarse pigment situated in the tissue lying between the seminiferous tubules, the individual patches of pigment staining deep blue colour.

A bone-marrow film showed very few nucleated red corpuscles. Most of the marrow cells present were finely granular myelocytes. There were a few coarsely granular myelocytes. The film contrasted markedly with one made a short time before from a case of pernicious anæmia in which there were large numbers of nucleated red corpuscles. The number of nucleated red cells appeared to be smaller than in a film obtained for purposes of comparison from a man who had died from an accident.

Pieces of the liver, spleen, and kidney were analysed in the Chemical Department by my colleague Dr. Kellas, who has kindly furnished me with the following report:

"Estimation of iron in pieces of the liver, spleen, and kidney submitted for examination.

"*Methods.*—The material was crushed, dried, powdered, as far as possible, and finally dried at 100° C. until the weight was constant. It was then carefully heated in a platinum basin, ultimately to redness, until the weight was constant. From the appearance of the kidney ash the bulk of the iron was probably left as phosphate; in the other cases the appearance suggested that the iron was left chiefly as oxide. The ash was then heated on a water-bath with 20 c.c. normal sulphuric acid until solution was effected as ferric sulphate. The solution was then diluted to 100 c.c. Half this quantity was then taken and reduced by boiling in a small flask with 3 grammes of pure zinc and 40 c.c. of normal sulphuric acid. It was then filtered and titrated with a standard solution of dilute potassium permanganate. A check experiment was

* It was suggested by Dr. William Hunter, who examined a specimen, that the coarse pigment found in the testes was due to previous interstitial hæmorrhages. There was no sign of increase of connective tissue in the sections examined.

carried out with the quantities of zinc and sulphuric acid used, and a slight correction found to be necessary.

*Percentages of Iron (metallic) in Liver, Spleen, and Kidney.**

	Liver.	Spleen.	Kidney.
1. Case under consideration—3 analyses:			
August, 1903	0·572	0·412	0·145
December, 1903	0·423	0·355	0·219
December, 1903	0·420	0·356	0·219
2. Case of acute pneumonia (for comparison);			
December, 1903	0·157	0·291	0·090

Remarks.—This case is of interest in several particulars and very difficult to classify. The condition of the blood differed in almost every particular from that usually met with in the pernicious (idiopathic) anæmia of Addison, of which disease the case would appear to be an example, if we regard post-mortem evidence of excessive hæmolysis as one of the essential pathological features of that condition. Megaloblasts, which Ehrlich considers a constant feature of pernicious anæmia, were absent throughout. Poikilocytosis was also absent. The oligocythæmia was by no means extreme, but this may vary considerably in pernicious anæmia. Leucopenia associated with high relative lymphocytosis and almost total absence of normoblasts clearly suggests that a complete failure of regenerative activity of the bone-marrow

* The figures obtained in the July series of analyses were so different from what I had expected that Dr. Kellas kindly made two more analyses for me from portions of the organs which had been preserved in a weak solution of formalin. I have placed the results of these later analyses alongside those communicated to the Society in November. The close agreement between the two latter series of observations vouches for the extreme care with which Dr. Kellas has carried out his experiments. The discrepancy between them and the August series is explained by Dr. Kellas as follows:—"In the case of the liver and spleen iron has been extracted to some extent on standing. I have found that the liquids in the jars in which the organs stand contain iron—perhaps in suspension. In the case of the kidney the sample contained fat in the August analyses, whereas the last samples contained only kidney substance." This observation is of interest and of some importance. Cf. also foot-note on p. 41.—W. P.

was one of the essential factors in the case. The clinical picture also differed in many particulars from that usually presented by a case of Addison's anæmia, notably (*a*) in the absence of the signs of intense hæmolysis such as lemon tint of skin, dark-coloured urine, and febrile exacerbations; (*b*) in the short duration (fifty days) and sudden onset of the illness; (*c*) in the extent and degree of the retinal changes: and on the pathological side; (*e*) in the absence of naked eye evidence of fatty degeneration of the heart muscle. On the other hand the analyses of the liver, spleen, and kidneys show in a very striking manner (*a*) the large excess of iron,* and (*b*) "the peculiar distribution between liver and spleen—the reversal of that usually obtaining" to which William Hunter attaches importance in the diagnosis of Addison's anæmia from other forms of fatal anæmia. Relying on these results I conclude that this is a case of idiopathic pernicious anæmia with very unusual clinical features and blood condition.

* It is matter for regret that the microscopic section of liver shown at the meeting had lost a good deal of colour, and quite failed to convey an adequate idea of the large amount of blue pigment it contained when first put up. Dr. Lazarus Barlow, who saw it then, hardly recognised it as the same specimen a few weeks later. He tells me that he has met with a similar loss of colour on a previous occasion.

VII.—*A Case of Chronic Intussusception; excision of forty-two inches of small intestine; recovery.* By F. C. Wallis, M.B. *Read November* 27, 1903.

E. S., a healthy-looking married woman, æt. 32, was admitted to Charing Cross Hospital on April 14, 1903, suffering from intestinal colic.

The patient was in perfect health until May, 1901. Previous to this she had never had a day's illness in her life. The bowels always acted with great regularity, and aperients were rarely necessary. She had never suffered from diarrhœa.

The present illness began in May, 1901, with a sudden onset of most acute pain in the abdomen (there was no cause for it as far as she knows). The pain was of a colic character, but not sufficiently bad to make her take to bed until the end of the week, when the attacks became more frequent, and vomiting commenced. Food always excited the colic, and vomiting always followed it. She described an attack as a "general turning-round-and-round feel in the stomach, followed quickly by vomiting." This attack lasted three weeks, and she was in Guy's Hospital for the latter part of it. After this she was perfectly well until *August,* 1901, when she had a similar attack, and there was a third attack in *September,* 1901. These attacks resembled the first, except that the bowels were obstinately constipated for three to four days. When the bowels acted she was much relieved, and the attack would generally pass off. There was no constipation at the beginning of an attack, but pain and vomiting preceded it for three or four days. After the third attack she continued well until June, 1902, when there was another attack, since when there have been many milder in degree, but all similar in character to the first. She has never passed any blood or mucus in the motions. The abdomen never swells, and pressure neither increases nor relieves the pain. No tumour has been felt.

She was admitted into the medical ward of Charing Cross Hospital during one of these attacks of pain, and was in for five days, leaving on April 18, 1903, apparently quite well.

She was re-admitted on April 22 for another attack of

pain, during which vomiting was more or less continuous; it was bile-stained, but not offensive. The abdomen was lax and not tender (this condition existed during all these attacks).

On April 25 an indefinite mass was felt below and to the left of the umbilicus.

It was decided that unless a distinct improvement took place in the next twenty-four hours, an exploratory laparotomy should be performed.

As the patient was no better, in fact getting weak, I operated at 11 A.M. on April 25, 1903.

When the patient was under the anæsthetic, a large, freely movable mass could be felt in the left umbilical region. The abdomen was opened in the mid-line below the umbilicus by an incision, lengthened to five inches in all. The palpable mass was an intussusception involving small intestine only. The length of bowel involved amounted to three feet six inches. The proximal gut was materially distended.

An unsuccessful attempt was made to reduce the invagination, and enterectomy was decided upon. Whilst lifting the involved gut out of the abdomen the distal end tore like a piece of wet blotting-paper, close to the end of the intussusception, and it was noticed that this part of the bowel was much inflamed. The intestinal contents were expressed at either end, and Lane's intestinal clamps applied on healthy bowel. The bowel was divided first at the upper end, and the mesentery cut through parallel to the intestine, the vessels being clamped as they were cut. The intestine was divided at the lower end, and the two ends united with a Murphy's button. A few Lembert sutures were put in in addition, and the cut edges of the mesentery were sewn together with silk sutures, the vessels being ligatured with silk also. Some hæmorrhage found its way between the layers of the mesentery. The parietal wound was closed by one row of separate fishing-gut sutures. The operation lasted one hour—the patient stood it very well;—pulse 120 at the end. One pint of beef-tea given by the rectum. There was practically no shock from operation.

The patient was nourished by rectal enemata only for two days; on the third day small quantities of plasmon and thick barley-water were given by the mouth, and on this day the bowels acted twice, the motions being well formed. The food by the mouth was gradually increased, and the rectal feeding discontinued; the stitches were removed on the eighth

day, and everything went very well indeed until May 15, three weeks after the operation, when the patient had an attack of pain similar to those she had previously suffered from. Paroxysmal colic with intervals free from pain. Chloroform was administered, and on palpating the abdomen I could feel the button in what I thought was the descending colon; it was quite easily pushed down into the pelvis, but it could not be reached by the rectum.

No button was passed, and the pains continued. On May 18 the button was seen by the X ray to lie on the outer side of the right rectus, two inches above the inlet of the pelvis.

On May 19 I reopened the abdomen, and found the button about four inches above the ileo-cæcal valve; it could not be passed on into the colon, so I removed the button through a longitudinal incision, which was sewn up transversely.

From this second operation the patient made a perfect recovery, and left the hospital quite well on June 10.

I saw her last a fortnight ago in the best of health.

The following is the pathologist's description of the specimen:—"No. 1223. Enteric intussusception in adult. Forty-two inches of small gut excised. A portion of small intestine, 67 cm. (26½ inches) of which forms the outer coat (Intussuscipiens) of an intussusception which has been greatly reduced, a double layer, 18 cm. (7¼ inches), now remaining invaginated. The apex of the intussusception shows considerable reddening, and is thickened from inflammation and œdema. The returning sheath is greatly thickened. The indrawing of the mesentery is well shown. The outer coat is considerably dilated and somewhat irregularly thickened. Here and there congested vessels may be seen. Eight centimetres (3 inches) from the lower end is an oval opening 2 cm. in diameter, which seems to have been torn—its edges are irregular; *microscopically* the gut near the orifice is in parts quite healthy, in others swollen and infiltrated with round-cells."

When the intussusception was first exposed, and before the mesentery was divided, the apex of the intussuscepted part was close up to the inflamed part of intestine which tore apart when the intestine was lifted out of the abdomen; but after removing the intestine the intussuception slid back to its present position, although when *in situ* it was quite impossible to reduce it in the slightest degree.

The *contretemps* with the Murphy's button was unfortunate. It is the only time that I have ever had any trouble,

PLATE III.

Illustrating Mr. F. C. Wallis's Case of Chronic Intussusception.

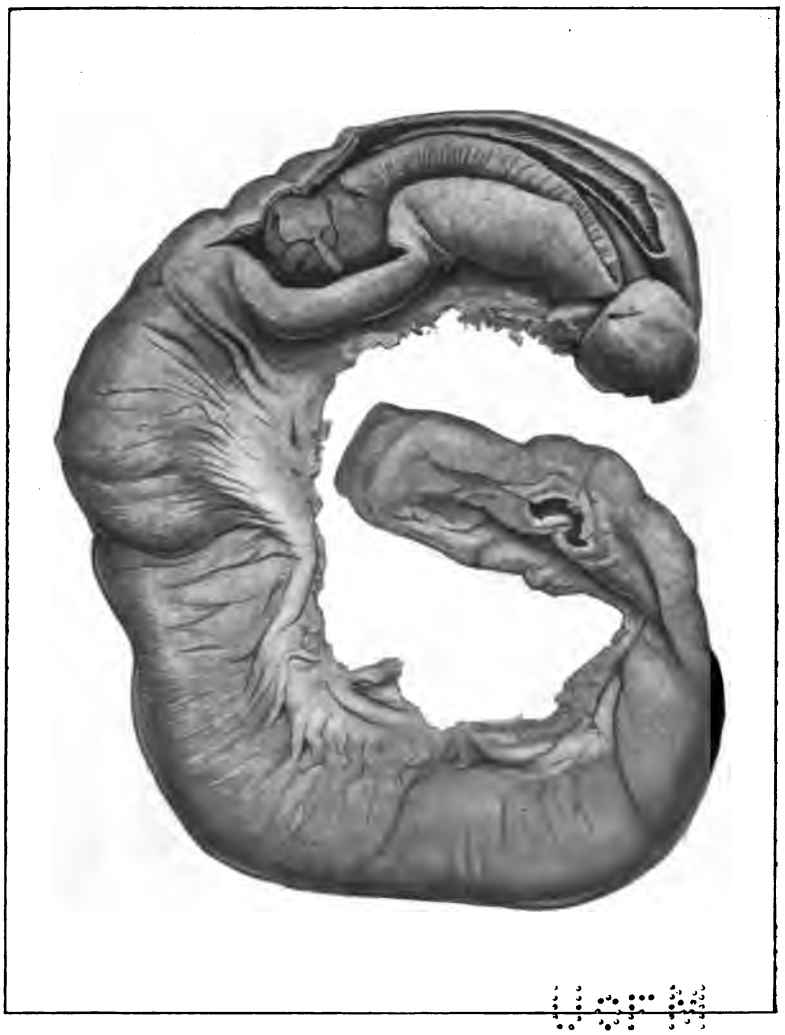

Bale and Danielsson, Ltd.

Microfilm

and I have used these buttons now in a large number of cases. It was due to the fact that I put in a button somewhat larger than the size generally used for small intestine. My reason for doing so was that the proximal end of the intestine was considerably distended, and the slightly larger button made approximation easier. It did not occur to me at the time that there would be any difficulty in the passing of the button, and ordinarily speaking I do not think that there would be any difficulty in its passage. In an urgent operation of this magnitude time was of the greatest consequence, and I do not know any other means by which the two ends of the intestine could be so rapidly and securely brought together. The main part of the time taken (one hour) was spent in cleaning the skin of the abdomen, removing the intestine, tying a large number of vessels, and uniting the widely separated ends of the mesentery. The sewing in and clamping of the two ends of the button did not take more than five minutes.

Why the gut should have torn in the way it did was a matter of some speculation, and a microscopical examination of the torn edge showed only inflammatory infiltration. I believe the softening of the intestine here was due to interference of the blood-supply, and there is no doubt that perforation would have occurred at this spot very soon.

As to the cause of the intussusception, there is nothing to show that it is due to anything but an irregular action in the muscular wall of the intestine.

Cases of chronic intussusception are not uncommon, but one such as this is, I think, worth recording.

The points of interest are—

1. The length of time—over two years—which it lasted.
2. The excellent health of the woman between the attacks and, I am glad to say, since the operation.
3. The large amount of small intestine involved. Most cases of chronic intussusception have to do with the large intestine.
4. The fact that no tumour was felt with any certainty until the patient was anæsthetised.
5. There was no exciting cause, such as a growth, tumour, or ulceration, which is commonly the starting-point in cases of chronic intussusception.

VIII.—*Two Cases of Leucocythæmia (Lymphatic Leukæmia).* By Frederick Taylor, M.D. *Read November* 27, 1903.

Case 1.—William G., æt. 10, a schoolboy, was admitted into Guy's Hospital on August 31, 1901. He has always been a nervous child, but otherwise strong and healthy. He had measles and whooping-cough when quite young, and scarlatina two years ago, since which time he has been dull and more nervous.

Two months ago he first complained of pain in the legs and aching in the popliteal space. He felt tired, was very thirsty, and was continually yawning. His eyes became bloodshot and swollen, and the nervousness increased.

He came up among the out-patients two weeks ago, when the following points were noted:—Enlargement of the left parotid gland; an area of percussion-dulness above the right nipple and over the upper half of the sternum, continuous with the normal cardiac dulness; absence of breath-sounds over the dull area; cardiac impulse half an inch external to the nipple; a deep-seated tumour in the left flank, apparently independent of stomach or spleen; hepatic dulness normal; no enlarged glands.

On admission.—The face is swollen, especially the upper and lower eyelid. There is distinct enlargement of the two parotid glands and of the submaxillary glands; those are larger on the left side. The glands in the former are slightly enlarged. The fauces are unduly red, and the tongue furred, but the lips, teeth, gums, and tonsils are normal.

The abdomen is full and rounded, but not tense. The edge of the liver can be felt an inch and a half below the costal margin, and the hepatic dulness extends from the upper border of the sixth rib to one inch below the costal margin. In the left flank is a tumour, which is now larger than it was two weeks ago; it is firm, but not markedly hard, presents no notch, and allows a resonant note on percussion. The fingers can be placed between its upper end and the left costal margin. The spleen cannot be felt.

The epigastric angle is narrow, the two sides of the chest move equally. A dull area is found over the right nipple and

over the sternum, continuous with precordial dulness; breath-sounds are deficient over this area, but elsewhere are normal. The larynx is normal. The heart's impulse is felt in the left sixth intercostal space, three quarters of an inch external to the nipple. The sounds are normal; the pulse is 82, regular, the same on the two sides.

The pupils react to light and accommodation. The fundi show large and very tortuous retinal veins, and the left disc is red and slightly œdematous, but there are no hæmorrhages.

FIG. 1.

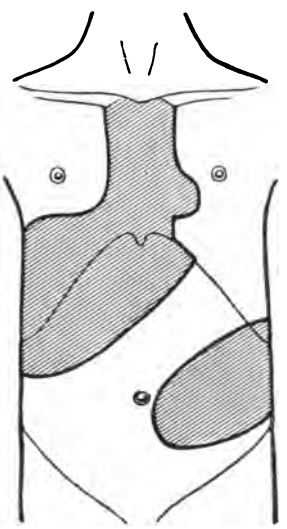

A blood-count shows, red corpuscles 5,600,000; white corpuscles 15,000.

A differential count of the latter gives—

Small lymphocytes . . .	46·6
Large „ . . .	9·3
Polymorphonuclear leucocytes .	42·1
Eosinophiles	2·0
	100·0

On a blood-film one nucleated red corpuscle was seen.

The urine was of sp. gr. 1010, pale straw colour, neutral reaction, contained 1 per cent. of urea and no abnormal constituents.

On September 6 the tumour in the flank nearly reached the middle line (see Fig. 1), and the liver was obviously much enlarged.

On the 9th it is noted that the left parotid swelling is much larger, and that a large and lymphatic gland can be felt in the neck. The anterior border of the parotid is two inches from the lobule of the ear. On the 18th it had extended another quarter of an inch forwards.

Just behind and below the lobule of the left ear is a

FIG. 2.

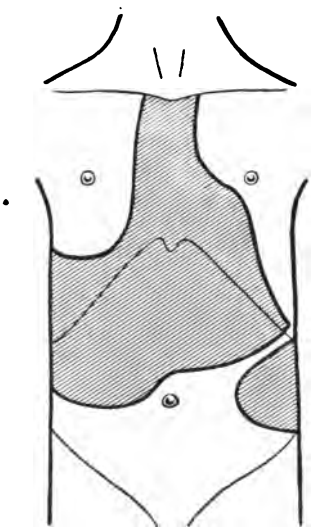

roundish lymphatic gland, about one inch in diameter, which makes a prominence on the skin.

The right parotid is very little enlarged, but a lymphatic gland can be felt just below and in front of the lobule of the ear, and another behind the pinna. On each side there are two glands felt below the mandible, the anterior the size of a haricot-bean, and the posterior as large as a pea (see Plate). The left sublingual gland appears to be enlarged as felt from the mouth. On each side at the occiput is a gland the size of a pea.

Each lachrymal gland can be felt as a rather hard mass, and the swelling of the upper eyelid is partly due to the enlargement of the gland and partly to œdematous tissue in front of it. The skin here is slightly pinker than normal, and

its veins are prominent. There is no increase of the glands in the neck, axilla, and groins; the largest gland felt in the groin measures 6 mm. by 4 mm. There is now a continuous dull area over the front of the trunk, including the sternum and adjacent costal cartilages, the precordial area, the liver continued down nearly to the umbilicus and the before-mentioned tumour in the flank (see Fig. 2). This tumour is separate from the liver, and reaches to within an inch of the umbilicus. The liver reaches an inch or more below the horizontal umbilicus level in the nipple-line, and its edge is traceable just above the umbilicus to the left costal margin in the nipple-line. Below there is a hard mass extending two or three inches below the right twelfth rib, apparently separate from the liver, and no doubt an enlarged kidney.

The spleen cannot be felt.

A blood-count gives now: Red corpuscles, 4,400,000; leucocytes 50,000.

Differential count—

Small lymphocytes . . .	94
Large „ . . .	3
Polymorphonuclear leucocytes .	2·5
Eosinophiles	·5
	100

Hæmoglobin 70 per cent.

September 19.—Some hæmorrhage from the gums.

September 23.—More hæmorrhage from the gums, and a small extravasation of blood into the left conjunctiva. Abdomen increasing in size.

September 25.—Patient more prostrate. Temperature rises to 101° and 102°. Pulse 130. Ecchymosis of both upper eyelids; petechiæ in skin of abdomen. Continued bleeding from gums.

September 30.—Bronchial breathing at upper part of right chest behind. In the evening vomiting of blood; this continued throughout the night, so that some pints of blood were brought up, and he died at 5 A.M. on the 27th.

The *post-mortem* examination was made by Dr. Bryant, whose report is as follows:—

The body was very pale and had a swollen, bloated appearance. There was a good deal of œdema of the lower extremities. There was no meningitis. The brain did not show any abnormal changes.

Both lachrymal glands were much enlarged, particularly the

right, which was twice as large as the left. On section these glands had a sodden and congested appearance. The parotid gland, especially the right, was also enlarged, and on section presented a congested appearance. A considerably enlarged lymphatic gland was found just below the left parotid. The submaxillary glands were enlarged, and also some of the lymphatic glands which were adjoining them. The cervical glands were slightly enlarged. The thymus was very much enlarged; it weighed 586 grammes, and was larger than a normal sized kidney. It was pale yellow, and on section presented a fatty semi-translucent appearance. There was a good deal of hæmorrhage into it. The hæmorrhages were small and irregularly distributed. The thyroid presented a normal appearance, and was not enlarged.

There were numerous subpleural ecchymoses over the posterior surfaces of both lungs. The lower and outer part of the lower lobe was compressed, and the pleura covering it had a few flakes of recent lymph on it. On section the lungs were rather paler than normal, and numerous hæmorrhages into their substance were found. The mucous membrane of the larynx, trachea, and bronchi was pale and ecchymosed. The lower end of the trachea and the upper part of the bronchi, especially the right, were considerably flattened from the pressure of the enlarged thymus. The bronchial glands were not enlarged. There was no pericarditis, but there were numerous subpleural ecchymoses, and there was also a little clear serous fluid in the pericardial sac. The heart weighed 165 grammes. On the whole the myocardium was decidedly paler than normal, but in parts it was very much paler than in others, as if it was infiltrated with some new growth. Over the anterior and upper part of the interventricular septum there was a distinct swelling, which on section appeared to extend deeply into the myocardium. It was pale yellow in appearance, and resembled the pale areas mentioned above. In places there were hæmorrhages into the myocardium. The valves were healthy. The coronary arteries appeared to be healthy. The tonsils were slightly enlarged, but there was no ulceration nor sloughing.

The œsophagus was healthy. The stomach contained a good deal of dark brown, altered blood. The mucous membrane of the stomach was much ecchymosed. I could not find any ulceration. The hæmatemeses must have been due to an oozing from small vessels. The small intestine contained a good deal of blood. No peritonitis.

The liver was enlarged. It weighed 2300 grammes. It was much paler than normal. No other macroscopic change could be made out.

Lymphatic glands not much enlarged.

The spleen weighed 508 grammes. It was pale. It did not contain any nodules such as are found in cases of Hodgkin's disease. There were a good many small hæmorrhages beneath the capsule.

The supra-renal capsules appeared to be normal. The kidneys weighed 1100 grammes. They were both much enlarged, and, as far as could be judged, were lying in the abdominal cavity in their normal positions. The capsule was not thickened nor was it adherent. The surfaces of both kidneys were quite smooth. The appearance, however, was most unusual, for the cortical substance was very pale, being of a dull greyish yellow, and this was mottled with large areas of hæmorrhage, some of which were from 10 to 20 mm. in diameter. On section the whole of the kidney substance was pale and dull yellowish, and both in the cortical and pyramidal portions it was mottled with small and large areas of hæmorrhage.

Microscopical examination. — Kidney. — There was an enormous infiltration of the connective tissue with lymphocytes, the tubules and the glomeruli being widely separated in consequence; in fact, there were more lymphocytes than anything else. The general appearance of the section was that of a matrix of lymphocytes studded with a few urinary tubules and glomeruli. The nuclei and protoplasm of the epithelium of the tubules were stained very faintly in comparison with the lymphocytes. Many of the tubules contained granular *débris.* In places there was a good deal of yellowish-brown pigment in the connective tissue mixed up with the lymphocytes.

Heart.—In places there was a considerable infiltration of lymphocytes into the connective tissue between the muscle-fibres, so that they were surrounded by lymphocytes. There were larger collections of lymphocytes in the connective tissue surrounding the branches of the coronary arteries. Many of the muscle-fibres which were surrounded by the lymphocytes had rather a blurred appearance, the striation not being very apparent, but the nuclei staining well. There was neither fatty nor pigmentary degeneration of the muscle.

Liver.—There was general and considerable infiltration of

lymphocytes between the liver-cells, and also local collections of lymphocytes between the lobules. There were also many granules of brownish pigment scattered about, some in the liver cells and some with the lymphocytes.

Spleen.—This organ appeared to consist of a large mass of lymphocytes, mostly of small size. The Malpighian corpuscles did not appear to be altered, and the stroma was not thickened.

Supra-renals.—The supra-renals were packed with lymphocytes, very little of the normal structure being visible, and that only in streaks and patches.

Pancreas.—The pancreas was normal. There was no infiltration of lymphocytes. The only lymphocytes seen were in the blood-vessels.

Thymus.—This organ showed large spaces packed with lymphocytes and surrounded by a fairly well-marked fibrous stroma.

Parotid gland.—This gland was thickly infiltrated with lymphocytes, and a good many very large round-cells with comparatively small nuclei were found.

Lachrymal gland.—This enlargement was entirely due to the lymphocyte infiltration.

Lymphatic glands.—The glands were packed with lymphocytes. The stroma was not thickened.

Bacteriological examination.—Microscopical examinations and cultures from the kidneys, spleen, blood, and thymus did not show the presence of any organisms. A rabbit was inoculated from the kidney, and died a month afterwards. Diplococci were found by culture and by microscopical examinations, and were identified as pneumococci.

Case 2.—Ada M., æt. 14, was seen by me in consultation with Dr. John Tanner, on January 15, 1902. The history I obtained was to the effect that she had been well till about six weeks previously, when she had pains in her limbs and felt unwell. It had also been noticed for about six weeks previously (that is, three months altogether) that her mammæ were becoming unusually large for one so young. Fourteen days ago her eyes became prominent, and her feet were observed to be swollen two days ago.

She is a well-developed and well-grown girl, with a white face, but no extreme pallor of the lips. She lies far over on her left side, burying the left side of the face in the pillow. She is breathing rapidly and is very unwilling to be dis-

turbed, and to that extent caused some difficulties in the examination.

The eyes are prominent, and there is in addition œdema of the upper and lower eyelids; but I could not feel distinctly any enlarged or hard lachrymal gland. The parotid gland on each side was distinctly outlined without being much enlarged; the submaxillary gland on each side formed a distinct prominence beyond the line of the jaw. The breasts were of considerable size for a girl of her age, rounded and normal in outline, and of equal size. I did not measure them, but I estimated them afterwards from memory as probably $4\frac{1}{2}$ inches in diameter, with a projection of $1\frac{3}{4}$ to 2 inches. They were in addition firm and nodulated throughout, and over each was a large dark tortuous vein, such as is seen in the breast of pregnancy or lactation. The liver was enlarged, and its edge could be felt fully one inch below the umbilicus horizontal level; it was of firmer consistence than in health, but not really hard. The edge of the spleen could be felt just beneath the left costal margin, and descended nearly an inch below it on deep inspiration. There were no very large glands on the groins, neck, or axilla; one the size of a pea could be felt in the right posterior triangle, and in each groin one or two slightly smaller. The heart was beating rather violently, with impulse on the fifth interspace; a cantering rhythm at the apex, but no murmur. The respiratory murmur was weak at both pulmonary bases, with an occasional slight sibilant or mucous *râle*. The feet were a little puffy-looking, but did not readily pit on pressure.

Dr. Tanner informed me that there was no albumen in the urine. The pupils were of moderate size and reacted to light; the child was so unwilling to assist that a good view of the fundus could not be obtained, but there was certainly retinal hæmorrhage in each eye. A drop of blood was drawn from the finger and films obtained. The blood was exceedingly pale and thin.

The films stained with eosin and hæmatoxylin and eosin and methylene blue showed an enormous number of lymphocytes. I had no apparatus for counting the corpuscles; but in parts of the films the leucocytes were densely crowded together, and appeared even to outnumber the red corpuscles. The small lymphocytes were obviously greatly in excess, and I estimated them at 95 per cent. of all the leucocytes. I submitted two films to Mr. G. L. Eastes, and he gave me the following report:

"*A differential count* of 1000 white cells in each slide gives the following proportions:

Small lymphocytes . . .	= 95·8	99·5
Large „ . . .	= 3·7	
Polymorphonuclears . .	=	0·5
		100·0

"During the count six nucleated blood-discs were seen, five of which were normoblasts. One was a microblast. Three myelocytes were also seen. The differentiation between small and large lymphocytes is very difficult, the two varieties shading imperceptibly into each other; doubtful forms have been enumerated with the type to which they most closely agree. The count has been one of great difficulty to me, as I am accustomed to the triacid stain, and the figures are therefore open to criticism."

On February 14 Dr. Tanner gave the following memoranda:—The patient was steadily getting worse, the parotids were very much enlarged, the breasts were a little larger than formerly, and there was considerable dropsy of the feet, legs, and abdomen, with some ascites. In the interval there had been a good deal of epistaxis and uterine hæmorrhage, the blood in each instance being very watery. The liver appears to be about the same size. For the last week she has sat up in a chair, leaning the head on one hand, with noisy, panting respiration, about thirty to the minute, and rapid, violent action of the heart. She is not febrile.

She died on February 21.

The above cases are offered as a contribution to the subject of leukæmia. They are cases, acute in their course and belonging to the group of lymphatic leukæmia or lymphocythæmia, cases of which the characteristic is not so much a hyperplasia of the lymphatic glands as the presence in the blood of an enormous number of so-called lymphocytes.

The occurrence of such cases was shown by Fraenkel, and Drs. Bradford and B. Shaw recorded similar cases at the Royal Medical and Chirurgical Society in 1898.* In all of those the hypertrophy of the glands was by no means prominent, and the early symptom was often a condition of inflammation and sloughing of the gums, which at first led to a misapprehension of the nature of the cases.

* *Med.-Chir. Trans.*, vol. lxxxi, p. 343.

Both of the present cases were children under puberty. The course was in both cases a matter of a few months: three months in the boy, and perhaps three months and a week in the girl.

The lymphatic glands were in neither instance markedly enlarged. In the boy, after two months' illness, the "glands in the groin are slightly enlarged;" and at the *post-mortem* a month later it is stated that "the lymphatic glands are not much enlarged." In the girl, after six weeks' illness, while other organs were much involved, there were no very large glands in the neck, groins, and axilla; one the size of a pea could be felt in the right posterior triangle, and in each groin one or two slightly smaller.

In regard to the remaining conditions, the boy and girl present a close likeness in the remarkable enlargement of the various secretory glands.

In both the parotid and submaxillary glands were early involved, and the liver and spleen were much enlarged. In the boy the kidneys were more than three times the normal size of adult kidneys; but in the girl they were not obviously big a month before death, and no *post-mortem* was made.

In the boy a remarkable feature was the enlargement of the lachrymal glands, which could be felt and seen projecting under the supra-orbital ridges comparatively early in his illness. *Post mortem* they were found to present hard, firm bodies, and one of them measured 1 inch by $\frac{3}{4}$ inch diameter.

In the girl, on the other hand, a noticeable feature was the size of the mammæ. When I saw her in the sixth week of her illness these were large and prominent—not perhaps larger than may be seen in other well-developed girls of her age; and moreover she was a big strong girl, who could, Dr. Tanner tells me, lift the cook, a big woman, and carry her round the room. But the glands were not only large, they were hard, nodulated, and each presented a large, tortuous vein, indicative of unusual growth or activity.

In the further progress of the cases the disturbances which commonly result from these allied conditions ensued, namely, dropsy and hæmorrhages.

The boy in his last days suffered from hæmorrhage in the gums, echymosis of the eyelids and conjunctiva, and a final hæmatemesis, while considerable hæmorrhages were found *post mortem* in the kidneys.

The girl had dropsy of the feet, legs, and abdomen, and hæmorrhage from the uterus and epistaxis.

At the *post-mortem* of the boy Dr. Bryant found a pronounced infiltration with lymphocytes of the connective tissue of every organ, namely, the kidneys, heart, liver, spleen, supra-renal capsule, pancreas, thymus, parotid gland, and lymphatic glands.

Leucocytosis was present in each case, and the prevailing leucocytes were of the lymphatic variety; that is, they were lymphocytes.

The dates of the occurrence of the lymphocyte excess seem to have been different; at any rate in the boy, when he had been two months ill, and the liver, spleen, parotid, and submaxillary glands were much enlarged with what histological examination subsequently showed to be lymphocyte infiltration, the blood showed only 15,000 lymphocytes per c.mm.—an estimate not much above the normal. This, however, was not a mere leucocytosis, since the blood-count showed that 55 per cent. of the leucocytes were lymphocytes.

About ten days later, however, the leucocytes had risen to 50,000 per c.mm., of which 97 per cent. were lymphocytes. This number is of course not extreme, but it is probable that in the remaining eighteen days of his life the leukæmia became still more pronounced.

In the case of the girl no estimate of the leucocytes per c.mm. was made, but the appearance of the film taken in the sixth week of the illness, when the parotid, liver, spleen, and mammæ were enlarged, and the child's cardiac distress was considerable, gives the impression that the leucocytes must have been very much more numerous than the number estimated in the former case.

I do not, upon the slender basis of these two cases, propose to solve the many questions as to the nature and varieties of leukæmia. They are in agreement with other recently published cases in their rapid course and in the comparatively slight enlargement of the lymphatic glands.

The broad distinction between typical spleno-medullary leukæmia and the present cases, which lies in the presence of myelocytes in the former and of lymphocytes in the latter, seems justified, but the theories as to the source of the leucocytes in both cases may be debated. It has been argued that the polymorphonuclear leucocytes naturally arise from myelocytes in the bone-marrow, and that myelæmia is the result of a primary disease of the bone-marrow. On the other hand, the multiplication of lymphocytes, as seen in the present cases, is referred to a primary aberration on their part

rather than to disease of any one organ. What these cases, with others, seem to suggest is that lymphatic leukæmia, lymphocythæmia, or lymphæmia, is *not* primarily a disease of the lymphatic glands. This is shown by the great enlargement of the various organs, shown *post mortem* to be due to lymphocyte infiltration, at a time when the blood contained only a moderate excess of these elements and the lymphatic glands were scarcely enlarged at all. If these lymph-glands were the sole factors or the chief factors of the corpuscles, it seems incredible that they should not have shown some obvious signs of the excessive discharge of their functions, and the blood should not have earlier or more abundantly changed with them.

Of organs directly related to the blood there remain the thymus and the spleen. The spleen was not prominently enlarged during life, and was only three times the normal size on *post-mortem*. But the thymus, with its persistence and enormous size taken together with its morbid enlargement in some other leukæmic cases, may possibly be suspected of some share in the pathology of the complaint.

The illness in these two cases occurred at a time when normally the thymus was still present, if, as stated by Sir John Simon, it remains more or less perfect up to eight or twelve years and only entirely disappears about the twentieth year. But I find that the thymus was present in the four cases recorded by Drs. Bradford and Shaw which were submitted to *post-mortem* examination. In the man æt. 30 it measured 3 inches by $1\frac{1}{2}$ inches; in the man æt. 58 it was persistent; in the youth æt. 19 it measured 3 inches; and in the boy æt. 7 it was present, but not particularly enlarged.

The relative enlargement of the glands in the girl agree in the main with what was found in the boy. The liver, spleen, mammæ, and salivary glands were very large, with a considerable leukæmia, when the lymphatic glands were little, if at all, above the normal. I have no information as to the thymus.

The similarity of the two cases lies in the early enlargement by lymphocyte infiltration of the different glands, and especially of the secretory glands of the racemose type, such as the lachrymal, salivary, and mammary glands.

They differ from the cases published by Drs. Bradford and B. Shaw in the fact that there was sloughing of the gums or gingivitis, and in the lymphocytes being of the small variety; but in many other respects—their acute course

and the insignificance of the enlargement of the lymph-glands—they resemble them. Whether this difference in the condition of the gums is essential may be doubted. An undue liability to suffer infection by destructive organisms may exist in all and be realised in some of the cases only. Hæmorrhage at least occurred from the gums in the boy.

Fever was not a prominent feature in either of the cases. In the last four days of the boy's life the temperature was between 100° and 102°, but on the six preceding days it was only between 98° and 99°. Only on six occasions (from hourly observations) rising above 99°, and never higher than 101°.

The girl's temperature was not fully recorded, but she was not febrile till near the end of her illness.

PLATE IV.

Illustrating Dr. Frederick Taylor's Case of Leucocythæmia.

FIG. 2.

FIG. 1.

Bale and Danielsson, Ltd.

Mau

IX.—*A Case of Post-operative Hernia treated by the Introduction of Prepared Silver-wire Filigree.* By Lawrie McGavin. *Read November* 27, 1903.

THE use of prepared silver-wire filigree for the cure of post-operative umbilical and other herniæ is of comparatively recent introduction; and, although I am aware that many surgeons, among whom may be mentioned Schede, Witzel, Barker, and others, have endeavoured to overcome the difficulty of closure of large deficiencies of the abdominal wall by the weaving in of silver wire in the course of the operation, or by simple forcible apposition by sutures of the same material, I am as yet unaware of the performance of any operation in this country in which the method suggested and practised by Willard Bartlett in America has been employed; a method which I think has much to recommend it, and which consists of the introduction into the tissues of a prepared network of silver-wire filigree. Having recently had the opportunity of applying this method, I am tempted to bring the case before the notice of the Society, partly as one of clinical interest, but chiefly in the hope of hearing the experience of other surgeons on the subject with which this paper deals.

The history of this case is as follows:

The patient, who first came under my care in July of this year, is a woman æt. 45, of spare build, healthy in every other respect than that for which she came to me, and having the prospect of many years of active life before her, but for her hernial condition.

About fifteen years ago, while in Australia, she underwent an operation for the removal of a fibroid tumour of the uterus; this was apparently incomplete, and Apostoli's method was tried; subsequently a pelvic abscess developed, the wound broke down, and in a few weeks a ventral hernia commenced to form.

On inspection I found the abdominal cicatrix much stretched and thinned out, primary union having obviously failed; and her condition one of great discomfort and considerable danger. On causing her to stand up the whole of

the supra-pubic region bulged markedly forwards and assumed a roughly lobulated appearance, the actual dimensions of the swelling being five inches vertically from immediately above the pubes and about four and a half in the transverse direction, the centre being rather to the left of the middle line. The skin was not adherent to the mass, but beneath it were four or five hard lobulated tumours, some of them as large as a walnut, which were persumably composed of omentum. On coughing the tumour bulged at a point two inches below and to the left of the umbilicus, and here bowel could be felt and partially reduced. The hernia was tender to pressure, and the patient complained of increasingly frequent attacks of painful dragging sensations when walking or standing. Frequency of micturition was rather troublesome and showed signs of becoming worse, and at times there were griping pains on defecation, accompanied by nausea and sometimes by retching. No part of the tumour could be completely reduced, and it was clear that if such reduction was to be brought about by operation, a considerable amount of tissue would have to be sacrificed, and the prospect of a permanent cure was therefore very slight.

I accordingly determined to deal with the case by Bartlett's method, and following the directions of that author,* I manufactured a filigree of silver wire, using No. 27 gauge, and making about twenty loops on each side; when finished it measured five inches in length by two and a half in breadth. This was washed in ether and thoroughly sterilised.

At the operation I found the recti muscles separated by about four inches, the stretched and thinned-out fascia between them being cribriform, and having five or six large masses of fibroid omentum projecting through its meshes, all of them being densely adherent; at the point of bulging above mentioned a knuckle of bowel presented, and this could not be reduced. The abdomen was opened just below the umbilicus, and by inserting two fingers I was able to free the omentum, of which I removed a considerable portion, and reduce the bowel; I then excised the whole of the intermuscular sheet of expanded and cribriform peritoneum and fascia, only retaining as much of the former as was normal in appearance.

The edges of the peritoneum could barely be made to meet owing to the tension, the suture repeatedly tearing out, and the same difficulty was met with in the muscular wall. I

* *The Annals of Surgery*, 1903.

next stripped up the edges of the peritoneum from the overlying tissues sufficiently to allow of the introduction of the margins of the filigree on each side, and placing it upon the peritoneum, fixed it lightly in position with two very fine catgut sutures passed round the central stem of the filigree and through the peritoneal junction. The muscles, which, as above stated, could barely be brought together, were then approximated by a form of removable deep suture with which I have been for some time experimenting, and which I have elsewhere described,* five stitches in all being introduced. The scar tissue in the skin was then removed, and the wound closed in the usual manner.

The deep sutures were removed at the end of a week and the superficial at the end of ten days, the patient being kept in a firm abdominal binder.

The subsequent history is uneventful; she was upon the couch on the fourteenth, and left the hospital on the twenty-first day, having been perfectly comfortable, and having felt no inconvenience from the presence of the filigree. Her frequency of micturition had completely disappeared, and the bowels were acting without difficulty or discomfort.

It is of course as yet much too early to claim this case as a cure, but, seeing the excellent results obtained by the American surgeons in this branch of operative surgery, it is, I think, reasonable to suppose that, given a primary union of the wound and an uncomplicated recovery, such an event may be looked upon as a practical certainty.

As the method has been so recently brought before the profession, it would be out of place for me to do more than report this case and show the subject of the operation, but I believe that it promises, if properly conducted, to place within our grasp many cases of hernia of all varieties which have hitherto been considered to be outside the pale of practicable surgery.

The chief points at which the operation aims are the saving of time, the discounting of tension between muscles when they *can* be brought together, and the presence of an unavoidable gap when they *cannot*, by the insertion of a light metal meshwork, which is rapidly incorporated in the living tissues; and lastly, the complete and permanent cure of a condition which has too often been seen to recur after treatment by less perfect methods.

* *Lancet*, April 23, 1904.

Should it be found impossible to get the edges of the peritoneum to come together, the difficulty could easily be met by the use of a large omental graft lightly sutured to the edges of the gap, than which it should be rather larger, so as to overlap to the extent of about a quarter of an inch all round; or if there should be danger of the graft dying on account of its size the omentum might be utilised to fill in the gap; but in this case the filigree should be rather more accurately sutured to the peritoneum.

In conclusion, I might point out that the above method has been very severely tested, and its efficiency demonstrated by Bartlett, who reports the success of a case in which the portion of abdominal wall involved consisted ultimately of nothing more than peritoneum, filigree, and skin, the muscles refusing to come together. The case did well, and the patient remains sound two years after the operation.

An operation which seems to promise relief to a host of sufferers from a condition which in the majority of cases cripples their daily work and in many renders their lives a burden to them, seems to me to call for a more extensive trial and wider publicity at the hands of those surgeons who are in the position to submit such cases to this method.

X.—*Congenital Narrowness of the Pyloric Orifice: a Cause of Chronic Gastric Disease in the Adult; illustrated by seven cases successfully treated by operation.*

By A. Ernest Maylard, M.B., B.S.Lond. *Read December* 11, 1903.

IN operating upon various cases of chronic gastric derangement I have met with a condition of the pyloric orifice that seemed to me not only sufficient to explain the symptoms which existed, but to suggest that the condition itself was probably of congenital origin.

I shall possibly best introduce the subject by first narrating the history of the cases upon which the subsequent observations are based. It might be reasonably contended that the fullest details of every case should be given in order to eliminate all causes that might be considered, were they present, to offer an explanation other than that which I shall venture to give. But I am compelled, in order to bring my contribution within reasonable limits, to introduce only such salient features in each case as appear to me fairly to support the views I hold. The cases are seven in number.

Case 1.—Mrs. A. B., æt. 31. Gastric symptoms commenced when twenty-four years old; were of a simple dyspeptic character. Later the symptoms were those of chronic gastric catarrh; much mucus present both in vomit and in motions; much emaciation, and relief only obtained by lavage; food generally caused pain. Dilatation occasionally present. No history of hæmorrhage. Patient in good station of life, and unable to account for the early appearance of her symptoms.

Operation on May 14, 1902, in private home. Direct external examination of stomach negative. Internal examination: Mucous membrane livid and coated with much mucus. Pyloric orifice with rather tight ring admitting index finger with difficulty. Posterior gastro-jejunostomy performed. Eighteen months after patient in excellent health, in every way a different woman.

Case 2.—Miss B. C., æt. 46. Gastric symptoms as long as she can remember, chief symptom being occasional attacks of vomiting after food not accompanied with pain, but food causes a sense of weight in the epigastrium. Dilatation takes place if careful attention is not paid to diet and lavage practised. Patient much emaciated and in general feeble health. No history of hæmorrhage, nor can any reason be assigned for the commencement of her early symptom. In a comfortable position in life.

Operation on June 5, 1902, in private home. Direct external examination of stomach and pylorus negative; internally a uniform ring-like constriction admitting about a No. 12 urethal catheter. Posterior gastro-jejunostomy. Fifteen months after, considerable and continued improvement.

Case 3.—Miss C. D., æt. 20, one of a very healthy family. Gastric symptoms commenced when fourteen years old in the way of ill-defined indigestion—the tolerance of certain foods and not of others. Latterly pained by food and relieved by lavage. Any indiscretion in diet brought on symptoms and caused gastric dilatation. No history of hæmorrhage nor any other cause to explain why she should differ from other members of family, who were all healthy. She lived in a good station of life.

Operation on October 20, 1902, in private home. Direct external examination of stomach negative; internal examination: pyloric orifice contracted by a uniform ring-like constriction which would only admit the apex of the index finger. Posterior gastro-jejunostomy. Twelve months after in good health.

Case 4.—Miss D. E., æt. 27, one of a healthy family. Gastric symptoms as long as she can remember; a feeling of weight and general discomfort after food; no pain nor vomiting, but attention to diet and occasional lavage always gave relief. The food took, as she said, about six hours to pass out of her stomach. Dilatation marked. No history of hæmorrhage nor other cause to account for the onset of her symptoms. In very good position in life.

Operation on October 30, 1902, in private home. Direct external examination of stomach and pylorus negative; internal examination: pyloric orifice a uniform, narrow, tense ring which only admitted tip of index finger. Gastro-

jejunostomy performed. Twelve months after, improvement and continuing, but so far not so marked as the other cases.

CASE 5.—M. R., æt. 21. Gastric symptoms commenced when sixteen years old, and consisted of pain and vomiting an hour after food. Dieting improved her condition, but return to ordinary food brought on the attacks. Treatment never produced more than temporary improvement. No history of hæmorrhage nor other cause to account for onset of symptoms. A dressmaker by occupation.

Operation on November 7, 1902, in Victoria Infirmary. Direct external examination of stomach and pylorus negative; internal examination: pyloric orifice uniformly contracted, admitting only the apex of the index finger. Posterior gastro-jejunostomy performed. Twelve months after, never better in her life and back to her work.

CASE 6.—Miss E. F., æt. 27. Gastric symptoms commenced a year and a half ago, mostly with pain after food. She found that by limiting herself to milk and fluid diet she was freed from any discomfort, but any attempt at a return to ordinary solid diet caused a recrudescence of her symptoms. She always noticed that small quantities agreed with her much better than large. Dilatation was occasionally present. No history of hæmorrhage nor of other cause to explain onset of symptoms. Was of good complexion, and fairly well nourished. In good social position.

Operation on November 27, 1902, in private home. Direct external examination of stomach and pylorus negative; internal examination: pyloric orifice uniformly contracted to a narrow ring which hardly admitted the apex of the index finger. Posterior gastro-jejunostomy performed. Twelve months after in excellent health.

CASE 7.—S. K., æt. 27. Gastric symptoms commenced nine years ago, and were mostly of a simple dyspeptic character; pain and vomiting sometimes present. Can only take milk and soups; solids, as butcher's meat, etc., caused pain and were vomited. Test breakfast showed free hydrochloric acid, and inflation marked distension. She is of a fresh colour and fairly well nourished. No history of hæmorrhage nor other cause to account for onset of symptoms. Is a shop assistant by trade.

Operation on September 15, 1903, in Victoria Infirmary. Direct external examination of stomach and pylorus negative; internal examination revealed a tight and uniformly ring-like constriction of the pyloric orifice which the index finger could not enter without force. No thickening or irregularity present to suggest old ulceration. Posterior gastro-jejunostomy performed. Two months after was in a convalescent home showing marked signs of improvement.

(In operating upon these and in most of my other gastric cases I have to acknowledge the kind and valued assistance of my friend Dr. J. Grant Andrew.)

The first point to which I should like to draw attention is the particular character of the constricted orifice met with in these cases; and before doing so I ought perhaps to state what may be considered the normal condition of the orifice as met with by the surgeon on the operating table. Under complete anæsthesia the gastric parietes are more or less flaccid; the pylorus externally presents a line of somewhat deeper colour than the neighbouring parts; only the faintest constriction is visible, the duodenum often passing so imperceptibly into the stomach that it is only by the tactile sensation offered by the sphincter that the exact seat of the pylorus is detected. There is no constancy in the amount of induration, if I may so express it, which the pylorus presents; a fact which seems to suggest that though the patency of the canal may be quite normal there may be great differences in the developmental condition of the sphincter—differences possibly dependent upon the same physical causes, which may naturally affect other parts of the body. I have little doubt that this variation has led to the difficulty experienced by some of determining whether the greater thickness met with in one case as compared with another was or was not due to some undue hypertrophic or inflammatory cause. I am, however, convinced that this variation is quite normal, and may exist within considerable limits. Regarding the calibre of the pyloric orifice, I have always found that while the index finger passes easily, it has conveyed to it the sense of a uniform, narrow, elastic ring, which feebly embraces, and seems to roll over the finger as it is gently pushed onwards. I should consider from 12 to 15 mm. as the normal calibre of the canal during life and under relaxation. If you look at a section of the pylorus, such, for instance, as is given in Quain's *Anatomy*, by Allen Thomson, a sensation such as that above described is what

might be reasonably expected. A uniform ring-like projection of mucous membrane is seen, containing within its folds of reduplication circular bands of muscle-fibre.

When in my earlier cases I first met with the abnormally narrowed condition of the canal, I was inclined to believe that if not due to chronic spasm, it was the direct result of the introduction of the finger into the pylorus; that such a solid substance as the finger within the stomach cavity was certainly likely to stimulate contraction of the pylorus, whose very function is to resist the passage of such indigestible objects as my finger presented. However, I had on one occasion when operating a very striking illustration of what both the stomach and pylorus are like under contraction. I had the stomach partly withdrawn from the abdomen with the pylorus in view; the patient seemed to suddenly come out of the anæsthetic, when an almost violent contraction of the gastric parietes took place, causing a little of the clear fluid within the stomach to be forcibly spurted out. Immediately there followed contraction of the pylorus, which assumed the appearance of a rigid structure about two inches in length and about the circumference of the ring finger. Pressing the anæsthetic soon relaxed the parts, and it was under this relaxed state that I felt a narrow uniform ring-like constriction at the pyloric orifice incapable of admitting the apex of the index finger.

It was the information gained in the observation of this particular case that led me first to doubt that these narrowed orifices were spasmodic in character; rather that they owed their existence more to some abnormality in development than to any acquired cause.

As to the nature of this abnormality, I am inclined to regard it as due to an excess of reduplication of the pyloric fold whereby the valve width is increased, but the orifice correspondingly diminished; that it is therefore purely anatomical and congenital in its origin. Such a definition entirely fits in with the facts revealed in the various cases above narrated. For the obstruction was always perfectly uniform, and simply gave the impression that it was abnormally small, and the smaller it was the greater the resistance it offered to the introduction and passage of the finger. Further it may be noted that resistance was in no sense like that of non-giving cicatricial tissue. That, as is well known, rarely gives way, except with laceration, while in most of these cases, with the exception possibly of the most extreme, the

ring gradually gives like an elastic band over the advancing finger. If I have been right in the construction which I have ventured to put forward regarding the nature of this obstruction, then it is possible to conceive how we may have solely as the result of development any calibre of the pyloric orifice between that which we consider as normal and that which will admit only a small sized ordinary urethral catheter.

Before passing on to the more clinical aspect of the subject I ought perhaps to indicate that these cases of pyloric obstruction in the adult in no way come under the category of that form of obstruction occasionally met with in earliest infancy. The so-called "congenital stenosis" of that period is of the nature of a very definite thickening of the pyloric region, and so quite distinct from the condition at present under discussion. While much has been written about this form of obstruction at the earliest period of life, very little appears to be mentioned of the particular kind specially referred to here.

I should say, before proceeding further, that although ignorant of the fact when I first met with the condition that I have just described, subsequent investigation into the subject has brought to my notice the description of this same appearance of the parts by others. Landerer, quoted by Maier (Virchow's *Archiv*, Bd. 102, p. 413), seems to have been the first to draw attention to this simple narrowing of the pylorus unassociated with any marked thickening or other changes connected with the part. Maier discusses this same congenital abnormality, and also indicates very clearly other appearances equally of a congenital origin. Maier's cases numbered twenty-one, and were *post-mortems* upon patients who had died mostly from other causes than those connected with the gastric condition. In some a definite history of stomach trouble was known to exist during life. While Maier's paper deals essentially with the anatomical and pathological conditions, it is also intended to indicate the clinical symptoms which may be present during life, and to suggest that due regard be had to their possible significance in this particular connection. For some years therefore the possibility of chronic gastric disturbance in the adult, dependent upon an abnormal narrowing of the pylorus, has been recognised; but it is only comparatively recently since surgery has attacked the stomach during life that the cause and its effect have come to be more exactly noted and still further treated. The subject is briefly referred to by Mayo Robson and

Moynihan in their work on *Diseases of the Stomach,* a very typical case illustrative of the condition being described. The patient was a male, æt. 24, who had suffered from indigestion for five years, which had commenced gradually and painlessly. When operated upon his symptoms were typically those of obstruction at the pylorus, and it was for this that he was treated. But the peculiarly simple and uniform nature of the obstruction—admitting only with difficulty the little finger—seems to have led the authors to regard this case as one of congenital narrowing of the pyloric orifice.

The simplest way, it seems to me, of considering the clinical aspect of the subject is to view the matter from the point of view of an obstruction at the pylorus, for the symptoms which arise from this must depend not only upon the calibre of this orifice—whether it is only slightly contracted or very markedly so,—but upon the very build and constitution of the patient. Given the same amount of abnormal development of the pyloric valve in two persons, there may be the utmost difference as to the *time* of appearance of the earliest symptoms and their special *character* and *severity*. The stomach of a well-developed, constitutionally healthy patient would probably overcome the obstruction and be free from symptoms to a much later period in life than one not so physically robust, and then when symptoms did appear in each case they might be totally distinct. I merely mention these matters in a general sort of way to show how extremely difficult must be the question of diagnosis.

Diagnosis.—In reviewing the cases I have briefly narrated there are not two that can be said to have presented symptoms of any marked similarity either in the initial or the later stages of the disease. It is no doubt due to this variableness of the symptoms that has served to mark the true cause of them. As an illustration of this I may instance the first of my cases, that of Mrs. A. B. She was a patient of Dr. Alexander Shiels, of Glasgow, who asked me to see her with him in consultation. Her symptoms were solely those of chronic gastric catarrh, from what cause it was not possible to ascertain. The amount of mucus discharged from the stomach was at times so large that it clogged the tube used for gastric lavage. Nothing but the very simplest and most meagre diet could the stomach stand. As seen at this time she was in a wretched state of health, and, although in a position to have all that means could supply, no permanent improvement had ever been attained by treatment.

We discussed the case very fully, and I must own to a sense of reluctance at the time either to propose or accede to operation. Would the performance of a gastro-jejunostomy give the stomach rest sufficient to enable it to recover from its chronically inflamed condition? Dr. Shiels seemed settled in his own mind that it was the right thing to do; his opinion being based on the success which he had seen follow operative treatment of a similar condition. Strange, therefore, as it may appear to some, the physician and not the surgeon was the one who advised operation. I accordingly performed a gastro-jejunostomy. Improvement was not immediate, but at the end of about six months progress, which had been slow, became rapid, and, without going into further details, this lady, at the end of eighteen months, was almost in what one might term robust health. The chronic catarrh in this case was evidently the result of many years of irritation, dependent upon the detention of food in the stomach by the narrowed pylorus.

The symptom of dilatation is a very variable one, sometimes present, sometimes not. What is usually found is that so long as the stomach is systematically washed out and only fluids and easily digested substances taken, no dilatation takes place; but on any liberty in diet or relaxation of treatment, dilatation becomes manifest.

A sense of weight in the epigastrium is often a striking symptom after food, and in some instances no relief was obtained until the contents of the stomach was either artificially or naturally removed. In one case the patient said her food usually took about six hours to digest.

There is nothing really pathognomonic about these symptoms, but the most suggestive I would consider the following:

1. The existence of obstinate gastric symptoms during young adult life, not to be accounted for by any of the usually recognised causes, functional or organic. Often the patients are in a good social position where neither excess nor deficiency in the necessities of life exist, and often, too, the sufferer is one only of a family otherwise healthy in all its branches.

2. The patients are mostly women under the normal standard both in stature and build. It is only somewhat natural to suppose that this is likely to be so, because an amount of development of the fold which in a viscus of naturally large size might not be sufficient to produce obstruction would

certainly do so in one of less dimensions. My cases were all women of comparatively small build, and on account of the usually smaller stature of the female as compared with the male, we may reasonably suppose that the former are more likely to suffer from any undue narrowing of the pyloric orifice than the latter.

3. Another feature of diagnostic significance is the great improvement it is always possible to effect by dieting, but the certainty with which any return to a normal state of living will call forth a renewal of the symptoms. This was most strikingly borne out in my cases.

As to the question of—

Treatment.—As has just been stated, it is possible to greatly improve the patient by attention to all those means usually employed for the same symptoms arising from other causes. I think it must be that owing to the improvement it is thus possible to effect, many men have been led into the erroneous belief that a cure has been attained where really nothing more than temporary relief has resulted. Dissatisfied after a time in not being permanently cured, the patient seeks advice elsewhere, and so leaves his or her original attendant in the erroneous position of believing he has effected a cure. Certain it is that some of my patients had seen as many as half-a-dozen separate medical men; and, as I personally know, some of these gentlemen have been indignant at hearing the patient has been operated upon for symptoms which they considered perfectly curable by the ordinary medicinal measures.

Operation is of course the only means of cure. It is not absolutely necessary in all cases, as a patient may by careful attention to diet doubtlessly live for years, and eventually die —as they did in some of Maier's recorded cases—of diseases quite unconnected with the stomach trouble. In nearly every case, however, it must be more or less an invalid existence.

Of the three operations which may be performed—pyloroplasty, pylorodiosis, and gastro-jejunostomy,—I have little hesitation in saying that the last is the proper one to adopt. It was successfully employed in my seven cases. Relief may be more or less immediate, but often it takes months to effect a cure. Where the stomach has been deranged for years careful treatment must be carried out for some time after the operation. So important and so frequently executed is this operation that I should like just to add a few remarks with regard to it. What is frequently and quite properly asked is, "You may perform your operation quite successfully and

relieve the symptoms, but what about the new relationships established—are they of themselves ever likely to cause trouble?" I say that it is quite a proper question to ask, because unless we can honestly feel that the artificial and unnatural connections we are establishing can of themselves in no way interfere with the future welfare of our patients, we ought probably to limit our practice to cases of absolute necessity and not employ it where the question is one merely of expediency. It would take far too much time to discuss the many points in connection with the performance of this operation, but after trying many methods and variations of detail, all aimed at procuring the most perfect immediate and remote ends, I have come to regard the following as the best. It is based solely on the attempt to leave the parts after operation as much as possible in their normal anatomical relation.

An oblique incision is made through the skin, commencing about one inch below the right costal margin and one inch to the right of the middle line, and extending for from three to four inches across the middle line downwards and outwards at a distance of about an inch from the left costal margin. By this incision the right rectus is divided for about half an inch and the left for two or three inches. The pylorus is exposed, and an easy examination of the stomach afforded. The division of the rectus muscle I consider of no importance; what, however, I do think necessary towards the attainment of a perfect cicatrix is the union of the anterior and posterior layers of the rectus sheath by separate lines of suture. I have not failed once in obtaining a perfectly sound and non-giving cicatrix by this method.

The posterior operation by simple suture is the one, with few exceptions, practised. After withdrawing and turning upwards the stomach and transverse colon, the mesocolon is teased through and its edges secured by three or four stitches to the posterior wall of the stomach, which is made to present. The jejunum is picked up, closed to the duodeno-jejunal bend, applied to the stomach, and stitched to it for about three inches, the direction being such that when the stomach is replaced it and the united bowel still occupy much the same relation as before union. The opening of communication about one and a half inches long is made close to the great curvature, so that it comes to occupy the most dependent part of the viscus, and has also an inch or two of stitched surfaces above it. Thus it will be seen that no "angulation" of the

gut is possible; there is no long loop of proximal bowel to become "water-logged" and possibly cause trouble in the remote future; there is no need for an entero-enterostomy, and as the bile and pancreatic juices very soon mix with the gastric juice there is little fear of the formation of peptic ulcers in the distal limb. The ejection of bile into the stomach never takes place, because the method of attachment adopted causes it and the pancreatic juice to be shot past the opening into the more readily accessible channel below. The method, practised now for more than a year, has been followed by an entire absence of all untoward symptoms, and I believe ensures against any complications in the future.

In conclusion, let me sum up my remarks by saying—

1. That there exists a considerable class of patients in young adult life who owe their chronic gastric trouble to a congenital narrowness of the pyloric orifice.

2. That this "narrowness" is due in many cases to an undue development of the pyloric valve lessening the calibre of the orifice to anything between the normal of 12 to 15 mm. and 2 or 3 mm.

3. That the proper treatment is gastro-jejunostomy performed with due regard to the normal disposition of the parts after operation.

XI.—*One Hundred Cases of Gastro-enterostomy for Simple Ulcer of the Stomach and Duodenum.*

By B. G. A. Moynihan, M.S., F.R.C.S. *Read December 11, 1903.*

During the last few years I have operated upon over 160 patients for diseases of the stomach and duodenum. The cases include examples of malignant disease treated by gastrectomy, partial or complete, or by gastro-enterostomy, of hour-glass stomach, of perforation of ulcers, and of chronic ulcers of the stomach which were in need of surgical treatment for one reason or another.

Up to October 1, 1903, I had performed gastro-enterostomy for ulcer of the stomach or of the duodenum exactly 100 times. In the following paper I have attempted an analysis of this series of cases.

It will be readily admitted that all the records in a long series of such cases are not of equal value. The experience which ripens with each successive case is not at the bidding of an operator at the beginning of his career. The earlier records are therefore imperfect; many observations which would now be made were then omitted, as the need for them was not appreciated.

The total number of operations was 100, the mortality two. Eighty-five cases were operated upon for chronic ulcer with intractable dyspepsia, or dilated stomach, with one death. Fifteen cases were operated upon for profuse and recurring hæmorrhage, with one death.

There were fifty-six females and forty-four males. The youngest patient, a female, was aged seventeen; the oldest, a male and a female, were each sixty-two. The average age was thirty-five.

In ten cases the induration around a chronic ulcer was so marked that I have recorded the presence of a "tumour."

In two cases, both females, the patients said they had suffered from stomach troubles "all their lives," and that vomiting was present in early infancy. In the first there was pyloric thickening with complex adhesions, in the second I have noted that the pylorus was like a "thick and rigid

tube"; in this case there were no adhesions. It is possible that in both a congenital malformation of the pylorus was present.

In fifty-eight cases the presence of a single ulcer, or of the scar of a single ulcer, was noted. In twenty cases there were two ulcers, in four cases there were three ulcers, and in seven the ulcers are described as being multiple. This statement needs criticising, for I found as my experience grew that on more careful and more extended examination of the stomach on both anterior and posterior surfaces, a second or a third ulcer was frequently found that formerly would have been overlooked. In the earlier cases, five in number, when the anterior operation of Wölfler was performed the posterior surface of the stomach was not examined. In the last fifty operations more ulcers than one were found in the stomach on twenty-two occasions. Duodenal ulcer was found alone in nine cases; duodenal ulcer with one or more gastric ulcers in thirteen cases. Again, it should be said that the co-existence of duodenal and gastric ulcers was more often noticed in the latter cases. The great majority of the ulcers were in the pyloric third of the stomach. It was rare to notice one within the cardiac third. Adhesions which were noticed in twenty-one cases varied greatly in extent and in complexity. In two cases there was a history of the perforation of an ulcer, so diagnosed by the medical man in attendance; in both of these the whole stomach was densely adherent, and it was with difficulty that so much of the stomach was cleared as to allow of a gastro-enterostomy being performed.

Fifteen cases were operated upon for hæmorrhage. Of these one patient, æt. 62, died. The only other fatal case in this series was in a man æt. 28. This patient died of a strangulated internal hernia. All the small intestine, with the exception of about fifteen inches of the lowest ileum, had passed through the opening in the transverse mesocolon into the lesser peritoneal cavity, and had become strangled by the margins of the opening. In performing the operation upon this case I was conscious of having made the tear in the transverse mesocolon larger than usual.

In several of the cases the patients complained of little more than severe intractable dyspepsia. It was quite an ordinary history for a patient to say that his or her trouble came on "in attacks;" that in the intervals there was comparative comfort, though solid food could not be freely taken;

and that relief was sought because the attacks were becoming more serious and the intervals were shorter. Vomiting was often inconspicuous as a symptom, and in some cases the patient said that she had never vomited. On inquiry it was found that such a patient had been compelled, owing to pain and the sense of impending sickness, to curtail the diet, to omit first one and then another article of food until little but milk or Benger's food was taken. Vomiting was not present because it was never elicited. A patient who had vomited frequently and in abundance would often be entirely free from any sickness while resting under observation in hospital. In all, vomiting had been observed as a repeated occurrence in forty-four cases.

Hæmatemesis had been recognised, apart from those cases operated upon because of the hæmorrhage, in twenty-one cases. Melæna was observed alone in three cases, in all of which a duodenal ulcer was found. Hæmatemesis and melæna were observed together in six cases; in four of these gastric ulcers alone were found, in two both duodenal and gastric.

Pain was the most constant and the most distressing symptom. It appeared sometimes before a meal was finished, sometimes half an hour or an hour afterwards. A "hunger pain," a pain eased by the taking of food and appearing two to four hours after the meal, was noticed in cases both of gastric and duodenal ulcer, and was always associated with hyperchlorhydria.

Hæmorrhage was the immediate and determining cause of operation in fifteen cases. In all of these there had been symptoms of stomach troubles for a shorter or longer time before the onset of the bleeding. I have elsewhere discussed the various forms of hæmatemesis dependent upon gastric ulcer, and I need only say here that the points which determine one to treat such a case surgically are the recurrence of the hæmorrhage and its quantity. Several of these patients were in a desperate condition. In five of them saline intravenous infusion was employed at the time of the operation; from three to five pints were given according to the patient's needs. The hæmoglobin percentage was 18, 22, 25, 28, and 33 in five of the most serious cases; in the rest it was above this point, or was not recorded. In all these patients gastro-enterostomy alone, without the excision of the ulcer, was performed; in not one of them was there any trace of renewed bleeding after the operation. There is without doubt a very remarkable tendency to spontaneous cessation in gas-

tric hæmorrhage. In hæmorrhage from what is known as an "acute" ulcer one of the most assured events is the spontaneous cessation of the bleeding. Though the hæmorrhage may be copious and most alarming, it is rarely fatal. In chronic ulcer the same tendency is noticed, and, indeed, in some cases in which an operation has been performed the ulcer has been found and the bleeding vessel has been seen plugged with a firm clot. The factor which determines a recurrence of the hæmorrhage is, according to my observation, distension of the stomach. In one case I had to puncture the stomach to let out a large volume of gas before I could manipulate it and secure it with a clamp as a preliminary step in the performance of gastro-enterostomy. In all the cases upon which I have operated this distension of the viscus has been observed, and in some it has been phenomenal. It is, I consider, the stretching of the ulcer caused by the distension of the stomach which is chiefly responsible for the repetition of the hæmorrhage. In one case not in this series I have excised the ulcer. The question as to what is the best method of treatment in hæmatemeses treated surgically has been much discussed, and the question remains still unanswered. There are some who advocate the opening of the stomach and the search for the ulcer. There are others who, ignoring the ulcer, hasten to perform gastro-enterostomy in the belief that this will secure the spontaneous arrest of the bleeding. My own feeling is that if the ulcer is readily found, it may be excised, but in any case gastro-enterostomy should be performed as well. For the ulcer may be difficult or impossible to recognise; it may not be single; and if, therefore, one ulcer is excised another may be the source of the hæmorrhage, and the hæmorrhage continuing, may prove fatal. Two cases of this kind at least are recorded. That gastro-enterostomy will secure, or at least go far to securing, the arrest of the bleeding (by emptying the stomach, as I think) I submit that my record of cases undoubtedly shows. Whether, therefore, the ulcer be excised or not, a gastro-enterostomy ought certainly to be performed.

In three patients regurgitant vomiting was observed; in one of the patients the vomiting ceased on the tenth day after the stomach had been washed out once, in another the painless vomiting of bile continued for nearly a year, in the third case I was dissatisfied with the appearance of the anastomosis as soon as my suture was completed. There had been, about two years before the operation, a perforation of an ulcer in

the stomach, and there were the utmost complexity of adhesions all round the stomach, which greatly distorted its outline. There appeared to be a kinking at the point of junction of the jejunum with the stomach, and I was tempted to perform entero-anastomosis then and there. I did not do so, however, but when vomiting of bile commenced, as I feared it would, directly the patient came round from the anæsthetic, I reopened the abdomen and joined the afferent and efferent loops of the jejunum. 132 ounces of bile-stained fluid were vomited within fifty-four hours of the original operation; after the second operation there was no vomiting. The causes of the "vicious circle" or "regurgitant vomiting" have been difficult to discover. It was supposed that the presence of bile and pancreatic juice in the stomach excited the act of vomiting, but a case of my own in which, owing to a complete rupture of the bowel at the duodeno-jejunal flexure, I had to close the duodenal end and implant the jejunal into the stomach proves without question that these fluids are harmless. For in this case all the bile and all the pancreatic juice passed into the stomach, yet digestion proceeded as before, and the boy ate well, enjoyed perfect comfort, and gained in weight. The correct explanation of the cause of regurgitant vomiting in some of the cases was first given by Mayo, of Rochester, Minnesota. He showed that if the anastomosis were made at some distance from the greater curvature on either the anterior or the posterior surface, a pool of fluid collected below the opening, and there, being stagnant, excited the act of vomiting. He urged that the anastomosis should always be made as close to the greater curvature as possible. Since making sure in all my operations that the lower end of the opening was at the greater curvature, I have never seen the vomiting of bile in any case. There are cases, however, to which this explanation does not apply. In these there is an acute kink at the point of anastomosis, and the symptoms are those of an intestinal obstruction high in the small intestine. In such circumstances the bile and pancreatic juice regurgitate into the stomach through the pylorus.

Gastric tetany has been observed in greater or less severity in five cases. In three it was slight and affected only the hands and forearms and the calf-muscles. In two it affected these muscles, the neck muscles, and the abdominal muscles, and in both the patients experienced the utmost agony, one of them repeatedly expressing a hope that she might die to be spared future attacks. In one case tetany affecting the

hands and forearms was observed in a patient on several occasions during the first few days *after* the gastro-enterostomy had been performed. This patient, who had a very dilated stomach and a markedly stenosed and thickened pylorus, told me at the time that she had never previously suffered from such attacks; but within the last month she has called to tell me that a relative with whom she then lived had reminded her that she had suffered from cramps of the hands with the typical "obstetric position" ten years before. Whatever the cause of gastric tetany may prove to be, there can be no doubt that the disease in its severer forms is a complication of old-standing dilatation of the stomach that can be prevented by the earlier performance in these cases of gastro-enterostomy.

Chest complications were seen in three cases; in one there was a sharp attack of pneumonia, in two there was acute bronchitis. In one case, not in this series, of malignant disease of the stomach and in one case of hour-glass stomach acute pneumonia has followed the operation. The symptoms have begun about the end of the second or on the third day, and the acute stage has lasted about one week. Many theories have been suggested to explain the frequency of pneumonia after operations in the upper part of the abdomen. It has been attributed to exposure, to embolism, to the fixing of the upper abdomen by the patient in the unconscious effort to keep the wound at rest, and to the anæsthetic. Much has been written about this subject, but where there are many theories there is little knowledge. My own belief is that the pneumonia is septic in origin, and is due in most cases to the inhalation of putrid material from carious or unclean teeth. When a patient who is to have gastro-enterostomy performed comes to the hospital or to the nursing home, he or she is supplied, as a routine, with a toothbrush and a bottle of antiseptic mouthwash, and instructions are given that the teeth are to be brushed freely every two hours. In addition, all food given is liquid and is sterilised. If the patient is admitted on Monday at noon, for example, five grains of calomel are given on Monday evening, a saline aperient on Tuesday morning, and an enema on Tuesday night. The stomach is washed out on Monday evening or Tuesday morning, as is convenient, the washing being continued until the fluid returns quite clear, and a second washing takes place about an hour before the operation. The operation is done on Wednesday morning. The importance of the cleansing of the mouth and

of the sterilising of the food was conveyed to me by the work of my friend Dr. Harvey Cushing, of Baltimore.

After the operation the patient, when in bed, is propped up in the semi-recumbent position by five or six pillows or by the bed-rest. If the patient is very ill and in urgent need of fluid nourishment, water, milk, or other fluid is given at once in small doses quickly increased. Saline enemata of five to six ounces, with or without brandy, are given every four hours, and a simple aperient enema is given every twenty-four hours. The toilette of the mouth is still carefully supervised.

The anterior operation of Wölfler was performed in five cases, the posterior of von Hacker in ninety-four cases, Roux's operation in one case. My choice of this last method was due to the fact that, owing to the perforation of a duodenal ulcer for which I had operated several months before, there were many adhesions crippling the stomach and warping its outline. In a previous almost exactly similar case already mentioned, I had been compelled to reopen the abdomen and perform an entero-anastomosis. In any case of this kind in future I should adopt Roux's procedure. It is ideally perfect as a method of gastro-enterostomy. It reproduces almost exactly the normal conditions. Its sole disadvantage is that the time necessarily expended in the operation is at least ten minutes longer than in an ordinary posterior gastro-enterostomy. I am so satisfied, however, with the results of the posterior operation and with the perfectly uneventful course of the great majority of the cases that there does not seem to me to be any need for the routine adoption of Roux's method.

In ninety-two of the cases the result of the operation has been from the first as satisfactory as could be wished. Appetite has soon returned, and food has been taken in any quantity with relish. All these patients have gained in weight, the gain varying in amount from seven pounds to four and a half stones. In the remaining six cases the after-history has not been so good. In every one of these hyperchlorhydria was pronounced before the operation, and has proved a source of pain and inconvenience afterwards. Of the six patients, three have improved greatly under medical treatment, continued for three to five months, and are now quite well; one is almost well, and two are still under treatment. The last three have all been operated upon within the past eight months. It is possible that in some of these cases, owing to the excess of free hydrochloric acid, the mucous membrane in the distal limb of the jejunum has been digested, forming a peptic ulcer,

and that this has caused some of the symptoms from which the patient has suffered. The six cases are the only ones that have not been completely successful. They have shown me that when hyperchlorhydria is present as a prominent and enduring symptom some preliminary treatment by diet and alkalies may be desirable.

In two cases the condition was diagnosed before operation as malignant, and the appearances found at the operation were taken as confirming the diagnosis. Yet malignancy is disproved by the fact that both patients have gained over three stones in weight, and remain perfectly well, though the operations were done in June, 1900, and in January, 1901. In one case not included in this series the induration at and near the pylorus was supposed to be simple in character, but the subsequent course of the case has shown that the condition was malignant. This may have been an error of diagnosis, or the case may be an example of "ulcus carcinomatosum," of the implantation of cancer upon the edge of a chronic ulcer. This case occurred early in my experience. I do not think that the differentiation between simple and malignant conditions in the stomach causes me any difficulty now.

In three cases not included in this list I performed pyloroplasty. The last operation was done in January, 1901. I do not intend to perform this operation in any subsequent case. Gastro-enterostomy is in my judgement a much more satisfactory method of dealing with any condition of pyloric stenosis. (This criticism does not apply to Finney's operation of gastro-duodenostomy, or pyloroplasty.) The operation of gastro-enterostomy is so safe and its results are so good that I cannot doubt that it is the most desirable operation in all cases of chronic gastric ulcer. Its success depends in no small measure upon care in the preparation of the patient, speed in operating, the choice of a method which is simple and which does not need a long exposure of viscera, and upon many details in after-treatment. Excision of an ulcer is perhaps desirable in some special instances, but the main indication to be fulfilled is drainage of the stomach; and to secure this gastro-enterostomy should always be performed. In many cases in this series the patients were extremely ill, wasted and enfeebled to the last degree, and it was only by the exercise of the greatest care that the operations proved successful. There are at least a dozen cases that one would not have been surprised to lose. Now that the mortality is reduced to so

small a figure as 2 per cent., the surgeon may not unreasonably expect that from being a last and sometimes desperate resource, gastro-enterostomy may be looked upon as a method of treatment worthy of consideration in a much earlier stage of chronic ulcer of the stomach.

XII.—*A Case of Pneumococcal Peritonitis; laparotomy; left empyema; thoracentesis; recovery.* By Sir Dyce Duckworth, M.D., LL.D., and Howard Marsh, M.A., F.R.C.S. *Read January* 8, 1904.

Miss G. W., æt. 27, a fair-haired, somewhat anæmic woman, was taken ill on February 26, 1903, with pains generally over the body, headache, and shivering. No temperature was taken this day. The catamenia were present, and the bowels were confined on this and the next day.

On the evening of February 27 the temperature rose to 104·2°, and she was restless and sleepless, but free from pain. Had four hours' sleep after a sleeping draught. On the morning of the 28th the temperature had fallen to 99·2°; felt better. In the evening, however, there was a rise in the temperature, and severe pain came on in the abdomen, not localised, and not relieved by hot fomentations. A patch of herpes appeared at the left angle of the mouth. Passed a bad night in spite of a sleeping draught. Complaint was now made of pain in epigastrium after swallowing any liquid. Was sick twice during the night. Vomit bilious, with curd and a few streaks of blood. Several loose stools (not characteristic) as a result of aperients.

March 1.—To-day the pain is still present all over the abdomen. The most tender parts are the right iliac fossa and the epigastric region. Pressure makes the pain worse. There is no pain on micturition or defæcation. Examination of chest and heart: nothing abnormal found. Abdomen is flat, not distended. Resonant all over. Does not move much on respiration. Some abdominal pain on deep respiration. On palpation both recti equally resistant. Spleen not felt. In right iliac region a cord-like edge (about half-inch in diameter) can be felt running upwards to the outer side of the right rectus. It can be rolled slightly under the fingers. No such swelling is felt on the left side. Nothing else abnormal found in abdomen. Liver dulness natural. Face: expression rather anxious. Eyes: conjunctivæ, slight icteric tint. Tongue: white fur on dorsum. Urine normal. Patient has been on the whole better. Abdominal pain less

intense this evening. Sick once after brandy. Temperature raised since 3 p.m. to 103·6°. Very thirsty. Widal's reaction negative. Large polynuclear leucocytosis present.

March 2.—During the night patient was very restless and wandering, and complained of abdominal pain. Her temperature rose to 103·6°. She was given one-seventh grain of morphine, after which she slept one hour. She was sick once during the night. Nothing characteristic about the vomit. Mr. Marsh and Mr. Bowlby saw her with Sir Dyce Duckworth at 1.30, and diagnosed appendicitis with some general peritonitis. (She was operated on by cutting down over the right rectus and drawing the muscle inwards.) On opening the abdomen the large intestine appeared red and inflamed, and its peritoneal surface dull. The appendix was found to be constricted at the base and dilated, and filled with mucus, above. It was ligatured and removed. Some thin turbid and dark-coloured fluid was present in the peritoneal cavity. No adhesions were seen. A tube was inserted and the wound closed round it. Her temperature fell after the operation to 100°, and she seemed a little more comfortable. During the night she was given heroin one-fifth grain, and slept for six hours. Delirious and had nightmares.

March 3.—Patient felt no better this morning, and complained chiefly of gastric pain. Abdomen unaltered. Slight discharge from tube. Examination of fluid in peritoneal cavity removed by Dr. Andrewes at time of operation shows it to be a pure culture of pneumococci; confirmed by Dr. Klein. Inoculation experiment on mouse subsequently. Mouse died of acute pneumococcal septicæmia. Patient is fed by nutrients. A little water only by mouth. Has not been sick to-day.

March 4.—Had a bad night and was delirious; heroin and morphine given. A little brandy by the mouth. Abdomen was more distended, and an asafœtida enema was given in the evening. Distension much relieved. Has been taking whey, tea, and brandy by mouth. Has not been sick. Has had a little hiccough, relieved by tea. The wound is dressed daily. There is very little discharge.

March 5.—Patient's pulse rose gradually yesterday from 120° to 140°. She had a bad, delirious night, requiring morphine and strychnine. This morning the hiccough is more troublesome, the abdomen more distended, and the pulse

quicker than it has been since the commencement of her illness. At 11 A.M. she was given 10 c.c. of No. 1 antipneumococcal serum in the flank. Her pulse had fallen twenty beats by 1.30 P.M., and she seemed slightly better. The serum No. 2 was repeated at night.

March 6.—Had a better night. Less restless, sleep more natural. Was not delirious. Temperature this morning 99·6°. Another dose of serum was given. Two hours after she seemed restless, her face was flushed, and the pulse-rate had increased to 132. There is more abdominal movement on respiration, especially in the upper part of the abdomen. The stitches were removed from the wound on the 5th; the tube having been removed on the 4th. Discharge very slight. Takes well, and has not been sick. Asafœtida enema has been found very efficient when distension is present.

March 7.—Fairly good night. Seems a little better this morning. Complains of dryness of the mouth. Abdomen is still very tender all over.

March 8.—Was given sulphonal and trional last night, but required morphine also. Slept for six hours. Abdomen moving a little better to-day. A little less tender. Pulse quite satisfactory. Bowels open naturally.

March 9.—Slept from 1 A.M. till 8.30 after morphine. Is improving slowly. Discharge is very slight from wound. Edges are drawn together with strapping. Has had no hiccough last two days. Takes very well. Nothing abnormal found in chest or heart except weak breathing left back at base.

March 12.—General condition improving. Temperature not above 100°. Sleeping better. Less abdominal pain.

March 14.—On examination of chest the note is impaired below the angle of the left scapula, and the air entry over that part of chest is deficient. There are no added sounds to be heard. Right back resonant to base. One or two crepitations heard at base. Heart's apex not displaced.

March 17.—Still a good deal of pain on left side of abdomen. There is a dull area over the left lumbar region extending to middle line of abdomen. It looks fuller on this side and is tender. Skin natural. No definite sense of fluid. Chest unaltered, expansion deficient at left base. Appetite fair. Bowels loose. Tongue clean. Patient is sleeping better.

March 20.—There is little alteration in the physical signs present in the chest and abdomen. Complained of pain in

right hip, shooting down leg. Gum-boil incised left lower jaw.

March 21.—The left pleura was explored in the post-axillary line, ninth space, and pus removed.

March 22.—Had a good night, and this evening, under chloroform, an inch of the ninth rib was removed and about twelve ounces of thick, yellowish, slightly sour-smelling pus were removed. She bore the operation and anæsthetic very well.

March 23.—A good deal of foul-smelling discharge has come away during the last twenty-four hours, and she has been dressed three times. Her temperature has been rather lower on the whole to-day, and she feels a little better. Her breathing has been rather quicker and not quite so easy.

March 25.—There is still a large quantity of discharge, but it is lighter in colour and not so foul smelling. The wound and tube are syringed with a solution of hydrogen peroxide. Appetite still good. Temperature falling. The abdomen is resonant all over, is not tender, and moves naturally. Right lung natural.

March 27.—Temperature rose last night to 101°, ? due to indiscretion in supper.

March 29.—Patient is sleeping and taking well. The discharge is less and thinner. The tube was removed to-day and re-inserted. Skin round the wound healthy.

Condition remained satisfactory during the next week. Patient slept well and took her food well. Wound painful to dress, and tube difficult to re-insert.

About April 8 temperature began to rise, and on the morning of the 12th reached 102·8°. During this time there was always difficulty with the tube owing to the closing up of the wound, the end of the tube being nipped by the upper rib; this led to insufficient drainage, with consequent retention of discharge.

April 21.—Mr. Marsh decided to enlarge the empyema wound and examine the condition of the cavity. Under chloroform a portion of the ninth rib along the upper border of the wound was cut away, and a thorough examination made in all directions with the finger. No collection was found, but many adhesions between the pleuræ, the lower margin of the lung being indurated. A large tube was then left in for drainage purposes.

Further progress was uneventful. When patient was discharged there was still a small sinus requiring daily dressing. The condition of the lung was quite satisfactory; there was

good expansion and air entry well down to within an inch of the empyema wound. A slight tendency to falling in of the left side of the chest, with dropping of that shoulder. The patient made a rather slow, but complete recovery. She was sent to Margate, and benefited much while there. Subsequently she went to the Isle of Wight. The sinus in the chest did not close till July, and the general health was completely restored by the end of that month.

Remarks by Sir Dyce Duckworth.

The patient was gravely ill for some days in March, and appeared to be losing strength rapidly. It was then that antipneumococcal serum was employed, and it is certain that improvement followed its administration—whether in consequence of it or not cannot be decidedly affirmed. Pneumococcal infection is as yet little recognised as a cause of peritonitis. When the infective nature of pneumonia was first made known in 1888, and the occasional contagious character of the disease was ascertained, it was discovered that the exciting cause of it had a wider field for its incidence and malign effects than the lungs. Various inflammatory conditions were thus traced to this pathogenic organism when alighting upon serous membranes and joints.

Pneumococcal arthritis was described by Weichselbaum in 1888, and by Dr. Cave, of Bath, in 1901.* Dr. F. Morisse wrote a thesis on the subject of pneumococcal peritonitis, recording eight cases, read before the Paris Faculty in 1892; and Dr. Bryant reported three cases in 1901, which occurred in Guy's Hospital. All proved fatal, although the abdomen was opened in two of them. Griffon reported a case in 1896 in which arthritis, endocarditis, and meningitis were found to result from this infection.† The occasional occurrence of meningitis in cases of pneumonia, which was formerly little explicable, is in all probability of pneumococcal origin. Cases of pleurisy, empyema, malignant endocarditis, pericarditis, nephritis, and several of peritonitis have been described by various German and French observers. In one of the latter, reported by M. Leroux, there were associated purulent meningitis, pleurisy, and arthritis.

The occurrence of herpes on the face in the case now recorded is noteworthy, inasmuch as this is a very rare accom-

* *Lancet*, 1901; "Septic Arthritis," by Howard Marsh, 1903, p. 10.
† *Brit. Med. Journ.*, September 21, 1901, with Bibliography.

paniment of ordinary peritonitis, though frequent enough in pneumonia. Joints infected by pneumococci present all the characters of a septic arthritis.

It was suggested about ten years ago that cases of so-called idiopathic peritonitis, or peritonitis *à frigore*, were of pneumococcal origin, and it appears probable that some of them are truly of this nature. We may therefore regard this micro-organism as a source of some of the gravest and most widely spread diseases we have to encounter. In respect to the peritoneum, the disorder may originate within the abdomen, and so be primary; or the peritonitis may result from a pneumococcal lesion elsewhere, and so be secondary, conveyed either by infected blood or by way of the lymphatic system.

NOTES FROM THE PATHOLOGICAL LABORATORY BY DR. ANDREWES.

Leucocytosis.

March 2.—35,000.
4.—21,000, entirely a polynuclear leucocytosis (polynuclears 94 per cent.).
9.—19,000, polynuclears 88 per cent.
16.—20,000, polynuclears 87 per cent.
25.—20,000.
April 1.—12,000.
16.—16,000.

March 2.—Widal's reaction negative.

Peritoneal fluid taken at operation thin, semi-purulent, containing pneumococci in pairs. Agar cultures yielded pneumococci in pure culture. Gelatine cultures remained sterile.

Animal experiment.—A mouse inoculated *sub cutem* with a drop of the peritoneal exudate died on the fifth day of pneumococcal septicæmia, with numerous capsuled diplococci in blood and spleen. A second mouse inoculated with an agar culture of the organism died in eighteen hours of pneumococcal septicæmia.

Excised appendix, at the distal end, shows old fibrosis and obliteration; at the proximal end, old fibrosis in the submucosa and recent peritonitis on the serous surface; but there is no evidence of *recent* inflammation in the thickness of the wall.

March 5.—Agar cultures from abdominal drainage-tube yielded very few colonies of pneumococci; they were probably mostly dead by this time. The chief organism growing in the cultures was a slowly liquefying, white staphylococcus—contamination of wound from the skin.

March 23.—*Empyema pus* contains microscopically a number of diplococci like pneumococci; no cultures made.

Remarks by Mr. Howard Marsh.

From the point of view of surgical diagnosis this case seemed worthy of attention. Pneumococcic peritonitis, though not a few examples of it have been recorded, is yet somewhat of a clinical novelty, and I had not before met with it. There was nothing in the case which obviously challenged the view that the illness was due to appendicitis. Certainly the occurrence of a rigor early in the attack is unusual in appendicitis, yet it has been met with; while the presence of a more marked degree of swelling, tenderness, and rigidity in the right iliac fossa than in the other parts of the abdomen seemed strongly to suggest that the appendix was at fault. On looking back on the case, however, one can see that had pneumococcic peritonitis been thought of, the fact that the attack began not with symptoms referable to the appendix, but with those of severe general illness—malaise, headache, high temperature and a rigor,—and that when abdominal pain set in forty-eight hours later it was not localised, but general, the materials for arriving at a correct conclusion, or at all events a strong suspicion, were at hand. On any future occasion under similar circumstances a mistake ought to be readily avoided. But this example shows that to the list of conditions which may imitate appendicitis pneumococcic peritonitis must be added.

The sudden onset and the rapid and grave development of the peritonitis in this case closely corresponded with what is observed in pneumococcic inflammations elsewhere, *e. g.* in the joints, where in several reported cases profuse suppuration has occurred within forty-eight hours.

When it was found, during the operation, that the peritonitis could not be ascribed to appendicitis, the course that should be pursued as to further treatment was somewhat difficult to determine. There was no evidence of perforation of any viscus, or any other cause to which the peritonitis could be attributed. In other words, the origin of the peritonitis was

obscure. Should, therefore, a further search be undertaken, or should an effort be made to disinfect the peritoneum? The former course, which would involve a prolonged operation and perhaps end in a negative result, seemed inadvisable. As to the latter, my own experience has been that in general peritonitis, when the amount of exudation is inconsiderable and not yet purulent, it is better to leave it to be absorbed rather than either to irrigate the general peritoneal cavity or to remove fluid by persistent sponging. Drainage only, therefore, was employed.

There was no feature as to surgical treatment of the empyema on which I need detain the Society. I will only say that suppuration was unusually prolonged, and drainage was rendered difficult by the formation of adhesions producing loculi in which pus was retained, so that recovery, although ultimately complete, was slow.

H. M.

XIII.—*A Case of Pneumococcal Peritonitis.* By Frederick Taylor, M.D. *Read January* 8, 1904.

Alice May B., æt. 8½, was admitted under my care into Guy's Hospital on November 19, 1903. There is no history of phthisis in the family; the father has had an operation for anal fistula, and a half-brother, æt. 16, and a half-sister, æt. 11, children of the father, have died of cirrhosis. This child had measles five years ago, and is said to have had a winter cough.

On November 10, at 5 P.M., she came home from school complaining of pain in the abdomen and difficulty in defæcation; on arrival she had a shivering fit. She was sent to a doctor, who gave her a powder; this she vomited, but another acted on her bowels at 4 A.M. on the 11th. Later on that day the doctor said she had a temperature of 104° and inflammation of the lungs.

On November 12 white blisters appeared on her nose. The bowels were well open, and the motions were offensive and yellow.

On November 17 she complained of acute abdominal pain, and the abdomen became distended. This condition has become much worse. During the last twenty-four hours the bowels have been opened once.

On admission at 2.30 A.M. the temperature was 102°, pulse 140, respiration 50. The patient was cyanosed, very ill, taking no notice of any one, lying on her back with her legs drawn up; on the alæ nasi and about the base of the nose some herpetic vesicles. She complains of pain all over the abdomen, without special localisation. The movements of both sides of the chest are rather limited, and a few rhonchi can be felt on the right side in front. The percussion note is high pitched at the left apex; it is impaired in the left lower axillary region, and both bases behind are dull up to the seventh rib.

On auscultation bronchial breathing is heard over the dull areas behind, and extends into the left axilla, nearly reaching the left nipple, but it is fainter in the left axilla than behind.

Some crackling *râles* are also present on both sides behind. No sputum is brought up.

The abdomen is distended, moderately tense, moving very little with respiration. It is tender all over, with no marked excess of tenderness at any one region. The percussion note is dull in the flanks, but a resonant note extends in front up to the upper border of the seventh rib on the right side and to the upper border of the sixth on the left. No distension nor peristalsis of intestinal coils is visible. The tongue is moist and furred. The heart's beat is within the nipple-line, and there are no adventitious sounds. She is frequently sick, and the vomit contains bile. The urine was passed into the bedpan.

A turpentine enema was given, and later, 10 A.M., one of olive and castor oil, but without result. At 11 A.M. the distension was the same, the pain was increased, and pain was most marked above the pubes. I saw the patient at 2 P.M., and the history of the early pneumonia, the presence of the physical signs in the chest, with the facial herpes and the subsequent occurrence of a definite peritonitis, made me think that a pneumococcal infection of the lung and of the peritoneum was the most probable diagnosis. Mr. Lucas saw the case with me, and it was decided to open the abdomen. At 4.45 P.M. ten ounces of yellowish fæces were spontaneously passed. At 5.15 P.M. Mr. Lucas operated. An incision was made in the middle line from the umbilicus to the pubes; some clear fluid escaped, followed by three or four drachms of greenish-white, mucoid pus, devoid of smell. The greater part appeared to come from the pelvis. The intestines were lustreless and injected, and a large quantity of curdy lymph was removed from them. The abdominal cavity was washed out with hot saline solution for fifteen minutes, three gallons being employed. The pelvis was then mopped out, and some thick lymph was thus removed, and the cavity was again washed out. The peritoneal coat was then sutured, and the muscular layer brought together. A few stitches were put in at the upper end of the wound and the rest left open. A small drain was inserted into the muscular layer, and the wound was dressed with iodoform gauze. A turpentine enema now given brought away a little flatus.

The report from the bacteriological department was as follows:—"Cultivations from these specimens gave a pure growth of the pneumococcus."

November 20.—The temperature has fallen below normal,

but the pulse is still very high, 124 to 140. The wound is looking well.

During the next week the patient went on well; the temperature ranged from 96° F. to 99·4°; the pulse and respiration slowly fell, the former ranging from 120 to 128, the latter from 24 to 30. The herpes cleared up, and the physical signs of the right chest became normal, except for a few *râles* at the base; but on the left side dulness persisted, extending to the mid-axilla, vesicular murmur was absent, and on deep inspiration faint bronchial breathing was heard nearly up to the spine of the scapula.

On November 27 the chest was explored in the eighth space and pus was drawn off. The aspirator was then used, but only six ounces of thin, curdy, odourless pus could be removed.

The bacteriological report on this pus was as follows:—"Cultivations from this material remained sterile. Microscopical preparations direct from the pus showed the presence of badly staining, capsulated diplococci, empty capsules and involution forms, characteristic of a pneumococcic empyema in which the organisms are for the most part dead."

The temperature that evening was 100°, and for the next four days it ranged from 97·4° to 100°.

The physical signs of fluid on the left side persisted, and on December 1, Sir Alfred Fripp opened the chest, resecting a portion of the eighth left rib, and removing twenty ounces of green, odourless pus, with large masses of lymph. The temperature fell to 97° the morning after this, but for the next week there was a gradual rise, the evening temperature reaching successively 101°, 102°, and 103°, and the morning temperature rarely less than 98·4°. Some suturing of the abdominal wound was necessary on December 7. On the 8th three cutaneous abscesses, two on the head and one on the buttock, were opened, and green pus was discharged, and on the 9th one on the abdominal wall was opened.

The bacteriological report on some pus from one of these boils is as follows:—"Cultivations from this material gave rise to a growth of *Staphylococcus aureus.* No pneumococci could be detected."

On December 11 there was some resistance with tenderness in the left iliac fossa, and the next few days this increased so as to form a prominent swelling in the left lower quarter of the abdomen. The bowels were open; rectal examination gave a negative result. The temperature was ranging between

98° in the morning, and 101°, 102°, or 103° in the evening. On the 14th some eight or ten ounces of pus which had been retained in the chest from blocking of the drainage-tube escaped, but without material effect upon the temperature. The iliac swelling continued to increase, and on December 18 it was incised and five ounces of pus were removed. The cavity was extra-peritoneal, and was found to extend for three inches into the left loin; it was drained by sponges and then washed out with saline solution, and a large drainage-tube was inserted. The temperature remained low on the evening of December 18th, but was high again on the evening of the 19th and 20th, and since then has ranged between 97·6° and 100°.

The bacteriological report on the pus last removed from the abdomen is: "Cultivation from this material gives a growth of the *Diplococcus pneumoniæ* associated with the *Staphylococcus aureus.*"

On December 21 a blotchy erythematous rash appeared on the chest, but it disappeared the following day.

On December 30 the lower abdominal wound had healed and the other was looking well. The empyema was still discharging, and the pulmonary vesicular murmur around the wound was deficient. The child was doing well otherwise.

January 8, 1904.—Both abdominal wounds are healed; the wound in the chest is very nearly closed, and the tube has been removed.

The bacteriological reports are by Dr. J. W. H. Eyre, bacteriologist to the hospital, who has since favoured me with the following full memorandum on the peritoneal pus obtained at the first operation:

November 20, 1903.—A. M. B., pus from peritoneal cavity. Microscopical examination of pus direct shows capsulated lanceolate diplococci together with numerous involution forms. Diplococci stain 1 Gram. Cultivations on broth agar and blood agar yielded typical growth of pneumococcus.

November 25.—Rabbit, 1200 grms. weight, was inoculated into the peritoneal cavity with 0·5 c.c. of a twenty-four-hour broth cultivation.

November 26.—Rabbit dead (less than twenty-four hours). *Post-mortem,* heart blood crowded with capsulated pneumococci.

Remarks.—The history of the above case, with the physical signs, results of operations, and the bacteriological examinations, make it quite clear that it is a case of pneumococcal

infection involving the lung, pleura, and peritoneum. A point of interest which the above report may be considered to leave open is the seat of the first infection. A fuller account of the early history of the case, which has been kindly supplied me by Dr. John Kennedy, renders it almost certain that the lung was first involved. He writes: "I had the first evidence by physical signs that the left lung was implicated on November 12. There was then no peritonitis, though the girl had complained of abdominal pain since first taken ill on November 10. The pain, however, was not localised, but was referred to the cardiac region, and also extended to the left iliac; so that I thought the pain was due to the pneumonia. On the 15th the temperature fell, and remained down until the evening of the 16th. On November 17 I suspected peritonitis, and on November 18 when I called there were unmistakable signs of it. As the mother said, I spoke about inflammation of the lung on the 11th, but then I could detect nothing by physical examination. The child's breathing suggested pneumonia, and, so far as my knowledge and observation go, I think the lung became affected first."

Dr. J. H. Bryant, in reporting three cases of pneumococcal peritonitis to the British Medical Association in 1901, suggested that infection by the pelvic organs would explain the great frequency of its occurrence in girls which had been noted by some French observers (Cassalt and Quéhart). In the present case there was a good deal of lymph in the pelvic cavity; but I do not think that could be held to be a strong argument for infection by this channel, in face of the facts in the history suggesting a primary pneumonia.

The child is very nearly well, but I may point out, with reference to the curability of pneumococcal empyemas, that an aspiration did not obviate the necessity of subsequent incision and thorough drainage of the pleural cavity.

XIV.—*A Case of Fibroid Disease of the Pancreas with Calculi, accompanied by Jaundice and subsequently by Diabetes; laparotomy; relief of symptoms; death.*

By Sidney Phillips, M.D. *Read February* 12, 1904.

M. D., æt. 26, married in the year 1898; in September 1899, she had a miscarriage, after which she suffered from uterine pain, and went into a metropolitan hospital where her uterus was "scraped out."

About Christmas, 1901, she began to experience pain about the upper part of the abdomen, gradually increasing in severity, and she soon after noticed a swelling in the right hypochondriac region.

In February, 1902, jaundice came on with colourless stools.

She was brought to me at St. Mary's Hospital by her medical attendant for an opinion; she was then deeply jaundiced; the liver was enlarged and tender, and the outline of the distended gall-bladder could be plainly felt through the abdominal wall.

The urine contained bile but no albumen or sugar.

There was no history of pain at any time, and it seemed improbable that the jaundice resulted from gall-stones.

After this melæna occurred two or three times. I did not see the patient again till I found she had come into the hospital under Mr. Edmund Owen, who had not been informed that I had seen her previously. "On April 3" (I quote from Mr. Owen's report of the case in the *British Medical Journal* of October 25, 1902), "an incision was made over the distended gall-bladder and search was made for a gall-stone, but with negative result; by gentle compression it was found possible to move onwards some of the contents of the gall-bladder. On making further search for the cause of the obstruction, it was found that the head of the pancreas was almost as large as one's fist, and the body and tail were also greatly increased in size; the enlarged gland was hard and lobulated." The wound healed well and the patient, who had been excessively weak on admission, improved in strength and spirits, but the jaundice remained unaltered, and the urine still contained bile; it was of specific gravity 1020 and contained no sugar.

She left the hospital on April 26. On June 14 she returned to the hospital, this time under my care; she had rapidly lost flesh and strength, the jaundice was as deep as before, the tongue dry, thirst severe, and the urine of specific gravity 1050, containing now in addition to bile, 8 per cent. of sugar and giving the diacetic acid test with ferric perchloride.

After rising to 12 per cent., the proportion of sugar fell somewhat, and during her stay in the hospital she passed on an average 130 ounces of urine *per diem* of a specific gravity varying from 1036 to 1044, and containing from 3 to 10 per cent. of sugar—a proportion little influenced by codeia and only to a very limited extent by diet. The temperature rose almost daily to 100°, but there was never any pain.

She was extremely weak, and lost $2\frac{3}{4}$ lbs. in weight during her five weeks' stay in the hospital, at the expiry of which she went home by her own desire, only to return three months later on October 28, so weak that she could hardly stand, very listless, sometimes drowsy, and passing urine containing 5·3 per cent. of sugar.

There was, however, one striking change in her condition, for the jaundice had almost entirely disappeared and the stools contained bile.

She stayed in hospital for a fortnight, during which time her temperature was nearly always 1° or 2° below the normal, and the loss in weight was 7 lbs.

On November 17 she returned home at her own request.

On January 25, 1903, Mr. Percy Rose, of Canning Town, was summoned to her home, found her semi-comatose, with urine of specific gravity 1017, and six grains of sugar in the ounce of urine. She died comatose on January 26.

With great difficulty Mr. Rose obtained a *post-mortem* partial examination, and I am much indebted to him for informing me of all that I know of the case after she had left the hospital. He found the liver enlarged and hard: there were no gall-stones.

The pancreas was greatly hypertrophied throughout, felt very tough, and was riddled with small cysts and with minute calculi: every section cut gritty, and the substance of the organ was tough and fibrotic, but plenty of gland tissue could be seen with the naked eye. The calculi were: one of small size, some the size of a pin's head, others as large as a hemp seed—the duct of Wirsung was dilated in its whole length. Microscopic specimens showing the change in the gland are exhibited this evening. They show dense fibrous tissue in-

volving the whole of the gland; in some parts there is also a small round cell infiltration, apparently a more acute pancreatitis superadded to the chronic process. Some of the elements of the pancreatic tissue remain, but seem to be disintegrating, and in some sections the larger cells, characterising the so-called islands of Langerhans, are scarcely recognisable, being destroyed by the fibroid overgrowth; the ducts of the pancreas and their branches are much dilated.

Remarks.—The nature of the disease, the course of the symptoms, the diagnosis, and the treatment of this case, each seems to merit consideration.

First, the nature of the case.—Only a partial *post-mortem* was obtainable, but I think it may be concluded that the case was one of fibrosis of the pancreas with calculi, and that death resulted from diabetes.

Lancéreaux states that obstruction of the pancreatic duct leads to fibrosis and subsequent atrophy of the pancreas; possibly then the fibrosis in this case resulted from obstruction of the duct by a calculus, which for a time was impacted, producing jaundice, and then passed on.

It seems, however, more probable that the fibroid change and the calculi were associated results of some common cause.

Fibroid disease of the gland is usually set down as arising from a catarrhal condition of the pancreatic duct, arising possibly from entry into it of micro-organisms from the intestine. I do not know how such a catarrhal condition of the duct would be recognisable during life, but it appears to me exceedingly improbable that such a widespread dense fibrous change, with enormous enlargement of the gland as was found in this case, could have arisen from a catarrhal state of the pancreatic duct.

Cases have been recorded in which somewhat similar disease has been preceded by syphilis; no evidence of syphilitic infection could be obtained in my patient, except that the patient had had a miscarriage one year after marriage, and I think the exact cause of the disease must remain undetermined.

Secondly, the course of the symptoms.—Dull pain in the epigastrium, never acute or severe, was the first symptom, and was probably due to the distension of the gall-bladder.

The jaundice may have resulted from pressure upon the common bile-duct by the enlargement of the head of the pancreas. Cancer of the head of the pancreas frequently produces such a result, and it seems unreasonable to deny, as is denied by some, that a non-cancerous enlargement may do the same.

It appears, however, possible that in the present case the obstruction of the common bile-duct was caused by impaction at the duodenal opening of the duct of Wirsung of a calculus similar to those found in the duct *post mortem*, for the jaundice passed off after a time, although the other symptoms of the disease continued to increase.

The diabetes was of the type usually associated with pancreatic disease, with glycosuria excessive and little influenced by diet or by drugs, with great thirst and diuresis, and very rapid emaciation and exhaustion.

The patient suffered from symptoms presumably due to pancreatic disease for six months before sugar appeared in the urine; the occurrence of jaundice brought her under medical observation during the pre-glycosuric period, and it is of interest to note that during this period there was no increase in the specific gravity of the urine, but the patient was extraordinarily weak, much more so than the jaundice would account for.

As is well known, experimental ablation of parts of the pancreas have shown that almost the entire gland must be removed before sugar appears in the urine, and in cases of pancreatic diabetes the gland is usually found much atrophied *post mortem*.

In this case, as in some few others reported, the pancreas was greatly hypertrophied. The hypertrophy, however, had practically led to the destruction of the gland tissue and atrophy of its functions; and it is noticeable that very little is recognisable of the so-called "islands of Langerhans," the destruction of which is said to be essential to the production of pancreatic diabetes.

Many cases of jaundice from chronic pancreatic disease have been recorded, many also of diabetes from the same cause. Clinically this case was specially interesting in presenting severe jaundice and later on diabetes, and from the complete disappearance of the jaundice without evident cause.

As regards the diagnosis, persistent jaundice without ascites or history of biliary colic pointed to pancreatic disease, and the melæna which occurred was confirmatory evidence.

The operation led to the conclusion that the disease of the pancreas was non-malignant pathologically, though it was far from being so clinically.

During the course of the case I gave salol by the mouth several times. On each occasion carboluria quickly ensued, showing, as many other cases of pancreatic disease under my

care have done, that no reliance can be placed on the statement that the diagnosis of pancreatic disease is assisted by the administration of salol.

Treatment.—No dietetic or drug treatment had any effect upon this patient; mercury, iodide of potassium, codeine, pancreatic extract were all tried without avail. The operation performed relieved the patient of some discomfort, probably by the emptying of the distended gall-bladder, but the jaundice persisted long after the operation, and its disappearance eventually could not be attributed to it. The operation cannot be said to have had any influence upon the progressive course of the disease. Cases of recovery from enlargement of the pancreas have been recorded after operation, sometimes after drainage of the gall-bladder, sometimes after merely palpating the gland; probably therefore some cases of enlarged pancreas get well spontaneously without operation. The present case never showed any disposition but to get rapidly worse, and there is probably more than one variety of non-cancerous enlargement of the pancreas.

Perhaps in any future case of operation for jaundice in which simple enlargement of the head of the pancreas is found, it would be well to bear in mind the possibility of a pancreatic calculus being present.

XV.—*Two Cases of Malignant Anæmia, without signs of Erythrocytolysis, and associated with Suppuration about the Jaws.* By Norman Dalton, M.D. *Read February* 12, 1904.

THE patient was a man (D.), æt. 21, and he did heavy work in connection with the machinery of a sawmill. The family history and the past history were unimportant. He was admitted into King's College Hospital in February, 1903, and had then been ill only one month. He left the hospital in July, and died (at home, it is believed) not long afterwards, so that the total duration of the illness was about eight months. The earliest symptoms were those of debility, with pains in the chest, occipital headache and epistaxis. There was neither constipation nor diarrhœa. The symptoms and physical signs which were present while he was under observation may be summed up in a few words, as they were typical of malignant anæmia. He was profoundly asthenic, with giddiness, dyspnœa on exertion, faintness, etc.; there was no emaciation; the skin was dingy yellow, and the mucous membranes pale. The usual anæmic bruits were present, but all the viscera were normal except that there was, at times, a slight increase of splenic dulness. The spleen, however, was never felt. The tonsils were slightly enlarged and he frequently complained of a feeling of weight in the epigastrium. There were occasional attacks of vomiting, and while he was in the hospital it became necessary to give aperients. His sight was bad and, on examination, retinal hæmorrhages were found. There were also, at times, subcutaneous petechiæ, and epistaxis occurred more than once. The blood appeared to ooze from a small abrasion on each side of the septum nasi. On admission, a few small, shotty glands were found in the neck; but otherwise there was no glandular enlargement except in connection with the suppurative lesions to which I will refer. While in the hospital a large patch of brown pigmentation developed on the forehead, chiefly on the left side. This varied in intensity. He showed a marked tendency to hæmorrhage, so that even the punctures in the ear, made for the examination of the blood, invariably bled profusely. The

chief interest concerns the urine, the suppurative lesions, and the blood. The "urine" was always normal and "never high-coloured." In this respect it differed from the urine which is found in those cases of pernicious anæmia which are due to the destruction of red blood-corpuscles. There was once a slight trace of albumen. As regards the "suppurative lesions," his teeth were very carious, and he developed an alveolar abscess on the right side of the upper jaw. At about the same time there was a slight purulent otorrhœa (with perforation of the membrana tympani), and the glands in the neck became enlarged. The alveolar abscess was opened, but a small sinus in the mucous membrane of the hard palate persisted. This sinus could never be explored on account of the risk of hæmorrhage, but the discharge from it became gradually less, and when he left the hospital the opening was thought to be closed. The otorrhœa ceased on treatment and the enlargement of the cervical glands subsided. These suppurative lesions became manifest early in March, six weeks after the onset of the illness and about ten days after the admission of the patient to the hospital. It is probable, however, that they were developing insidiously from the first, because the temperature from the time of admission until the appearance of the alveolar abscess varied from 100·4° to normal, the rise being in the evening. While the suppuration was active (*i. e.* for about fourteen days) the temperature was remittent but higher, being over 103° on two consecutive nights. During the remaining five months of the patient's stay in the hospital the temperature was mostly about 99° at night and 97° in the morning. These remissions probably indicate that the septic process was still going on (although the discharge of pus was less) and that but for the anæmia a much higher remittent fever would have been present. Curiously enough at the beginning of July the temperature remained normal both night and morning for about a week, and it was at that time that the slight improvement in the symptoms was noted. As regards the "blood" there was progressive oligocythæmia. In February the red blood-corpuscles numbered 1,200,000 per c.mm. The number decreased steadily until, on May 9th, it reached 393,720. After this there was a slight improvement, but the maximum observed (on July 7th) was only 600,000. As regards the kinds of corpuscles, fifteen examinations were made in the six months, more than one every fortnight. I am much indebted to Dr. d'Este Emery for

these examinations. On seven occasions no normoblasts were found; on six occasions one or two normoblasts; and on two occasions a "few" normoblasts. The occasions on which the "few" normoblasts were found were in February, when the blood was first examined, and on June 26. The latter date corresponds with the time when the slight improvement in the number of corpuscles was taking place. On one occasion a megaloblast was seen, and on two occasions a few red discs showing polychromatophil degeneration. On the whole, then, it may be stated that the attempt to form new blood-corpuscles by the bone-marrow was unsuccessful. On the other hand, the size of the red discs was very variable; sometimes poikilocytes were found, and occasionally a few megalocytes and microcytes. At the time when the slight improvement occurred the abnormality in the shape and the size of the corpuscles disappeared.

The "hæmoglobin" was estimated on seventeen occasions. It fell from 26 per cent. in February to 13 per cent. in May. This fall coincided with the decrease in the number of red blood-corpuscles, but was not so great, for the colour index, which was 1·08 in February, was 1·8 in May. After this the hæmoglobin increased to 17 per cent. in July, but as the blood-corpuscles increased rather more abundantly the colour index became 1·4.

As regards the "leucocytes" there was marked leucopenia except when the alveolar abscess occurred, when their number was 57,000. Putting this count aside, the number of white corpuscles fell from 9,280 in February to 800 in July. But the decrease was not steady, for in some weeks the count was double that of the week before, although always very small. The most interesting point about the leucocytes was that on every occasion the "lymphocytes" were very much more numerous than the "polynuclears." This was most marked in May, when the number of the red discs was at its lowest. On that occasion there were 19·5 per cent. polynuclears to 78 per cent. lymphocytes. Even when suppuration was occurring and the total number of leucocytes became 57,000, there were only 34 per cent. polynuclears to 58 per cent. lymphocytes. Further, the pus from the ear was found to contain large numbers of lymphocytes. On the other hand, when the number of the red discs was increasing the disproportion between the two kinds of whites became less, and when the patient left the hospital with a total of 800 white corpuscles per c.mm. the proportion was 40 per cent. polynuclears to

53·5 lymphocytes. There is nothing particular to say about the other kinds of white blood-corpuscles. The large hyaline forms varied in number from 9·5 per cent. to 1·5 per cent.; the eosinophils from 3 per cent. to ·5 per cent.; on two occasions 1·5 per cent. mast-cells were found, and on one occasion a myelocyte.

I may mention here that the vomited matter was examined on two occasions. Besides undigested food, mucus, and some unspecified bacteria it contained, on the first occasion, blood pigment and a trace of free HCl, and on the second occasion no free HCl, but blood, pus, and squamous cells. The pus and squamous cells may have come from the mouth.

As regards treatment, arsenic, intestinal antiseptics, and bone-marrow were tried without any benefit. Ten c.c. of antistreptococic serum were injected on two occasions. On the second occasion a good deal of swelling remained at the site of the injection. Shortly after this he insisted on leaving the hospital. At the time when the first injection was given the increase in the number of red discs had been going on for six weeks, and after it the further increase was very slight. As regards the temperature it had been normal night and morning for forty-eight hours before the first injection. On the evening after the injection it rose to 99·2, became normal next morning and rose to 99·6 in the evening. After this it was normal for a week night and morning. These facts do not favour the idea that the injection was beneficial. Still, the treatment did not receive a fair trial, as with the tendency to hæmorrhage, there was a disinclination to make the smallest puncture. On the other hand, the increase in the red discs began synchronously with the administration of pepsin and hydrochloric acid, prescribed when the absence of free HCl from the vomited matter was detected. It would be going too far to attribute the improvement to this prescription, and it is certain that the improvement was slight and not progressive.

The patient died outside the hospital, so that the final phases of the disease are unknown, and there was no *post-mortem* examination.

I think that it will be of use to put on record a summary of the events during the period which I have so often mentioned as the period of improvement. It began five months after the onset of the illness, and was synchronous with a lessening of the discharge from the jaw and also with the administration of pepsin and hydrochloric acid. It

was characterised by (1) a steady, though slight increase in the number of red discs; (2) a slight increase of hæmoglobin, which was not, however, so great as that of the corpuscles, so that the colour index became less than it had been; (3) a disappearance of poikilocytes; (4) the appearance of a few normoblasts; (5) an increase of the leucopenia; (6) an increase in the number of polynuclear leucocytes; (7) a decrease on the whole of the lymphocytes; (8) an improvement of the vision and in the condition of the fundus oculi; (9) an increase of seven pounds in the weight of the patient; (10) a normal temperature for one week. The improvement became stationary for the last three weeks of the patient's stay in hospital, but there was no retrogression.

The second case was that of a woman (F. O.), aged 17, who was admitted into King's College Hospital on December 19th, 1903, and died there on December 23rd. She was too ill to be questioned at length, but it was ascertained that she had always lived in London, and in great poverty. She had been pale and feeble for a long time, but the menses had been regular and rather profuse. She was able to work until three weeks ago, when she felt extremely ill and had severe bleeding from the mouth. A week later she had hæmorrhage from both ears, and became very deaf. She also had a hæmatemesis. Present condition: There is no marked wasting. The skin is rather "lemon" coloured and shows numerous subcutaneous hæmorrhages. The visible mucous membranes, particularly the gums, are very pale, and the lips show submucous hæmorrhages. On the right cheek, below the malar eminence, there is a brawny swelling, and inside the mouth there is a fluctuating swelling of the gum over the upper jaw above one of the molar teeth. There was a small hole in this swelling from which there oozed foul grumous pus in such quantity as to necessitate constant cleansing of the mouth. The breath had a gangrenous smell, and many of the teeth were carious. The usual anæmic murmurs were heard, and the lungs and all other organs were normal. In particular there was no enlargement of the spleen or lymphatic glands. The "urine" was pale and showed a trace of albumen. The "blood" was pale, very fluid, and coagulated slowly. It contained only 816,000 red discs per c.mm. and 17 per cent. of hæmoglobin, so that the colour index was normal. The "leucocytes" were 3,500 in number, 13 per cent. being polynuclears and 80 per cent. lymphocytes. Among the red discs were some macrocytes and microcytes (the latter showing an

increase of pigment), but no normoblasts nor poikilocytes. During the five days in which the patient was in the hospital the temperature varied from 99·4° to 103·2°, the hæmorrhages continued (particularly from the uterus), and there was some vomiting. Shortly before death the red discs fell to 480,000, and the leucocytes increased to 6,800. Arsenic was given, but it was obviously too late to do anything. The swelling on the jaw was not incised for fear of hæmorrhage. The duration of the illness was one month from the first grave symptom.

Post-mortem.—The fat was in fair quantity and not "lemon" coloured. The muscles were of good colour, and did not suggest either fatty or hyaline degeneration. There were extensive subpericardial hæmorrhages with slight pericarditis over them, and subendocardial petechiæ. The heart was small and the lumen of the aorta particularly so. The myocardium showed fatty degeneration. Valves normal. The lungs and pleuræ, the intestines, pancreas, kidneys, and adrenals were normal, except for subserous or submucous hæmorrhages. The subperitoneal hæmorrhages were most marked over the cardiac end of the stomach and the bladder (which was itself normal). The mesenteric glands were a little large and pink. The stomach showed submucous hæmorrhages, except for 2 inches at the pyloric end. The thyroid, the larynx, fauces, and œsophagus were normal. The uterus was small, but otherwise normal, and the ovaries contained some simple cysts. The brain was normal, except for subarachnoid hæmorrhages over the 1st and 2nd left frontal convolutions, and over the left occipital region and the cerebellum. The "spleen" weighed $2\frac{3}{4}$ ozs. and was normal. There was a small splenule. The "liver" weighed $42\frac{1}{2}$ ozs., and was normal in appearance. It was found to contain no free iron. The bile was normal in colour. The bone-marrow of the vertebræ was pale and scanty. A "film" from this marrow showed all the usual cells in fairly normal proportion, except perhaps that the lymphocytes were rather too numerous and the nucleated reds rather too few. Sections of the marrow showed the same cells, but there was a marked diminution in the total number of cells with an apparent increase of the fat. Instead, therefore, of the reticulum between the oil globules being crowded with cells, it was bare as if the cells had been washed or brushed out. The appearance suggested a want of activity in the bone-marrow. The marrow from the long bones was normally fatty. The teeth were

extremely carious, and on cutting into the swelling over the right side of the upper jaw a large necrosed area of bone was found, surrounded by grumous pus, which emitted a gangrenous odour. The necrosis appeared to extend from the prong of one of the teeth continuously to the bone. The pus from this abscess showed an excess of lymphocytes.

Remarks.—It is obvious that these two are cases of the same disease. In both there was extreme oligocythæmia, with practically no production of normoblasts, but with slight abnormalities in the shape and size of the red discs. There was also marked leucopenia (except temporarily, in the first case, when the alveolar abscess was formed), and there was a great excess of lymphocytes over polynuclear leucocytes. As regards the hæmoglobin there was a slight difference, for in the man it was relatively in excess, while in the woman it was relatively normal. In both, however, the total amount of hæmoglobin was diminished. In both cases the urine showed no pigmentation, and in both there was caries of the teeth and suppuration about the upper jaw. I have Dr. Wm. Hunter's authority for saying that the first case corresponds exactly with the form of malignant anæmia which he has described as septic anæmia, and I have no doubt that he will consider the second case to be the same, especially as the *post-mortem* revealed the two conditions which are characteristic of the disease, viz. the absence of free iron from the liver and the absence of any sign of activity in the bone-marrow. In these respects the cases differ from the pernicious anæmia produced by the breaking up of corpuscles. Here I would like to remind the Society of a case recently brought before it by Dr. Pasteur, which was in many respects of the same kind as mine. There was the same extreme oligocythæmia without the presence of normoblasts, and the same leucopenia with great relative increase of lymphocytes. The colour index was about normal, as in my second case. All three cases ran a very rapid course, viz. eight months in my first case, seven weeks in Dr. Pasteur's case, and four weeks in my second case. Clinically the great difference is that in Dr. Pasteur's case there was no oral lesion and no suppuration in any part of the body. As regards the *post-mortem* appearances; in Dr. Pasteur's case the bone-marrow presented the same deficiency of cells as was found in mine, but there was this great difference, viz. that the liver contained a large quantity of free iron. Dr. Pasteur's case was, therefore, somewhat anomalous, but it shows that a fatal anæmia can

occur without any symptoms of hæmolysis during life, and presenting all the symptoms of the so-called septic anæmia, although no suppurative lesions existed.

It would therefore follow that "septic anæmia" is perhaps not the best name for the condition. It is a secondary malignant anæmia, associated in a remarkable number of cases with sepsis, and with oral sepsis in particular, but possibly occurring at times without suppuration. As Dr. Hunter has himself stated, there must be some other factor in the ætiology. It is certain that people may go about for years with carious teeth, and may even develop an alveolar abscess without the occurrence of malignant anæmia. In the same way not every case of cancer of the stomach produces a profound anæmia. But to return to the question of oral sepsis, my two cases strongly confirm Dr. Hunter's most valuable observations. It would seem that a man with carious teeth lives in constant danger, for at any moment some new, at present unknown, factor may come into play and produce an anæmia which may be fatal in a few weeks. The state of affairs may be compared to that of a woman with an adenomatous tumour in the breast which, although causing no inconvenience itself, may at any time become malignant through the action of some unknown factor. The importance of recognising the oral sepsis early cannot be exaggerated, because the moment the malignant anæmia sets in it becomes impossible to treat the teeth on account of the hæmorrhage. I was told that some weeks before the grave symptoms began my second patient went to a hospital and was treated for anæmia, and I cannot help thinking that if her teeth had then been treated the anæmia might never have become malignant; in fact, Dr. Hunter records cases in which recovery followed on the removal of the septic condition. Curiously enough I have under my care at the present time a case of great interest. It is a woman of about 40, who had a hæmatemesis about six weeks ago, which was pretty clearly due to a gastric ulcer. There is reason to believe, however, that she has been anæmic for about six years and her jaws are covered with the stumps of decayed teeth. Her blood condition is: Red discs, 2,440,000; white corpuscles, 9,600; and hæmoglobin 26 per cent. This makes the colour index rather more than 50. Of the leucocytes 66 per cent. are polynuclears and 28·5 per cent. lymphocytes. There are no normoblasts. The urine is pale. I do not think that the above blood condition can be due to the loss

of blood from the gastric ulcer six or seven weeks ago, especially as she had symptoms of anæmia before then. It is true that the blood condition is that of an ordinary chlorosis except that the oligocythæmia is so great. Also chlorosis is not common at this age. The stumps of her teeth are being systematically removed, and it will be interesting to see whether any rapid improvement in the blood state will follow these operations.

XVII.—*A Note on a Case of Ankylosis of both Temporo-maxillary Joints.* By J. Jackson Clarke, M.B.Lond. *Read February* 12, 1904.

On April 24, 1899, four years and seven months ago, I operated on a woman, æt. 32, for ankylosis of both temporo-maxillary joints.* At that time the movement in the joints was limited to that which enabled the patient to separate the teeth by less than an eighth of an inch. The cause of the ankylosis was of a pyæmic nature, and I thought it safer to restore the power of movement to the patient by removal of the neck of the bone on both sides rather than by forcibly breaking down the adhesions in the joints; it is well known that where ankylosis follows suppuration in a joint there is danger of a recurrence of suppuration if the adhesions are forcibly broken down. The immediate result of the operation was all that could be desired, and the patient carefully carried out the instructions that I gave her as to after-treatment. This consisted in daily passive and active movements, depressing and pushing forward the jaw, and biting on india-rubber wedges which were placed between the bicuspid teeth of the upper and lower jaws on each side.

Earlier in the present year I heard from the patient that she was having some trouble with some of her teeth. The importance of preserving the molar teeth in order to maintain the separation of the stumps of the necks of the jaw from the skull led me to advise her to see my dental colleague Mr. Lewin Payne with me in consultation. We then found that the power of voluntary separation of the teeth, measured from the cutting edge of one upper to the corresponding lower incisor, had become reduced to half an inch from about an inch immediately after the operation. We decided that the proper course to pursue would be to have ether administered for the double purpose of forciby increasing the opening the jaws by means of wedges and of enabling Mr. Payne to remove some decayed teeth. Ether was given by Dr. Barford and the separation of the jaws was consider-

* The case was reported in *The Hospital* of October 7, 1899.

ably improved, a conical screw gag proving the most efficacious for the purpose. Mr. Lewin Payne subsequently made dentures carrying teeth to replace those removed, and at the present time the patient can masticate well and separate the edges of the incisor teeth for three-quarters of an inch, as shown by a photograph taken in November of the present year.

On January 12, 1900, I presented to the Society a girl, æt. 8 years, on whom I had done a similar operation for unilateral ankylosis. In this case the immediate result was very good, but I heard recently from a friend into whose care she had passed that the ankylosis had recurred, and that he proposed to excise the angle of the jaw. Two facts, I think, account for the recurrence of ankylosis in this case: first, the molar and bicuspid teeth had been removed from the affected side before she came into my hands, and second, the child's mother had failed to carry out the after-treatment, and neglected to bring her up to the hospital from time to time. As shown by the case of my older patient the prolonged success of the operation depends on simple exercises being practised daily, and on proper care of the teeth by a skilled dentist. Whether the result of the operation can be improved by covering the lower cut surface of the bone with a layer of gold foil at the time of operation appears to me to be worthy of consideration.

XVIII.—*Primary and Secondary Local Tuberculosis of the Thyroid Gland.* By EDRED M. CORNER. *Read February* 12, 1904.

THESE two cases are brought before the Clinical Society for their rarity rather than for any bearing which they have on everyday practice. Practically the only point of clinical interest which they illustrate is the healing of wounds in a subject of relative athyroidism, or better, inadequate thyroidism.

Virchow, in his famous *Geschwülste*, ii, 679, says that tubercular disease of the thyroid is very rare, and adds in a footnote that in miliary tuberculosis it is not unknown. Chiari says (*Wien. med. Jahrbuch*, 1878), in a paper, "Ueber Tuberculose der Schildrüse," that he found that the thyroid was affected seven times in 100 *post-mortem* examinations of subjects who had died of some tubercular infection. Ziegler, in his *Pathologische Anatomie*, also says that it is seldom found. Fraenckel, in the *Arch. fur Path. Anat. Berlin*, 1886, civ, pp. 58—72, found that the thyroid was always involved in miliary tuberculosis, but only found it otherwise affected in six out of 380 *post-mortems* of subjects who died from tubercular disease. Mr. Berry has shown two thyroids affected in miliary tuberculosis (*Path. Trans.*, xli, p. 261, and xlii, p. 298). In the latter volume Dr. Voelcker records three similar cases. All authorities who have examined the question agree as to the thyroid gland being frequently involved as an incident in general miliary tuberculosis. Local, and especially primary, tubercular affections seem to be rare. It is for this reason that these two cases are reported. But before reporting my cases reference will be briefly made to one of Schwarz and one of Rolleston's.

Schwarz records his case in the *Arch. Internat. de Laryngologie, etc.*, Paris, 1894, vii, 320—324. A man, æt. 30, had a swelling in the right lobe of his thyroid, with paralysis of his right recurrent laryngeal nerve. The swelling was incised and an abscess opened and drained. Guinea-pigs

inoculated therefrom died of general tuberculosis. The man recovered.

Dr. Rolleston, in the *Path. Trans.*, 1896–7, xlviii, 197—200, collected almost all the literature to that date, and records a case in which he found caseous masses in the thyroid of a man æt. 23, who died of paraplegia due to caries of the spine.

Professor Kocher, of Berne, has seen a few examples of tuberculous goitre, but says that they are very rare. It will thus be seen that localised tubercular foci in the thyroid, both primary and secondary infections, are of sufficiently uncommon occurrence as to merit record.

Case 1.—*Apparent primary tuberculosis of the thyroid.*—M. E. B., female, æt. 9, was admitted to St. Thomas's Hospital in 1901 with the history of having had swellings in the neck for a year. On examination, numerous small, though enlarged glands were felt in the neck. The right lobe of the thyroid was larger than the left, and in its lower part was soft and fluctuating. The left lobe was hard, and at the apex a sinus opened on the surface of the skin. Operation was performed on April 4, 1901. The swelling on the right side of the neck extended outwards behind the carotid sheath, the vessels being stretched over it. An abscess in the thyroid was opened, which contained between one to two drachms of pus. Microscopic examination of part of the wall of the abscess showed chronically inflamed thyroid tissue and tubercles. Two or three of the lymphatic glands were removed, and appeared to be in an early stage of tubercular infection. The sinus on the left side of the neck and the diseased portion of the left lobe were also removed. The convalescence presented only one feature of note, namely, the absolute refusal of the wounds to heal. Twenty-six days after operation she was sent to a convalescent home. Two months after the same date she was again admitted with tubercular dactylitis of one finger. The following note was made: "The wounds in the neck have not healed, and are covered with a yellowish gray kind of membrane." Three and a half months after the operation she had some fits which were diagnosed as epileptic. Soon after this she was put on Liq. Thyroidei in increasing doses. In a very short time there was marked improvement in the appearance of the wounds, her general health, mental and facial conditions. The fits ceased, though she had one or two fainting attacks. She died seven months after the

operation. Dr. Emin, who sent me a full account of her last illness, says that she died of tubercular meningitis and acute general tuberculosis.

Besides the rarity of the pathological event, this case is interesting on account of the lack of thyroid secretion, almost entirely due to the action of the disease, which prevented the healing of the wounds; the marked improvement, both general and local, which followed the administration of thyroid extract: to all appearances the disease of the thyroid was primary, and the condition of inadequate thyroidism may have predisposed to dissemination of the infection and the general tuberculosis.

No signs of tubercular disease could be found in the lungs before the operation.

The second case illustrates the secondary involvement of the thyroid, as a local caseous mass, in a case which died of pulmonary thrombosis and phthisis. During life an asymmetrical swelling of the thyroid was noted, though the pathological condition present was not suspected.

Case 2.—*Secondary local tuberculosis of the thyroid gland.*—As this condition was found *post mortem* the case can be shortly treated. The subject was admitted under the care of Dr. Hawkins. The woman died of thrombosis of the pulmonary vessels and phthisis. There was a caseous mass the size of a walnut in the right lobe of the gland. There were no symptoms of inadequate thyroidism noted.

XIX.—*A Case of Chronic Polycythæmia with Enlarged Spleen, probably a Disease of the Bone-marrow.* By F. Parkes Weber, M.D., F.R.C.P., and J. H. Watson, M.B., B.S. *Read March* 11, 1904.

THE patient, Gerardus R., a cabinet-maker, æt. 58 years, a native of Holland, who since 1871 had lived in England, was admitted to the German Hospital at the end of November, 1903, complaining of vertigo and inability to do his work properly. He was then found by Dr. Weber to present the peculiar symptom-complex, chronic cyanosis with enlargement of the spleen, and polycythæmia. Following is the past history.*

He was said formerly always to have had a very ruddy complexion, but during the last six or seven years an increasing liability to blueness of the nose and extremities had been observed. He had always been subject to indigestion, constipation, headaches, and occasional insomnia. Five years ago he brought up some blood (? hæmatemesis), and attended as an out-patient at a London hospital, but had no recurrence. At one time he seems to have been treated for stricture. No history of any other illnesses was forthcoming. He had certainly always been strictly moderate in regard to alcohol, and was known to have had a great aversion to intemperance. Of late years he had been subject to giddiness and feelings of weakness in the knees. The giddiness often came on when he got up from a chair or bed, and when he was doing his work. It had prevented him from following his employment during the last year or so.

In the latter part of the summer of 1903 he fractured some ribs and was an in-patient from August 31 to September 23 at the German Hospital. After leaving the hospital he had some mental trouble (part of his possessions were apparently sold to pay his rent), and ideas of persecution were first noticed. When readmitted to the hospital on November 30 his manner was quite different to what it had been before. He had become extremely emotional. It was

* Some of it obtained from a daughter of the patient.

difficult to get him to eat, and he had delusions. On December 7 he had to be removed to an infirmary, and on December 11 was transferred to Colney Hatch Asylum.* His mental condition seemed to improve there at first, and he nearly lost his delusions, yet he remained bodily and mentally feeble. On the morning of February 4 marked increase of the cyanosis was noted, and he died suddenly from syncope in the evening.

Family history.—Father and mother lived to a fair age; the former is said to have died of "heart disease." Several brothers and sisters are living in Holland, and some or all of them are remarkably ruddy in the face. There is no family history of insanity. The patient had one son who died of consumption. Another was epileptic, and died at nineteen years of age. Two other sons and two daughters are living and healthy.

Clinical Features of the Case as observed at the German Hospital and Colney Hatch Asylum.

The patient was a well-proportioned man with fair muscular development, but rather thin. His weight in December, 1903, was 10 st. 3 lbs. His skin was dry, and he was always more or less cyanosed. His fingers were slightly clubbed.

The cyanosis.—This was specially marked over the nose, malar prominences, lips, ears, hands, and feet. It varied in degree considerably from time to time. It was markedly increased whenever the patient became mentally excited, and was extreme shortly before he died. A slight pigmentation of the skin of the face was probably a result of the chronic cyanosis.

The temperature was slightly subnormal.

Thoracic organs.—There was evidence of a moderate amount of pulmonary emphysema. The heart presented no obvious signs of disease. No murmur was heard on any occasion. The respirations averaged fifteen per minute, the pulse being generally about sixty-five per minute.

Circulatory system.—The radial arteries felt a little thickened. The pulse was regular, of average frequency (about 65), of medium volume, and generally of decided high tension. Sphygmographic tracings with a Dudgeon's instrument showed a pulse of sustained pressure, almost anacrotic in

* We must express our thanks to Dr. W. J. Seward, medical superintendent of the asylum, through whose kindness every facility was given us to make our observations.

character. By Hill and Barnard's pocket sphygmometer we estimated the blood pressure in the radial artery as equivalent to about 120 mm. mercury,* and on different occasions by their larger instrument on the arm we found it reached 140 to 170 mm. mercury. There were no varicose veins in the lower extremities, and no venous pulsation or distension at the root of the neck was observed. Dr. R. Gruber kindly made an ophthalmoscopic examination, and found nothing abnormal except extreme distension of the retinal veins and very minute vessels, some of the veins having a slightly moniliform appearance. Doubtless, chiefly owing to the distension with blood, many minute vessels were visible which in ordinary persons would be invisible.

The abdominal organs.—The *spleen* was certainly enlarged, and could easily be felt during inspiration below the costal margin. By palpation nothing else abnormal could be found. There was no distension. We thought that the liver was not enlarged.

The urine.—The average daily quantity of urine was estimated at about 40 ounces, whilst the patient was drinking about 55 ounces of fluid *per diem*. Dr. Watson estimated the urea in the urine at about 13·25 grains to the ounce, which would make a daily excretion of about 530 grains (34½ grammes)—that is to say, about the normal amount. The urine was of about specific gravity 1020, usually clear, acid, free from sugar, but yielding a cloud of albumen (about 0·5 per mille by Esbach's tube). It was of a deep orange colour, and on dilution showed a urobilin absorption band by spectroscopic examination. Heating with a little nitric acid heightened the colour. The addition of a perchloride of iron solution caused a reddish-brown colour reaction. No urinary casts were detected by the use of the centrifugal machine and microscopic examination. Following is a report on a specimen of the patient's urine kindly written out for us by Dr. A. E. Garrod:

"The urine contained a large amount of uro-erythin, and threw down a deep pink urate sediment. The filtrate showed a very pronounced urobilin band, the amount of urobilin being obviously considerably in excess. The filtrate was rendered acid with acetic acid, and was then shaken with some amylic alcohol. The amylic extract showed a dark uro-

* That is the pressure at which the *maximum pulse oscillations* were shown by this instrument, not the pressure sufficient to suppress the oscillations.

bilin band and very faint bands of hæmatoporphyrin, indicating an amount of that pigment rather above the normal trace, but only such as is often seen in morbid urines. The presence of this last pigment in such amounts has no special significance. The pigmentation of the urine was such as is often seen when there is either organic disease or functional derangement of the liver."

The blood.—At the beginning of December, 1903, when the patient was at the German Hospital, the hæmoglobin value of his blood from finger and ear, was estimated (Dr. Campiche at the request of Dr. Weber) at about 150—160 per cent. of the normal. Red cells about 9,000,000 per c.mm., white cells about 12,000. No abnormal blood-cells were seen. At Colney Hatch Asylum we were able, after saturating the blood with coal-gas, to carefully estimate the hæmoglobin value by using Haldane's modification of Gowers' hæmoglobinometer. Though this instrument is graduated to measure only up to 130 per cent., the divisions of the scale are at equal intervals from each other, and so we were able to calculate that the hæmoglobin value in our patient was approximately 170 per cent. Four blood-counts were made on different occasions at Colney Hatch and the red corpuscles were estimated at between ten millions to slightly over eleven millions, and the white cells at between 7,500 and 8,000 per cubic millimetre. On January 17, 1904, the red cells were put down as 10,700,000, the white cells as 8,000. The white cells were not counted at the last examination, namely on January 29, when the number of red cells reached 11,150,000. Blood-films of January 31 were searched for erythroblasts, but with a negative result. A differential count of white cells was made by Dr. G. L. Eastes (December 21, 1903). Of 400 white cells counted he found that the small lymphocytes made up 13·2 per cent., the large lymphocytes 4·2 per cent. (total lymphocytes 17·4 per cent.), polymorphonuclears 82·4 per cent., and coarsely granular eosinophile cells 0·2 per cent. Dr. Eastes added that during the count no myelocytes or other abnormal cells were seen, and there was no poikilocytosis. The average diameter of the red blood cells (Dr. Watson by Ramsden's micrometer eye piece) was found to be 7·1 micro-millimetres (measured in dried films), that is, if anything, slightly below the average. On a glass microscope slide * the coagulation time of the blood (that is, for the beginning of coagulation),

* *Vide* the clinical method recommended by Dr. M. Copeman in Allbutt's *System of Medicine*, vol. v, p. 451.

was found to be one and a half to two minutes. We endeavoured by Hammerschlag's and by another method to estimate the specific gravity of the blood and made it slightly over 1060, but we may have underestimated it.

The Nervous System and Mental Symptoms.—Nothing abnormal was found on examining the patient's pupillary reactions, knee jerks, or other reflexes. No motor paresis, incoordination or abnormality of sensation was to be found. The muscular sense was normal. The speech was not affected, except that it was rather slow, perhaps owing to mental confusion. We need not add anything to what we have already said in regard to the headaches, the vertigo, and the feelings of giving way of the knees and prostration, to which the patient was subject. The following *résumé* (Dr. Watson, January 24, 1904) of his mental symptoms at Colney Hatch Asylum shows that the state of his mind was one of "confusional insanity:"

"The patient is very talkative, very confused, and more or less incoherent; his sentences are very disjointed. He seems not to know where he is. He is slow in understanding what is said to him. He behaves himself fairly well, and is not violent or destructive, but rather slovenly in his dress; in his habits he is quite clean. Since admission he has taken little or no interest in his surroundings. As a general rule he sits moping in front of the fire, and has to be literally dragged away to his meals. At the table he plays with his food, eating very slowly, and apparently with no relish. After meals there is the same difficulty in getting him to leave his seat. His mood is changeable, but for the most part depressed. His moral conceptions and judgments are quite natural. His memory is much impaired both for past and recent events. He does not mistake objects (apraxia). At present there is no evidence of illusions or hallucinations. Delusions are not marked, but at times evident, and of a depressive type. At one time he was convinced that his food was poisoned. He has no suicidal tendency."

Necropsy (Dr. Weber).

To avoid repetition we will say at once that one of the most remarkable appearances noted was the extreme distension of all the minute venules with blood. This was especially striking when the abdomen was opened. The minute mesenteric venules reminded one of the appearance seen in

an anatomical preparation in which the vessels had been very forcibly injected with some dark bluish "mass."* This corresponds to the state of things found in a similar case by Türk (see *Literature* at the end) and likewise exactly corresponds to Dr. Gruber's description of the fundus oculi during life (to which we have already alluded). We may also here mention that all the viscera were hyperæmic. In fact, as a histological examination of the various organs subsequently showed, the microscopic blood channels were engorged with blood just as were the minute venules which could be seen with the naked eye. All the medium-sized arteries (radials, basal arteries of the brain) seemed somewhat thickened.

Brain and skull.†—On the inner surface of the calvarium the vascular grooves are peculiarly well-marked, in fact, more of these channels are seen than in ordinary skulls. This doubtless corresponds to the distension of small and medium-sized veins all over the body, to which we have already referred. There is slight thickening of the pia-arachnoid, which is intensely congested. The membranes strip easily and leave no erosion. No gross lesion can be found in the brain. The cortex is unduly dark, evidently due to the vascular engorgement and dark colour of the blood. Weights: Whole brain, 1460 g. = $51\frac{1}{2}$ ounces; right cerebrum, 640 g. = $22\frac{3}{5}$ ounces; left cerebrum, 635 g. = $22\frac{2}{5}$ ounces; cerebellum, pons and medulla, 190 g. = $6\frac{7}{10}$ ounces; right cerebrum, after stripping off membranes, 610 g. = $21\frac{1}{2}$ ounces. The pituitary body is not enlarged.

Lungs.—Large and moderately emphysematous, somewhat unduly covering the anterior surface of the heart. There are a few small hæmorrhagic infarcts (? thrombotic or embolic) in the anterior edge of the lower part of the right lung, and one at the base of the left lung. Both lungs engorged with blood. No evidence found of old or recent tubercle, except a little pleuritic puckering from slight former disease at both apices. No pleuritic adhesions, but a few small flakes of recent lymph are present at the left pulmonary base. Weight of both lungs together 1300 g. (46 ounces).

Heart.—Of medium size, but showing a decided relative

* It must be remembered, however, that the distinctness of all the small veins was doubtless due not only to their distension, but also to the high hæmoglobin value and the venosity of the blood they contained.

† Kind assistance was given by Dr. C. F. Beadles at the necropsy, especially in the examination of the brain.

hypertrophy of the left ventricle. Weight about 298 g. (10½ ounces).* Both ventricles firmly contracted.† The mitral orifice admits two, the tricuspid orifice three fingers. The two anterior curtains of the aortic orifice are partly united by an old, hardish vegetation (of the size of a medium pea) situated between them, but excepting slight thickening of the mitral cusps there is no other valvular disease. No aperture in the interventricular or interauricular septa. No congenital disease. The ductus arteriosus is represented by a thin tendinous cord. There is some slight atheromatous change in the thoracic aorta. There is a little (possibly *ante-mortem*) colourless clot rather firmly fixed in the meshwork of muscular trabeculæ of the right auricular appendix. We may here point out that the weight of the heart and the absence of any murmur during life prove that the mechanism of the aortic valves cannot have been much impaired by the old slight disease found at the necropsy.

Spleen.—Uniformly enlarged. Weight 655 g. (23 ounces). A few small perisplenic adhesions. There is one tough, whitish, depressed wedge-shaped scar on the convex side of the spleen, doubtless representing an old infarct. On section the splenic substance appears normal to the naked eye. There is no disease in the splenic arteries and veins.

Liver.—Weight 1760 g. (62 ounces). No evidence of disease. No nutmeggy appearance on section.

Kidneys.—Weight of both together 445 g. (16 ounces). Capsule strips fairly easily. Cortex not noticeably diminished. The substance of both these organs is rather hard.

The *supra-renal capsules* appear macroscopically not to be diseased‡; and nothing unusual is observed in examining the *urinary bladder* and *testes* beyond *varicocele.*

The alimentary canal.—The mucous membrane of the stomach is intensely congested. A round ulcer, with sharp

* This weight was taken only after the heart had been lying for a considerable time in weak formalin, but the weight of the spleen which had been lying with it was found to have hardly altered at all.

† Albanese, in his experiments on the hearts of frogs, found that if the circulating fluid was not viscid enough the heart's action was arrested in diastole. In conditions of polycythæmia, as we shall subsequently point out, the blood is too viscid (*Arch. f. exp. Path. u. Pharm.*, Leipzig, 1893, vol. xxxii, p. 296).

‡ In regard to the occurrence of hypertrophy of the supra-renals in connection with changes in the blood-vessels (*vide* Gouget, Société de Biologie, Paris, December 19, 1903; and O. Josué, *Presse Médicale*, Paris, May 4, 1904, p. 281; and Aubertin and Ambert, *Tribune Médicale*, Paris, 1904, p. 119), we are sorry that we omitted to take the weight of these organs.

edges, of the diameter of a shilling, is situated on the posterior surface about two inches away from the pylorus. At the site of the ulcer there are old peritoneal adhesions between the stomach and the adjacent parts. The lymphatic follicles of the mucous membrane of the ileum near the ileo-cæcal valve appear somewhat enlarged, but otherwise there is no intestinal disease. Some "coffee ground" material is noted on opening the stomach and intestine (? from the gastric ulcer or congestion of the gastric mucous membrane).

The mesenteric glands are moderately enlarged. No big hæmolymph glands are to be found near the aorta.

A few atheromatous patches are present in the lower part of the *abdominal aorta.*

The *thyroid gland* weighs 35 g. ($1\frac{1}{5}$ ounce) and appears normal to the naked eye.

Bones and joints.—The left humerus, sawn through longitudinally, shows red transformation of the marrow of the whole of the shaft. The left femur and the right tibia, both sawn through transversely in the centres of their shafts, show bone-marrow of the same deep red appearance. Transverse section through the shafts of smaller long bones, namely the right fibula, the right radius and the right ulna, shows relatively pale and fatty-looking marrow. The cancellous tissue of the sternum is very red. On examination of one of the large joints (left shoulder joint) nothing abnormal can be found.*

Microscopical Examination.

An account of the examination of the blood has already been given.

The *bone-marrow.*—Sections of bone-marrow from the shaft of the left humerus were stained (1) by hæmatoxylin and eosin, (2) by methylene blue and eosin, (3) by polychromic methylene blue, (4) by Jenner's blood-stain, (5) by Leishman's blood-stain, (6) by Ehrlich's triacid stain, (7) by Mann's biacid methyl-blue and eosin mixture (*vide* Mann's description of his longer method in his *Physiological Histology,* 1902, p. 216), (8) by carbol-fuchsine and methylene blue.

The tissue was found to consist of nucleated cells and thin-walled vessels distended with blood.

* We have to thank Dr. F. W. Mott, F.R.S., Pathologist to the London County Asylums, for his kind interest and the loan of several instruments. He was prevented by illness from being present at the *post-mortem* examination.

The fat cells, of which normal marrow from the shafts of long bones chiefly consists, were represented only by a vesicle here and there. Four classes of nucleated cells could be distinguished—

(A) The greater portion (*i. e.* greater in bulk if not in actual number) were rounded or polygonal cells, containing a rather large vesicular nucleus with scanty chromatin network surrounded by a good deal of faintly-stained protoplasm gener-

FIG. 3.—Microscopic section (hæmatoxylin) of the bone marrow from the shaft of the left humerus (× 220). It shows a tissue consisting of myelocytes, erythroblasts, and giant-cells, together with thin-walled dilated blood-vessels full of red blood corpuscles. There are no fat vesicles visible. The erythroblasts are distinguished in this specimen by their small dark nuclei. Most of the other nucleated cells are myelocytes (the eosinophile myelocytes are not specially stained in this specimen). There are several giant-cells present.

ally without distinct granules. Although we seldom saw any distinct granules in these cells, we regard them as "representing" the ordinary neutrophile myelocytes. We have, however, no objection to calling them, at least those which showed no distinct granulation, "mononuclear cells of the large lymphocyte type," for we believe that cells of the large lymphocyte type, when they occur in the bone-marrow, should be generally regarded as "non-granulated myelocytes." Certain cells, which apparently belonged to the same group,

were smaller, had little protoplasm around their nuclei, and reminded us of ordinary lymphocytes.

(B) Scattered about throughout the sections were a fair number of cells somewhat resembling class A, but their nuclei were often smaller and more deeply stained, and were sometimes lobed or otherwise irregular in form, and their cytoplasm contained eosinophile granules. These we regarded as eosinophile myelocytes, although their granulation appeared less coarse than that of typical coarsely-granular eosinophile cells.

(C) Almost as numerous as the cells of group A, and in some parts of the sections more numerous, were cells having a nucleus staining very deeply (at least with hæmatoxylin and with methylene blue) and quite or almost homogeneously. In these cells the amount of cytoplasm around the nucleus varied considerably, but most of the nuclei seemed to be surrounded by a thin film only. Moreover there were a great many nuclei apparently without any cytoplasm around them. Chiefly on account of the intense staining of their nuclei we regarded these cells as erythroblasts, though their cytoplasm with most of our stains took on a different colour to that taken on by the erythrocytes. The cells and also their nuclei were not all of the same size, but by far the majority might be classed as normoblasts or the nuclei of normoblasts. Sometimes two or more nuclei were seen in the same cell, and sometimes the nucleus appeared rosette-like or irregularly split up. These cells were very unevenly distributed through the sections, occurring scattered about in some parts, but in other parts collected together in clumps. Their nuclei, notably the nuclei without any protoplasm around them, were generally deeply tinted by the eosin in sections stained by Mann's eosin-methyl-blue method.*

(D) A good number of large endothelioid cells and typical giant-cells were present scattered about over all parts of the sections.

For certain reasons, into which we need not enter, a search for tubercle bacilli in the bone-marrow was made, but with negative results.

The spleen.—The Malpighian corpuscles appeared normal. The enlargement of the organ seemed to be due merely to increase of the splenic pulp and engorgement with blood.

Sections of an enlarged *mesenteric lymph-gland* from near

* Possibly owing to some necrobiotic change having occurred.

the stomach showed considerable increase of the fibrous tissue of the trabeculæ, apparently the result of chronic adenitis. Considering that the patient had a chronic ulcer of the stomach this evidence of chronic inflammation in a neighbouring lymph-gland was not surprising.

In sections of the *liver* nothing remarkable was seen beyond engorgement of the organ with blood and a certain amount of deposit of brown pigment granules in the central portions of the acini. Although this pigment deposit is similar to that which is ordinarily seen in chronic venous congestion of the organ, there was evidently no near approach to the condition of "nutmeg liver." By the potassium ferrocyanide and hydrochloric acid method no evidence of the presence of free iron was obtained in sections of the liver and spleen.

Microscopical examination of a *kidney* showed no interstitial nephritis, and certain parenchymatous changes in the renal epithelium were probably of *post-mortem* origin. A feature worth mentioning was the remarkable engorgement of the minute renal blood-vessels. In fact, in sections counterstained with eosin the appearance due to the vascular engorgement was similar to that in sections of a kidney the vessels of which had been forcibly injected with a bright red material for demonstration purposes.

Transverse sections of both right and left *radial arteries* seemed to show a decided relative increase in the size of the muscular coat ("arterial hypermyotrophy"), all due allowance being made for shrinkage during preparation of the specimens. This confirmed our previous conclusions as to thickening of the medium-sized arteries generally.*

Remarks.

It is quite clear that the foregoing case is an example of the clinical group described under the heading "Polycythæmia with Splenomegaly and Chronic Cyanosis," or under some similar heading, by several different observers, and in the English language, notably by Osler (see *Literature* at the end).† We must here shortly recapitulate the main points.

* We have to thank Mr. S. G. Shattock for his kindness in looking through sections of some of the viscera with us.

† Perhaps cases of chronic cyanosis with enlarged spleen and polycythæmia in which the splenomegaly was found to be due to tuberculosis (as in the case of Rendu and Widal) should be placed in a separate group. In acute tuberculosis of the spleen (as in D. D. Stewart's case) polycythæmia may be absent, possibly because the disease has not lasted long enough.

The patient was a man æt. 58 years, who had always been very ruddy in the face, though strictly temperate with regard to alcohol. He had apparently usually enjoyed fair general health, though always inclined to "indigestion" and constipation. A tendency to blueness of the nose and extremities had been noticed during the last six or seven years. Latterly he had been subject to feelings of giddiness and prostration, which prevented him from following his employment.

At the end of 1903, some time after an injury (fracture of ribs), he began to suffer from delusions, and had to be admitted to a lunatic asylum, where, in spite of apparent mental improvement, he seemed to get weaker. He died suddenly of syncope during a period of increased cyanosis.

The *post-mortem* examination showed the presence of a certain amount of pulmonary emphysema, and slight old disease at the aortic orifice of the heart, but these changes were quite insufficient to account for the enlarged spleen, and for the polycythæmia,* and the other symptoms observed during the patient's life. Moreover, the liver had not the typical "nutmeg" appearance of chronic passive congestion as it would have had if the enlargement of the spleen had been due to pulmonary emphysema and cardiac disease. On the other hand, the examination of the patient's bones showed that almost all the ordinary yellow (normal) marrow of the shafts of the long bones was in this patient replaced by red marrow, from which fat cells were nearly absent, in other words, the amount of erythrocyte-forming tissue in this man's body was immensely greater than in the bodies of ordinary persons. It became, therefore, obvious that even if the formation of red blood-corpuscles had not been particularly active in any one part of the bone-marrow, the total production of red cells in the patient's body must have been much above the average, owing to the great excess of the tissues engaged in manufacturing them. In this connection it may be noted that in Cabot's second case, and in two of Türk's cases, erythroblasts were found during life in the circulating blood, indicating increased activity of the erythrocyte-forming functions of the bone-marrow (see *Literature* at the end). In regard to destruction of red cells, we have no

* Contrary to the statements of some writers it seems that in chronic cyanosis due to heart disease the red corpuscles may exceed seven or eight millions per cubic millimetre. Thus, in a seven-year-old girl with congenital pulmonary stenosis Friedel Pick (*Verein deutscher Aerzte in Prag*, January 22, 1904) recently found the erythrocytes to be over ten millions per cubic millimetre.

certain evidence in our case that this was increased, though judging by the enlargement of the spleen,* the high colour of the urine, etc., it is more likely to have been increased than diminished.

We repeat, then, that in the present case we have abundant evidence that an increased production of erythrocytes was taking place in the bone-marrow, and in Saundby and Russell's case, though it is stated that the marrow of the femur was normal on naked eye inspection, no microscopic examination was made, and the marrow of other bones seems not to have been examined. It must be remembered, however, that as yet there have been only very few necropsies on cases of this class, and in scarcely any of them has the bone-marrow been examined.

The question arises, What was the cause of the bone-marrow changes in our case? We must acknowledge that such changes may probably sometimes be secondary to circulatory disturbance from heart disease. Thus, in *post-mortem* examinations on two children with congenital pulmonary stenosis and cyanosis, E. Weil † found that there was red transformation of the bone-marrow, sections of which showed that all traces of the normal fatty tissue had disappeared. In our case and similar cases, unlike such "cardiac" cases, we would provisionally regard the changes in the bone-marrow as *primary*, or, if not strictly speaking primary, as representing an *excessive "vital reaction"* to stimulating agents which in ordinary individuals would have hardly been sufficient to excite any reaction at all.‡

Further than this we cannot go with certainty, but it has occurred to us that on one supposition we can account for

* In the cases of persistent cyanosis accompanying chronic tuberculous splenomegaly (case of Rendu and Widal, etc.), it seems possible that the polycythæmia may be partly due to diminished destruction of red cells in the spleen.

† *Soc. de Biologie*, Paris, June 29, 1901, p. 713.

‡ Dr. G. A. Gibson (*Lancet*, 1903, vol. ii, p. 1564) regards the whole symptom-complex as probably due to myocardiac weakness. We of course admit that polycythæmia may occur as a "vital reaction" resulting from imperfect oxidation of the tissues in cardiac disease, etc. If, however, the symptom-complex were in our class of cases really a "vital reaction" of this nature, it would appear to be a vital reaction out of all proportion to the exciting agents. We should therefore be driven to the assumption that the bone-marrow in these patients possessed the (congenital?) peculiarity of altogether excessive reaction towards any exciting agent, or, at least, to any stimulation of its erythrocyte-forming functions. In this connection it may be borne in mind that our patient had formerly always been distinguished by a very ruddy complexion, and that he belonged to a family with similar ruddy complexions.

the association of the chief phenomena constituting the symptom-complex of our own and similar cases. This supposition is that the osmotic tension of the blood of patients with extreme polycythæmia (whether as a result of the polycythæmia * or not) is higher than that of ordinary blood. Although there are many apparent physical objections to this supposition we have determined provisionally to entertain it, for it is only by this means that we can in any way explain the condition of patients of this group.

Further observations on similar cases will show whether our supposition is justified or not. At present we will endeavour to explain the main symptoms on the basis of our supposition. Granting it to be correct, it follows by the laws of osmosis that the blood contained in the vessels tends to give less fluid up to the tissues than normal blood. As a result of this, the small blood-vessels will be habitually distended † and there will be a true condition of "polyhæmia" or blood plethora ‡ as well as of polycythæmia. The spleen will become enlarged, since in a sense it is an elastic reservoir of blood at a pressure approximately that of blood in the capillaries, and, apart from enlargements due to structural diseases, varies in size mainly § according to the pressure of the blood within it.

In spite of the existence of true plethora in the vessels there would, according to the explanation we have proposed, be a tendency for the tissues to be imperfectly supplied with fluid from the capillaries, and consequently to be imperfectly

* However, a rough experiment made by Dr. Weber, with Dr. Lazarus-Barlow's kind assistance by means of his osmometer tubes, seems to show that artificial increase of the proportion of corpuscles in fresh horse's blood (coagulation prevented by the addition of ½ per cent. potassium citrate) rather lowers than raises osmotic tension.

† As we have subsequently shown, the viscosity of the blood is necessarily increased when there is polycythæmia. Hence we must acknowledge that the dilatation of the minute blood-vessels may be equally well explained as being *compensatory* to the increased difficulty in the circulation resulting from the abnormally viscous state of the blood.

‡ In spite of Cohnheim's classical teaching as to the great improbability or impossibility of any persistent true blood plethora (*vide* Cohnheim's *Lectures on General Pathology*, New Sydenham Society's translation, London, 1889, vol. i, p. 424).

§ From this point of view the spleen may be said to act as a manometer of the capillary blood-pressure. In regard to the present question one need not take into consideration the slight rhythmical variations in the volume of the spleen which have been studied by physiologists in animals, and which are doubtless due to the action of the unstriped muscular tissue in the trabeculæ and walls of the blood-vessels and capsule of this organ.

supplied with nutrient material, and with oxygen for combustion. Under such conditions, therefore, the skin and other tissues (in spite of the polyhæmia) would tend to be abnormally dry and rather ill nourished than well nourished, whilst metabolism would tend to be defective.

Similarly, secretions and excretions of the body would tend to be diminished. The daily output of urine would be below the average, and the urine itself probably more highly coloured. The gastro-intestinal secretions would be lessened and thus conditions of chronic constipation and dyspepsia would be favoured. The central nervous system, like the other tissues, would share in the nutritional disturbances, and feelings of prostration, headache, giddiness, and other symptoms might be complained of.

The presence of true plethora, as well as of increased viscosity of the blood (see later section), would tend to throw extra work upon the muscular tissue of the circulatory system and lead to hypertrophy (hypermyotrophy) of the arterial walls and left ventricle.

According to our hypothesis, as we have briefly explained, the vertigo and other nervous symptoms, as well as the scantiness of the urine, the dryness of the skin, the splenomegaly, and the distention of the minute blood-vessels as seen by the ophthalmoscope during life, would all be secondary to the osmotic state of the blood. The cyanosis of the face, ears, hands, and feet, which varies very much in degree at different times, and is apparently apt to be much increased by mental excitement and during attacks of prostration, may perhaps be partly explained as an expression of embarrassment resulting from excessive work thrown on the circulatory organs. It seems to us, however, that, according to our hypothesis, it would also be partly due to the osmotic conditions, if these were caused by the polycythæmia; in fact, we suppose that, granting the existence of such osmotic conditions, there would be an increased tendency for carbonic acid to be carried into the blood-vessels and a diminished tendency for oxygen to be carried from the blood to the tissues in patients of our class of cases as compared to ordinary persons.

Here we must make a short digression in regard to what in a preceding paragraph we said on *increased viscosity of blood*. We have succeeded in experimentally proving that, other conditions being similar, increase in the proportion of corpuscles to blood-plasma does decidedly increase friction in the flow of blood through capillary channels; that is to

say, it raises the "viscosity" of the blood. Professor J. McFadyean kindly provided us with a glass vessel containing 1000 c.c. of fresh horse's blood, in which clotting had been prevented by the addition of 10 grammes of a 50 per cent. aqueous solution of citrate of potassium. The corpuscles were given time to sink to the bottom of the vessel until two distinct strata were formed, a lower opaque red one containing almost only blood-corpuscles and an upper clear yellow one consisting of blood-plasma. It was then easy, by the help of a pipette, to obtain samples suitable for our purpose as follows: (1) a sample of the stratum of blood-plasma (of specific gravity 1025); (2) a sample of the corpuscular stratum; (3) a sample obtained by mixing one part of the corpuscular stratum with three parts of the plasma, the specific gravity of the mixture being about 1040; (4) a sample obtained by mixing one part of the corpuscular stratum with seven of the plasma, the specific gravity being about 1030. By means of a Thoma-Zeiss hæmocytometer it was found that the proportion of red cells in the first mixture (that is No. 3) was four millions per cubic millimetre; therefore the proportion in the other mixture (No. 4) was about two millions to the c,mm.* The four different samples were then compared in regard to viscosity by allowing them to run through a long glass capillary tube (similar to the tubing employed in the stems of thermometers) with a bulb in the upper part (for the pattern for which we are indebted to the kindness of Prof. A. Schuster, F.R.S., of Manchester), the time taken by the upper surface of the liquid to pass from a mark on the glass tube above the bulb to another mark below the bulb being carefully noted in each case. Distilled water took 43 seconds. The blood-plasma (No. 1) took 65½ seconds. The second mixture (No. 4) took 84 seconds. The first mixture (No. 3) took 110 seconds. We did not stop to ascertain the exact time taken by the sample of the corpuscular stratum (No. 2), because it evidently would have taken half-an-hour or longer. The temperature was constant during these experiments, and as the specific gravities of the different fluids were obtainable it would have been possible, as Prof. Schuster† pointed out,

* Professor McFadyean kindly informs us that the normal proportion of red corpuscles in horse's blood is usually given as 7 to 8 millions per cubic millimetre, and that their average diameter is 6 to 7 micro-millimetres (*i. e.* slightly less than that of human red corpuscles).

† He told us that if the time taken in two different liquids be t_1 and t_2 respectively, and p_1 and p_2 be the respective densities of the two liquids, and

to ascertain the coefficient of viscosity of each sample. All we required was, however, to prove, as we succeeded in

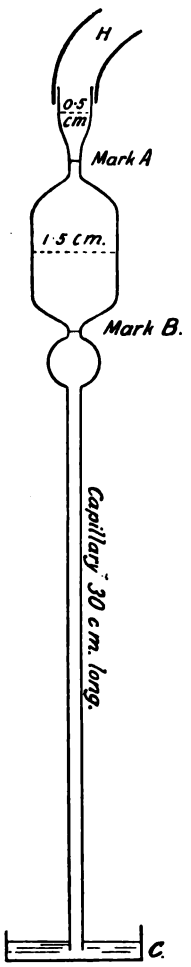

FIG. 4.—The liquid is sucked up from an open vessel, C, by means of an india-rubber tube, H. The liquid is then allowed to fall whilst the tube is kept in a vertical position. The times at which the upper surface of the liquid passes the marks A and B are noted.

n_1 and n_2 their coefficients of viscosity, then $\frac{n_1}{n_2} = \frac{t_1 p_1}{t_2 p_2}$; so that, if for one liquid (as in our case, for water), n_2 is known, n_1 may be calculated out.

doing, that increase of the corpuscular elements was accompanied by a decided rise in the viscosity of the blood.*

It is impossible to say in our case, as in other cases of the same group, precisely when the disease commenced. All we can state is that the cyanosis was noticeable during the last six or seven years of the patient's life. We have good authority for supposing that even before this time he had a markedly ruddy complexion, and that some of his near relatives were like him in this respect. Unfortunately we have not been able to examine the blood of these relatives, as they are not living in England.

Concerning treatment we have very little to suggest. It seems to us, however, that probably one of the most unfortunate things that can happen to a patient is to suffer from any accident temporarily preventing him from taking his usual exercise and the usual amount of fresh air, since deficiency of fresh air and want of exercise must almost certainly lead to diminished destruction of red blood-corpuscles. It is possible that in our patient the diminution of open-air exercise consequent upon the accident and the mental disorder may have had some influence in hastening the end. Injury to bones, such as occurred in our case, might perhaps aggravate the disease (1) by exciting the bone-marrow to increased activity; (2) by rendering rest indoors necessary, and thus diminishing the destruction of red blood-corpuscles.†

Venesection does not seem, according to our views, to be likely to do any good, unless in association with the introduction of normal saline solution to dilute the circulating blood. Such patients ought probably to be supplied with as great

* It follows that conditions of polycythæmia and oligocythæmia (whether absolute or relative) have some importance in regard to indications for venesection and for injections of normal salt solution (subcutaneous or intravenous). When we made these experiments we did not know of those of Jacoby, an abstract of which is given in the *Deut. Med. Wochenschrift* for February 21, 1901. By employing leech extract, or else by defibrinating blood to prevent coagulation, and by the aid of the centrifugal machine, he was able to study the influence of the proportion of corpuscles on the viscosity of the blood. He found that the viscosity was far more influenced by the proportion of corpuscles than by gummy (viscous) substances in the blood-plasma, and still more so than by the amount of salts, etc., present. By increase of corpuscles the viscosity of the blood was raised, and the excretion of urine slightly diminished, though the blood-pressure became slightly higher and the pulse-frequency remained the same. The bearing of Jacoby's experiments on the explanation of the present case is obvious.

† In this connection it may also be remembered that the patient suffered from a hæmorrhage (? from the stomach) five years before his death, and that any severe hæmorrhage may be regarded as a possible exciting or aggravating factor in the ætiology of bone-marrow diseases.

abundance of fresh air as patients suffering from pulmonary tuberculosis. Any food or drug such as iron-containing medicines,* known specially to excite the erythrocyte-forming functions of the bone-marrow, or coal tar products, such as acetanilide ("antifebrin"), known to cause cyanosis,† should, of course, be specially avoided.

ADDENDUM (June, 1904).

If, as H. Ribbert believes (*Centralblatt für allg. Pathologie*, Jena, 1904, vol. xv, No. 9), there is a form of "myeloma," that is to say, of growth originating in the bone marrow, which should be termed "erythroblastoma," because the tumour-cells are allied to erythroblasts (*i. e.* derived from the embryonal ancestors of erythroblasts), it seems to us not unlikely that cases of *polycythæmia with splenomegaly*, such as our case, bear a relation to cases of erythroblastoma similar to that which the various forms of leukæmia bear to the various forms of "myelogenic pseudoleukæmia," that is to say, to the other (non-erythroblastic) forms of myeloma. (Cf. F. P. Weber, "A Case of Acute Leukæmia, with a Scheme of Classification of Leukæmias and Pseudo-Leukæmias," *Trans. Path. Soc. London*, 1903, vol. liv, p. 286.)

LITERATURE.

(We have included references to some cases of enlargement of the spleen due to tuberculosis, in which chronic cyanosis constituted a prominent clinical feature.)

XAVIER BENDER, "La Tuberculose de la Rate (Revue Générale)," *Gazette des Hôpitaux*, Paris, March 31, 1900, p. 375.

* We regret that after the patient's death a quantitative estimation of the iron in the blood and various tissues was not undertaken.

† Osler (*Brit. Med. Journ.*, Jan. 16, 1904, p. 121) refers to a woman sent to him by Dr. W. P. Platt, with obscure cyanosis of two years' duration, but without enlargement of the spleen or polycythæmia. It was ascertained that she had been in the habit of taking a quack medicine containing acetanilide. In Stengel and White's case of chronic acetanilide poisoning there was great cyanosis, and the spleen could be felt two inches below the ribs. In spite of the cyanosis the number of red blood cells did not exceed three millions per cubic millimeter, but the relative abundance of erythroblasts was remarkable. It seems to us, therefore, that in such cases of chronic acetanilide poisoning increased destruction of erythrocytes accompanies increased production. It may here be noted that chronic carbon monoxide poisoning may lead to polycythæmia with relative or absolute hæmoglobin deficiency (von Jaksch in Nothnagel's *Handbuch der spec. Path. und Ther.*, vol. i, p. 257, and G. Reinhold in *Muenchener med. Wochenschr.*, 1904, No. 17, p. 739).

R. Breuer, *Wiener Ges. für inn. Med.*, 1903; quoted by W. Türk.

R. C. Cabot, "A Case of Chronic Cyanosis without Discoverable Cause, ending in Cerebral Hæmorrhage," *Boston Med. and Surg. Journ.*, December 7, 1899, p. 574; "A Second Case of Chronic Cyanosis without Assignable Cause," *ibid.*, March 15, 1900, p. 275.

Collet and Gallavardin, "Tuberculose massive primitive de la Rate," *Arch. de Med. Exp. et d'Anat. Path.*, Paris, 1901, vol. xiii, p. 191.

J. Collins, "Chronic Cyanosis of the Extremities associated with Polycythæmia and Splenomegaly," *Medical Record*, New York, November 21, 1903, p. 807.

V. Cominotti, "Hyperglobulie und Splenomegalie," *Wiener Klin. Wochenschrift*, 1900, No. 39, p. 881.

G. A. Gibson, "Adaptation and Compensation," *Lancet*, December 5th, 1903, p. 1560.

J. N. Hall, of Denver, "Chronic Cyanotic Polycythæmia, with Notes upon Two Cases," *American Medicine*, Philadelphia, June 27, 1903, p. 1026; quoted by J. Collins.

S. F. McKeen, "A Case of Marked Cyanosis, difficult to explain," *Boston Med. and Surg. Journ.*, June 20, 1901, p. 610.

R. Moutard-Martin and Lefas, "Tuberculose primitive et massive de la Rate," *Bulletins de la Soc. Médicale des Hôpitaux*, Paris, 1899, p. 547.

W. Osler, "Chronic Cyanosis, with Polycythæmia and Enlarged Spleen: a New Clinical Entity," *American Journ. Med. Science*, August, 1903; also "Chronic Cyanotic Polycythæmia with Enlarged Spleen," *British Medical Journal*, 1904, vol. i, p. 121.

P. Quiserne, "Des Polyglobulies," Paris Thesis, 1902.

Rendu and Widal, "Splénomégalie tuberculeuse sans leucémie avec hyperglobulie et cyanose," *Bulletins de la Soc. Médicale des Hôpitaux*, Paris, 1899, p. 528.

J. Rosengart, "Milztumor und Hyperglobulie," *Mitteilungen aus den Grenzgebieten der Medizin und Chirurgie*, Jena, 1903, vol. xi, p. 495.

Saundby and Russell, "An Unexplained Condition of Chronic Cyanosis, with the Report of a Case," *Lancet*, 1902 vol. i, p. 515.

J. Scharold, "Ein Fall von substantiver acuter Miliartuberculose der Milz," *Aerztliches Intelligenzblatt*, Munich, 1883, vol. xxx, p. 352.

A. Stengel and C. Y. White, "A Report of a Case of Chronic Acetanilide Poisoning, with Marked Alterations in the

Blood," *University of Pennsylvania Medical Bulletin*, Philadelphia, February, 1903, p. 462.

D. D. STEWART, "Acute Splenic Miliary Tuberculosis," *Trans. Assoc. Amer. Physicians*, Philadelphia, 1901, vol. xvi, p. 431.

W. TÜRK, of Vienna, "Beiträge zur Kenntnis des Symptomenbildes: Polycythämie mit Milztumor und Zyanose," *Wiener Klinische Wochenschrift*, 1904, Nos. 6 and 7; also *Wiener Ges. für inn. Med.*, 1902 and 1903.

H. VAQUEZ, "Hyperglobulie et Splénomégalie," *Bulletins de la Soc. Médicale des Hôpitaux*, Paris, 1899, p. 579; also "Sur une Forme spéciale de Cyanose s'accompagnant d'Hyperglobulie excessive et persistante," *Comptes rendus de la Société de Biologie*, Paris, May 7, 1892. A supplementary note (*Société Médicale des Hôpitaux*, Paris, January 25, 1895) described the existence of splenomegaly and the absence of cardiac lesion in Vaquez's case. Chronic polycythæmia with enlarged spleen might, therefore, almost be called "Maladie de Vaquez."

E. WEIL, "Note sur les organes hématopoiétiques et l'hématopoièse dans la cyanose congenitale," *Société de Biologie*, Paris, June 29, 1901, p. 713.

XX.—*Intra-cranial Resection of the Second Division of the Fifth Nerve for Epileptiform Neuralgia.* By J. Hutchinson, Jun. *Read March* 11, 1904.

SOME three years ago, in a paper on "Excision of the Gasserian Ganglion," I advanced the proposal "that the so-called excision of Meckel's ganglion (always a very difficult and uncertain proceeding, involving disfigurement of the face) should be given up in favour of intra-cranial division of the superior maxillary trunk, just above the foramen rotundum."*

The recommendation was based on the following considerations:

1. The more central the operation, the nearer to the brain, the more certain is the prospect of permanent cure. In almost every case of peripheral operation, including removal of Meckel's ganglion, the neuralgia has returned after an interval of a few months or years.

2. The surgeon who works through the walls of the antrum to the pterygo-maxillary fossa is greatly hampered by the depth of the wound and by hæmorrhage from the internal maxillary artery. He may be successful in defining the trunk of the superior maxillary nerve in the upper part of the fossa, but he is very likely to fail.

3. A depressed scar in the middle of the cheek is much more disfiguring than one hidden by the scalp in the temporal region.

In the middle fossa of the skull the whole of the superior maxillary trunk, before it has given off any branches, can be exposed. Here it can be not only divided but a considerable portion of it can be excised, so that there will be no chance of subsequent union.

The amount of the nerve available at this point for excision varies somewhat in different subjects, but from one-third to half an inch can be resected.

The accompanying figure will make this plain; the trunk

* *Medical Society's Transactions*, vol. xxiii.

should be divided just at the foramen rotundum, and again where it leaves the Gasserian ganglion, as shown at A. B.

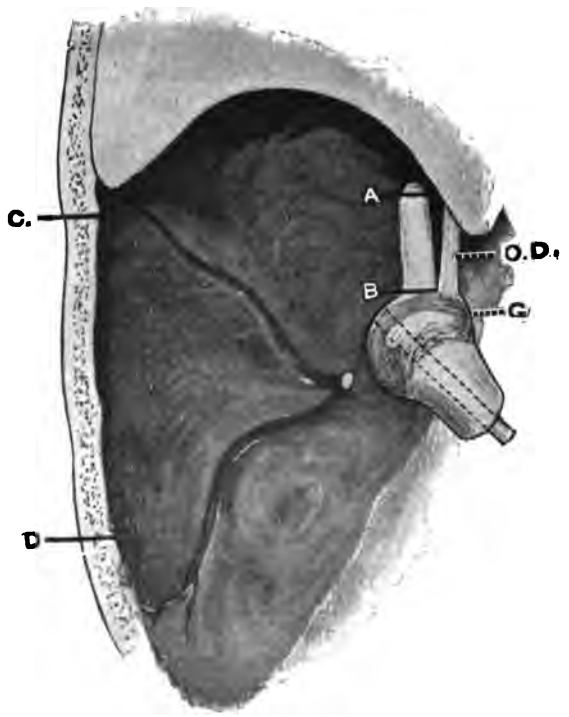

FIG. 5.—Middle fossa of skull. A.B. The superior maxillary division showing the part excised. G. The Gasserian ganglion. O.D. Ophthalmic division. C.D. Wall of temporal fossa, the part between the two lines is resected in order to give access to the nerve.

Cases in which such an operation is justified are not numerous, and it was only about a year ago that one presented itself to me.

A ship's officer, nearly 60 years old, but of fine constitution, had suffered for several years from intense pain in the right cheek and upper jaw. The neuralgia was typically epileptiform, the attacks becoming more and more frequent during the last four years. He had had a number of teeth removed without the slightest relief, and medicines were equally unavailing. He struggled on with his duties on board a Cape liner, and about Christmas, 1902, he consulted Sir Frede-

rick Treves with regard to operative measures, who kindly sent him to me with a note suggesting removal of Meckel's ganglion and the infra-orbital nerve. The distribution of the neuralgia was always the same, and the parts were very tender, though during an attack some relief was obtained by the patient violently grasping the tissues of the cheek. The lower eyelid, both sides of the cheek, the palate and the gums on the right side formed the area involved. Lacrimation and congestion of the right eye were frequent.

It might be suggested that exposure on deck to wind and wet was a predisposing cause of the neuralgia, but the attacks were equally severe when he was on land, and they occurred both by day and night. He had the aspect of great suffering and depression.

My friend Mr. T. Crisp English assisted me at the operation, which was performed with the patient fixed in a dentist's chair in order to lessen the trouble from venous hæmorrhage. A horse-shoe flap was turned down from the temporal region, having its base at the zygoma, the flap including part of the temporal muscle and the pericranium. With a large trephine and cutting forceps the subjacent bone was removed and the dura mater exposed. As in the operation for removal of the Gasserian ganglion, the dura mater and temporo-sphenoidal lobe were then carefully pushed upwards and inwards, making for the foramen rotundum as the first land-mark. (In this respect the two operations differ, as in dealing with the Gasserian ganglion the foramina spinosum and ovale are first sought for.) Considerable difficulty was met with, owing to the thin and fragile character of the dura mater, and some cerebro-spinal fluid escaped. Ultimately the trunk of the superior maxillary division and part of the Gasserian ganglion were thoroughly exposed, a broad spatula of soft metal being used to retract the dura mater and brain. The whole of the nerve was then removed; a small drain was subsequently inserted, and the flap sutured in position. None of the bone removed was replaced. Primary healing followed, and no complication of any sort occurred. The patient a month later returned to his duties, and has made regular voyages to and from the Cape ever since. I have waited twelve months before reporting the case in order to ascertain that the relief is permanent, and am glad to state that he has not had the slightest recurrence. The anæsthesia is most marked over the cheek and right superior maxillary bone; it involves also the soft palate and lower eyelid. He

can eat and talk with perfect comfort, whereas before the operation both acts brought on spasmodic pain. The scar is hardly to be noticed, the gap in the bone has practically filled up, and there is, of course, no paralysis of masticatory muscles on that side such as follows removal of the Gasserian ganglion.

I am confident that no recurrence is likely to take place.

It would be erroneous to suppose that the operation is an easy one, the depth of the nerve-trunk (3 centimetres or more from the wall of the temporal fossa) and the troublesome oozing in a narrow space where it is essential to see and define a nerve-trunk of small size prevent this. But having had the opportunity of assisting my colleague, Sir Frederick Treves, in several operations on Meckel's ganglion, I can safely assert that the intra-cranial route is at least as easy as the facial one, and I believe it affords the more certain access.

It will be remembered that the superior maxillary nerve, immediately on entering the pterygo-maxillary fossa, gives descending branches to the palate and bone with internal branches to the cavity of the nose. It is easy to follow up and remove the infra-orbital nerve from in front, but very difficult to remove the trunk and all its branches in the fossa. Moreover, even if this is accomplished, the evidence is strong that recurrence of the neuralgia is only a matter of time. In Sir F. Treves' five cases it recurred within twelve months in two, a third patient died (of cancer) within six months of the operation; in the remaining cases recurrence was observed in two and three years respectively.

Mr. Chavasse collected twenty-two cases of what is often termed Carnochan's operation; in only three was the relief stated to be lasting.

With regard to operations on the Gasserian ganglion, properly carried out (this may be emphasised without going into details here) the evidence is conclusive that the neuralgia is permanently cured.

There are other methods of approaching the superior maxillary trunk, which I venture to think compare most unfavourably with the temporal route. In Professor Lücke's operation the masseter muscle is divided, the zygoma cut through, and an extensive scar left on the side of the face. The zygoma may not unite again, and movements of the lower jaw may be much interfered with.

Nussbaum and Billroth employed osteo-plastic resection of

upper jaw, Kocher and others' methods involving temporary resection of the outer orbital wall. Not one of these methods or their modifications afford access to the trunk where it comes off from the Gasserian ganglion. In Sir F. Treves' words, "These various measures are all needlessly severe, and involve wounds of great and unnecessary magnitude."

It is well known that in cases of epileptiform neuralgia of the fifth nerve one, two, or all three divisions of the nerve may be involved. In some patients the pain is mainly limited to one division, usually the inferior or the superior maxillary, with radiations into the ophthalmic branches or even the cervical plexus.

Experience has shown that a thorough operation on the central part primarily involved will almost always cure the lesser and more widely distributed neuralgia. Supposing the inferior maxillary division to be alone or mainly affected, it is open to question whether an intra-cranial removal of the lower part of the ganglion and inferior maxillary trunk would not be preferable to the elaborate operations usually performed below the foramen ovale. The conditions here are not so favourable, however, as exist in the superior maxillary trunk, where about half an inch of the nerve can be exposed and removed.

Codivilla, an Italian surgeon, has performed this operation twice with success. His first case was in 1897.

When both second and third divisions are mainly involved I am sure that removal of the lower half of the ganglion, leaving the ophthalmic division intact, is the best operation. As a series of cases have shown, going back from two to seven years, no recurrence of neuralgia need be feared in the ophthalmic part that has been left intact. But where the superior maxillary division alone is concerned the operation described may be advocated in preference either to Carnochan's method or the more complete operation on the Gasserian ganglion itself.

[Note.—When the foregoing paper was read at the meeting of the Clinical Society Mr. Stanley Boyd related a case in which he had, about the same time as myself, performed intra-cranial resection of the second division of the fifth nerve for epileptiform neuralgia limited to that distribution. The result had been complete relief for about a year, at the end of which time slight neuralgia was again reported, though its localisation was uncertain.]

XXI.—*Foreign Body impacted in Bronchus; Removal by Operation.* By W. Pasteur, M.D., and T. H. Kellock. *Read March* 11, 1904.

L. J., æt. 5, schoolboy, was admitted into the Middlesex Hospital on September 28 with the following history:

On September 23 he brought home a small glass stopper, which he had picked up in the street, and showed it to his mother. A few minutes later the father called her back to the room, which she had just left, to find the child lying on the floor "fighting for his breath." His face and lips were blue and his eyes "starting." Guessing that he had swallowed the stopper she picked him up by the heels and shook him violently, with marked relief to his symptoms; but the stopper did not reappear. He was at once brought to the hospital, X-rayed with a negative result, and as he was then breathing quite quietly allowed to go home again.

On the 27th he was seen by a local practitioner who discovered physical signs at the apex of the left lung, which he attributed to impaction of the glass stopper in the bronchus leading to the upper lobe.

On admission the boy looked ill. Temp. 102·8°; complexion pale and slightly dusky; resp. 36 per minute, but not laboured. Alæ nasi move slightly. No stridor during ordinary breathing; but with cough or deep breathing there is a stridulous wheezing sound. Cough is loud, inclined to be brassy at times, and decidedly paroxysmal. Pulse 110. Urine normal.

On examining the chest there is marked loss of movement on the left side, which feels smaller than the right.

The heart's apex beat is in the fifth interspace in the nipple line.

The percussion note is a trifle short over the left upper lobe, but there is no dulness. Vocal fremitus is impaired over the left front as low as the level of the fourth rib, and behind in the supra-scapular region, and part of the inter-scapular region.

The breath-sounds are very weak all over the left upper lobe, and have entirely lost the vesicular quality. The breathing is also much weaker than normal over the left

base, but more audible than over the apex. The voice-sounds are audible, but weak and distant all over the left chest. With the exception of an occasional rhonchus there are no adventitious sounds.

The right lung is healthy.

I first saw the child on October 1, and at once asked Mr. Kellock to see him with me. He recognised the boy as having been under his care a few months before for an injury to the hand. At that time he was healthy and robust-looking, and Mr. Kellock was much struck with the change in his appearance.

The child was again examined with the screen when it was noticed that there was practically no movement of the ribs on the left side in respiration. We were unable to see anything in the region of the left bronchus, but Mr. Lyster fancied he could detect a faint shadow in that situation.

We agreed that, in the face of such a definite history, and with physical signs so pointedly suggesting obstruction of the left bronchus, an attempt to relieve the condition by operation should at once be made, the more so that the oscillating temperature and serious illness of the child made it probable that local inflammation and suppuration were taking place.

Operation was immediately proceeded with.

Chloroform having been administered the trachea was opened below the isthmus of the thyroid, three of the cartilaginous rings being divided. As soon as air entered through the wound the child coughed a little, but expelled nothing. On passing a probe downwards and into the left bronchus a foreign body was distinctly felt, and on measuring the distance it was found to be about three and a half inches from the lowest part of the opening in the trachea. Attempts were made to dislodge it by means of the probe, but they were unsuccessful, as was also an attempt to grasp it by means of long forceps. A piece of silver wire twisted into a loop at the end was then tried, passed down to the foreign body, and rotated; whilst this was being done the child rather suddenly coughed up about one drachm of thick pus. On the next attempt the wire evidently got beyond the foreign body and dislodged it, for it was seen with a good deal of mucus to emerge from the wound for an instant, but was sucked backed again with the next inspiration. Fortunately it was found on examination to have returned to its original situation. A rather stiffer loop of wire was passed

down to and beyond it, on withdrawing which the glass stopper was delivered through the wound.

The pus and mucus having been thoroughly cleaned away from the wound the opening in the trachea was closed by fine silk sutures passed through the intervals between the cartilaginous rings, but not entering the lumen; the muscles were brought together by one or two fine silk stitches, a small drainage-tube put in the lower angle of the wound reaching nearly to the sutured trachea, and the skin wound closed round this by means of interrupted horse-hair sutures. A light dressing was applied, and the child, who had borne the operation very well, sent back to the ward.

FIG. 6.

The neck was dressed on the second day, and the drainage-tube removed; there had been very little discharge through it, and the upper part of the wound had practically healed. Five days later, the wound having quite closed over, a little fulness was noticed at the lower part; this was reopened with a probe and a few drops of pus let out, and complete healing took place a day or two after this. There was never any escape of air through the wound.

There was a marked diminution of symptoms from the time of operation onwards. The temperature, which before operation had been high and irregular, fell at once, and remained normal. The cough immediately lost its paroxysmal character, but persisted for several days. The condition of the lung rapidly improved, and beyond slight impairment of movement the physical signs were practically those of health by the end of the fourth day. There was a striking change in the child's colour and general condition, and he continued to make good progress up to the date of his discharge on October 26.

Remarks.—The features of interest in this case are mainly surgical. We were fortunate in obtaining so definite a history that there could be no reasonable doubt as to the cause of the obstruction. The X-ray screen examination only gave an indefinite shadow in the region of the left bronchus. After removal the stopper was found by Mr. Lyster to offer a resistance to the X-rays equal to 9 cm. aluminium, which would only give an indefinite shadow through the thorax of a child about this age.

Measurements taken at the time of the operation, and subsequently applied to the trachea of a child of about the

same age, showed that the foreign body must have been lodged just at the bifurcation of the left bronchus.

It is worthy of note that a foreign body, such as was found in this case, should have given rise to the formation of an appreciable amount of pus in the course of a few days. Septic changes would not have been surprising had it been an organic body capable of decomposition, or of such irregularity of surface as to be likely to cause ulceration.

From the absence of blood in the pus that was liberated, and the rapidity of recovery, we conclude that the pus in this case had been pent up in one of the larger bronchial tubes rather than in a cavity caused by ulceration.

The operation itself calls for little comment. It was evident that we had to deal with a foreign body impacted in the bronchus, and there was so little likelihood of its being coughed up on opening the trachea that an opening as low as possible seemed desirable. On ascertaining that the body was lying some way down the left bronchus, and after an unsuccessful attempt to reach it with tracheal forceps, these were abandoned in favour of a twisted loop of wire similar to that successfully used by Mr. Kellock in a previous case for the removal of an impacted haricot bean in the left bronchus. The modern plan of completely closing the trachea by sutures was attended with complete success.

XXII.—*Two Cases of Intestinal Obstruction immediately following an attack of Typhoid Fever.* By E. W. Goodall, M.D. *Read March* 25, 1904.

Case 1.—Henry L., æt. 14, was admitted to the Eastern Hospital on September 3, 1903, with typhoid fever. The illness dated from August 9, so that he had been ill between three and four weeks. It was stated that he had complained of severe abdominal pain on the day of admission, but this had almost passed off before he reached the hospital. On admission no definite signs of typhoid fever were to be found. The boy looked ill, was thin, and somewhat wasted. The temperature was subnormal; pulse 106; resp. 44. There were signs of moderate bronchitis, and there was a troublesome cough. The abdomen was a little retracted and firm without exactly being rigid; there was no abnormal dulness, and the hepatic dulness reached from the sixth rib to the costal margin in the nipple line. The patient complained of pain in the abdomen while it was being percussed. He was very deficient in intellect, and could neither read nor write. He was given to making a good deal of whining noise at times, especially when he was touched, so that all through his illness it was difficult to be certain of the localisation or even the existence of pain. The tongue was clean and moist. The blood serum gave a positive reaction with a 1 in 60 dilution; on the strength of this and the history of the case I concluded that the patient had just passed through an attack of typhoid fever of moderate severity. During the first two days after admission the patient was noisy at night; the temperature was raised on the evenings of the 5th and 6th, and on the latter day it was noted that the abdomen was painful when percussed and rather more retracted than on admission. The bowels were moved by an enema on the 5th. On the 7th a swelling was observed on the upper jaw on the right side; an alveolar abscess formed, and was opened on the 10th. On the 9th of September the temperature had risen again, and this proved to be the commencement of a relapse of moderate severity which lasted till September 25. The chief symptoms of this relapse were continued pyrexia and some looseness of the bowels. It was noted, however, that the abdomen remained rigid though without

pain. The patient at times passed his excreta under him; he did this occasionally all through his illness; the fact was probably accounted for by his mental condition.

On September 25, just at the end of the relapse, the patient twice vomited bile, and he was also troubled with hiccough. Next day the following note was made:—"Hiccough has continued since 4 P.M. yesterday; occasional, not when patient is asleep; he has attacks every fifteen minutes, which continue for ten minutes; he vomited last night; temperature subnormal; pulse small and compressible, 104; nothing wrong with the heart and lungs; the abdomen is rigid; there is some intestinal distension; there is no localised pain, but it is difficult to examine the patient, as he whines and cries on being touched; liver dulness normal; he slept well last night; he complains of feeling sick, and takes food very unwillingly; no albuminuria." He was put on a mixture containing bismuth and dilute hydrocyanic acid, and brandy, and nourishment was given by means of enemata. The next day he was better; there was no more vomiting and less hiccough. On the 28th the hiccough had ceased; there had been no more vomiting; the pulse was good, the tongue clean and moist. The nutrient enemata were discontinued, and milk and barley water given by the mouth. From September 28 to October 3 the temperature occasionally rose to 100° F. The patient continued to do well; he was allowed bread and butter on September 29, fish on October 5, and rice pudding on the 10th. The bowels were moved by soap and water enemata. There were no fresh symptoms till October 18, when the temperature rose in the morning to 102°, and the patient complained of severe pain in the legs. Although the patient had recently been taking his nourishment very well, yet he had got very thin indeed. The excreta were all passed under him. He was put back on liquid food. On October 19 some typhoid spots appeared on the chest and abdomen, and more came out during the next two days. There was irregular pyrexia till October 29; there was, in short, another slight relapse. During this relapse there were no abdominal symptoms, except that the abdomen was retracted. On November 1 the patient was allowed a little bread, butter, and fish, and was doing very well when, on November 9, during the forenoon, he complained of pain in the abdomen. At noon the abdomen was found to be a little full, it having previously been retracted; it was also tender; there was no rigidity; there was some

gurgling on the left side; the liver dulness was normal. The bowels had been opened twice on the previous day and once that morning, the stools being brown and formed. Hot fomentations were applied to the abdomen, and whey ordered instead of the diet the patient was having. In the afternoon he vomited three or four times; the pulse became intermittent, and in the evening there was hiccough; temperature subnormal.

November 10 (11.30 A.M.).—"Patient has been hiccoughing on and off since last evening; there has been retching, but no more vomiting; heart beating at 180 per minute; pulse very feeble, not intermittent; still some abdominal pain and tenderness; patient is very cold."

10.30 P.M.—"Has not vomited; has retained whey and brandy given by the mouth; occasional hiccough; patient is very thirsty."

November 11 (1 A.M.).—"Vomiting commenced again; nourishment by the mouth omitted, and nutrient enemata given instead, but the patient continued to vomit frequently, and the enemata were not retained. He died at 6 P.M. the same day. The temperature remained subnormal to the end."

A *post-mortem* examination was made at 6 P.M. on November 12. The body was much emaciated. The abdomen was not at all distended. On opening the abdominal cavity it at first appeared as if the organs were normal. The intestines that came into view were moderately distended. There was no peritonitis to be seen, but on moving the intestines some local peritonitis was found in the right iliac region over about a foot of small intestine, intense injection with some flakes of lymph. There was no perforation and no pus. On making further examination it was found that the foot of intestine mentioned above was constricted by a band in the following manner (see the adjoining diagram):—The band *a* stretched from the mesentery *b* to a portion of small intestine *c*, to which it was firmly adherent; it passed over and constricted another portion of intestine *d*, to which it was also adherent a little, though not so firmly as it was to *c*. This band consisted of strands of fibrous tissue, and was not so thick in proportion as represented in the diagram; it was about one and a half inches long, and was rather thin. On the pelvic side of the band there was about one foot of intestine, that between the two portions to which the band was adherent (shown by dotted lines in the diagram). This was the

portion of small intestine referred to above as being highly injected and having small flakes of lymph upon it; it was not at all gangrenous. This loop, and all the intestine down to the ileo-cæcal valve, and the whole of the large intestine were contracted, but not quite empty, as here and there in the large intestine was a small mass of putty-like fæces. Above the band the small intestine was distended compared with what it was lower down; still, it was only moderately distended. There was a sort of fossa (marked xxxx in the diagram) in the right iliac region, bounded on the right by the omentum, which ran down and was adherent by mode-

Fig. 7.

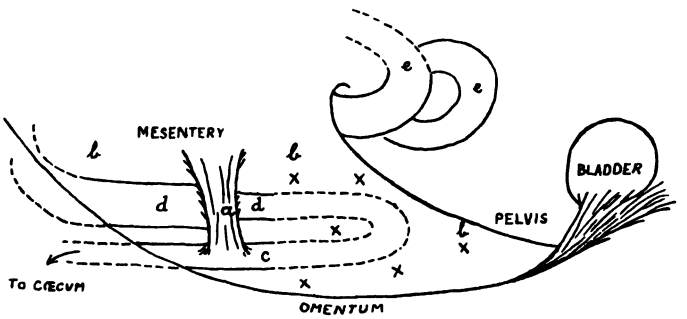

rately firm adhesions to the anterior part of the brim of the pelvis and slightly to the top of the bladder, and on the left and below by the mesentery, which ran downwards in a very definite ridge or band along the right brim of the pelvis. In the fossa xxxx lay the empty foot of small intestine, huddled up, and prevented from falling into the pelvis by the convergence of the mesentery and omentum. On taking out and cutting open the small intestine I found that at *d* the bowel was half twisted upon itself in a manner which is not shown in the diagram. The mesentery of the piece of bowel *d* was not quite close to that portion of the mesentery to which the band was attached. The pelvis was partly occupied by other loops of small intestine *e, e*.

The small intestine was ulcerated in its lowest four feet. The part *d* was found to be two and a half feet from the valve. Many Peyer's patches and solitary follicles were affected. The lowest three inches, together with the valve

itself, were extremely ulcerated. There were no sloughs; all the ulcers were quite clean, and were, in fact, commencing to heal, the edges being rounded off, and several of the upper ones showing minute granulations on the floor. Two or three of the lower ones had very thin floors, which tore through on removing the bowels; in fact, in these the floor consisted of little more than peritoneum. For about three inches of the slightly distended gut just above the point *d* there was an irregular, superficial erosion of the mucous membrane, which I thought was probably due to distension. In the lower two feet the ulcers were of a slatey grey colour. The points of attachment of the band at *d* and *c* were opposite the bases of ulcers, which had evidently been rather deep. The adhesions were not very recent; they could be separated with a little care; they might very well have been formed during the primary attack the patient had before admission. The peritoneal surface of two or three of the other ulcers in the loop *d* to *c* also presented evidence of not very recent peritonitis. There were a few ulcerated follicles in the ascending and transverse colon. With the exception of extensive old adhesions over the whole of the left lung all the other organs were normal.

Case 2.—R. C., a young man 22 years of age, was admitted to the Eastern Hospital on November 6, 1903, on about the tenth day of a moderately severe attack of typhoid fever. There is no particular observation to make concerning his illness, except that a few small clots of blood were passed in the stools on November 13, till November 16, about the twentieth day of the attack, when at 9.15 A.M. the patient looked in pain, and, on being questioned, complained of "wind and pain low down in the stomach." At 10.15 A.M. he was pale, sweating, and collapsed; the pulse was rapid, small, and compressible; the abdomen was slightly rigid and immobile; there was tenderness in the right iliac region; the liver dulness was normal. Perforation was diagnosed, but as the patient's friends had to be communicated with, it was not till 1 P.M. that an operation was commenced. The abdomen was opened by my colleague, Dr. Whitaker, by an incision in the right iliac region, just to the inner side of the linea semilunaris. The intestines were found to be slightly injected, and there was some inoffensive fluid in the peritoneal cavity. It took several minutes to find the perforation, which was in the small intestine, though how far from the

ileo-cæcal valve was not ascertained. The perforation was of moderate size, and a small slough was projecting through it. There was just a little lymph on the bowel immediately round the perforation. The perforation was invaginated by six Lembert's sutures of silk, and a glass drainage tube having been inserted, the abdominal wall was sewn up in one layer with silkworm gut. The patient did not take the anæsthetic very well (gas, ether, and chloroform), and vomited several times after he had recovered consciousness. During the next day or two the abdomen became rather distended, with the result that some of the stitches gave way and the wound gaped, but otherwise the patient's condition, local and general, remained satisfactory. On the 22nd the glass was replaced by an india-rubber tube. On the 24th a small slough was observed in the wound, but the abdomen was flat and supple. Three of the stitches were removed. On the 26th the temperature, which since the operation had been mostly normal, rose to 101°, and the tongue was a little furred. In spite of the fact that the temperature continued to go up several degrees every evening, usually falling to normal in the morning, the patient remained in a satisfactory condition; but it was thought he might be about to have a relapse. On the 28th the drainage tube was removed. No bad sign occurred till 12.30 A.M. on December 1, when the patient vomited two or three minutes after taking a little whey; there was no abdominal pain, and he appeared to be comfortable. The pulse was 118, the temperature about 99°. The bowels had been opened by a glycerine enema on the previous day, a formed motion having been passed. At 11 A.M. the same day the following note was made:—"Between midnight and 9.30 A.M. the patient vomited six times; the pulse, though small and readily compressible, is steady and slow; the temperature, both axillary and rectal, has dropped to 96°; hands and face warm, but nose cold; colour good; patient is quite bright and conscious; the bowels have not been opened, but wind has been passed both by rectum and mouth; wound dressed, looking quite healthy; abdomen quite flat; no distension; moves readily; no tenderness; liver dulness normal." Nothing more was allowed by the mouth, and at 4 P.M. rectal feeding was commenced.

During the next four days the patient gradually got a little worse; there was occasional scanty bilious vomiting; flatus was passed by the mouth and rectum; the abdomen became distended, and the wound gaped; the tongue became

furred and dry; the temperature rose to about 101° in the evening. On December 3 he was allowed a little whey by the mouth; on the 4th the nutrient enemata were omitted, but they were resumed on the 5th. On the 6th the vomit was dark, and had a fæcal odour; a glycerine enema produced a large yellow, formed stool; no flatus was now passed by the rectum: a long tube was ordered to be passed into the rectum night and morning. On the 7th a soap and water enema produced a fair result; the patient vomited at 6.30 A.M.; he also complained of abdominal pain; the wound, though gaping, looked healthy; the upper part of the abdomen was distended, but the hypogastric region flat; no abdominal pain or tenderness since the morning; a little wind is passed by the mouth, but not by the rectum; temperature normal; pulse fair; general condition fairly good; tongue dry.

At 3 P.M. I was examining the abdomen, and twice within a few minutes I observed peristaltic action in a distended coil of intestine, appearing as a sort of ridge transversely in the upper part of the abdomen, rising slowly, persisting for a short time, and then disappearing. On the second occasion I heard a gurgling sound, and the patient said he had pain in the right iliac region. Later in the evening I had a consultation with Dr. Whitaker, and it was decided that there was some partial obstruction, and that, as the patient was slowly getting worse, the abdomen should be opened again the next morning with a view to ascertaining the cause; there were no urgent symptoms at the time. The patient had a pretty good night, and slept fairly well; he vomited at 9 P.M. At 7 A.M. the next morning he was seized with very severe pain, which did not last very long; but the pain recurred several times in paroxysms up to 8 A.M., when some opium was given. At 9 A.M. the patient was collapsed; the abdominal pain had returned; the abdomen was quite flat; no peristaltic action to be seen; pulse not to be felt at wrist. He never rallied, and died at 10 A.M. During the last three days the temperature varied from 97° to 99·4° and the pulse from 92 to 108, but towards the end the pulse-rate went up to 140.

An examination of the abdominal cavity was made at noon on December 8. The abdomen was not distended. The wound looked healthy, but at the same time did not show any signs of healing; there was no discharge; it gaped considerably. The floor was formed of a thin layer of muscle

covering the peritoneum, to which the omentum was firmly adherent. To the left of the wound, just under the abdominal peritoneum, was a small abscess containing thick, curdy pus. The floor and sides of the abscess were formed by the omentum and small intestines, and the abscess was quite cut off by adhesions from the wound and from the general peritoneal cavity. On enlarging slightly the wound into the abdominal cavity some free gas escaped, and a considerable amount of dark fluid, the escaped contents of the intestine, was found in the pelvis and amongst the coils of intestines. A considerable extent of the upper portion of the small intestine was much distended and injected, while the large and the rest of the small intestines were much contracted. A large number of little bands, formed of peritoneal adhesions, were found stretching between different coils of the contracted intestines. The effect of these bands was to kink some and bind down other coils of small intestine, though in no place did total occlusion of the bowel appear to exist. Three of these bands were especially well marked, of which the highest was the highest band of all, being situated about six feet above the ileo-cæcal valve. The gut above this point was much distended. The largest bands were one to two inches in length, and were composed of fibrous strands, to break which required some force. In a few places also the intestine was bent on itself and fixed in a kink by adhesions. It was subsequently found that many of these bands were attached at one end to the peritoneal aspect of ulcers. Sixteen inches above the junction of the distended and contracted portions of the intestine a minute perforation was found. It was situated at the end of a Peyer's patch, which had healed except just at this end; here the floor was very thin, and had evidently given way under the strain caused by the distension. There was very extensive ulceration of the small intestines from the valve up to the jejunum; the ulcers were all healing, and there were no sloughs and no evidence of a relapse. The sutured ulcer was two feet above the valve; it had not quite healed, but was in a perfectly healthy condition. The bowel was a little narrowed, but not enough to cause any obstruction. The ridge caused by the inversion of the ulcer had entirely disappeared. The outer parts of the sutures were buried in firm, organised lymph.

The spleen was a good deal larger than usual, and very soft. In it were several large recent infarctions. The largest one, which was of the size of a Tangerine orange, had broken

down, and was on the point of rupture. None of the other organs were examined.

Remarks.—I have thought these two cases worthy of record for three reasons. Firstly, they are instances of a very rare sequel of typhoid fever; secondly, they illustrate how peritoneal bands may be formed; and thirdly, they are interesting from the points of view of diagnosis and treatment.

(i) Intestinal obstruction is very rare as a sequel, at any rate as an immediate sequel, of typhoid fever. I have never before met with a case similar to these. It is well known that the healing of the ulcers does not lead to narrowing of the gut, even if scar tissue be formed. And I take it that if peritoneal bands are ever formed during an attack of typhoid fever their results are not shown till so long afterwards that the origin of the bands is not recognised.

(ii) With regard to the second point I think I am justified in concluding that in each of these cases the bands were formed during the attack of typhoid fever.

In the case of the first patient there is a history of abdominal pain just before admission at the end of the primary attack; the pain is present on admission and recurs three days later. Six days after admission a relapse takes place, which lasts for sixteen days, during which the abdomen is noted to be mostly rigid. At the end of this relapse there is an attack of vomiting and hiccough, probably accompanied by pain. This lasts for three days. An interval of twenty days follows, at the end of which is a second relapse of eleven days' duration. Eleven days after this relapse occurs a second attack of vomiting, hiccough, and abdominal pain, with some distension of the abdomen; the heart fails, and the patient dies two days later, about ninety-four days from the commencement of his illness and at least sixty-nine from the first complaint of abdominal pain. I believe the interpretation of the case to be as follows:—In the primary attack there was local peritonitis opposite some of the deepest ulcers; that this will take place we know from the experience of the dead-house. I have also met with it on opening the abdomen for perforation. The *post-mortem* examination showed that some of the ulcers had been deep; and as neither of the relapses were severe it is probable that the deep ulcers dated from the primary attack. The lymph thrown out caused adhesions at the spots shown in the diagram. These adhesions were soft and yielding at first, but slowly became organised into a definite band. At the end of the first relapse this band was

sufficiently formed to give rise to definite symptoms, of the same nature though not of the same severity as those which occurred in the fatal attack. It should further be noted that during the whole time the patient was under observation in hospital the abdomen was never quite normal; it was mostly retracted, at times a little distended, at others rigid. I ascertained, by special inquiry of his father, that the boy had never previously suffered from any abdominal illness.

The second case was an ordinary one of typhoid fever with perforation. It is quite certain that on the twentieth day of the disease there were no bands, because a considerable portion of the intestine was examined before the perforation was found. But after the operation an adhesive peritonitis set in, which did not give rise to any symptoms till fifteen days later; and I take it that at this date the adhesions were beginning to get firmer. Gradually the symptoms became more severe till seven days later the patient died of a second perforation. Two causes may be assigned for the peritonitis which followed the laparotomy and led to the formation of adhesions and bands. It may have been a direct result of the operation, and more or less general; or, as in the first case, the bands may have arisen out of localised patches of peritonitis opposite the bases of ulcers. This view appears to agree best with the arrangement of the bands met with after death, most of them being attached opposite ulcers. From the fact that a slough was found in the perforated ulcer at the operation it is very likely that there were sloughs, perhaps deep, in some of the others, at or about that date.

(iii) Thirdly come the questions of diagnosis and treatment. In the first case I did not diagnose the condition. I had not seen the patient in the first attack of vomiting and hiccough, and I failed to attach sufficient importance to the recorded symptoms of that attack. The patient, too, was a boy of deficient intellect in whom it was very difficult to ascertain the nature and locality of pain. He was certainly not in a fit condition at the time of the second attack to stand any operation, as he was extremely emaciated and weak as a result of his long illness. An exploratory operation was quite out of the question.

The second case gave rise to some trouble in diagnosis at first, with respect I mean to the cause of the vomiting which set in fifteen days after the operation. There was nothing in the condition of the wound to account for the symptoms. It

was not till three or four days after the onset of the vomiting that any abdominal distension took place, and there was no pain till the day before death, and even then the pain was slight and transient. Seeing the peristaltic action in a distended coil of intestine determined me on an exploratory operation, but the patient died before the time fixed for this. As a matter of fact the condition of things found *post-mortem* was quite hopeless. There were too many bands and kinks to be dealt with successfully; and even if the bands had admitted of treatment the rupture of the splenic infarct would almost certainly have speedily led to a fatal termination.

XXIII.—*Severe and Fatal Hæmaturia of Unknown Origin.* By W. G. Spencer. *Read March* 25, 1904.

Case 1. *Rapidly fatal hæmaturia.*—A man, æt. 44, first noticed blood in his urine about a fortnight before his death. He had before this been in good health. He had not suffered in any way. In particular he had had no previous hæmorrhages, and he had not been abroad. The hæmaturia increased, unaccompanied by any symptoms; there was neither pain nor frequency of micturition. He was seen by Dr. Denne, of Brook Green, but the hæmorrhage became so severe that he sent him into the hospital. I saw the patient shortly after his admission. He was then very anæmic, practically pulseless, and breathing very rapidly. The bladder was distended, but not tense nor tender. The temperature was just below normal; there was no skin eruption; indeed, nothing could be made out. He was infused with salt solution, given repeated enemata of water, and stimulated with alcohol and strychnine. He passed urine containing a large proportion of blood, the temperature became subnormal, and he died within twelve hours of admission.

Dr. Hebb, to whom I had spoken of the obscurity of the case, made a complete *post-mortem* examination, without finding anything to throw light on the cause or source of the hæmorrhage. The bladder contained a small quantity of bloody urine, which was not found in the pelvis of either kidney. The kidneys, bladder, and urethra appeared normal; there were no submucous hæmorrhages, nor ulcerations, nor sign of stone. The patient's vessels were not diseased, but in the exsanguine tissues they seemed somewhat thin and translucent.

The following specimens are shown: the bladder, prostate, and urethra; also microscopic specimens of the kidney, wall of the bladder, and a section of the aorta. There is nothing abnormal in any of them, except that in the case of the aorta the section, whilst showing no sign of disease, is, in Dr. Hebb's opinion, distinctly thinner than usual in a subject of the patient's age.

Case 2.—*Recurring hæmaturia, arrested for a time by drainage of the bladder.*—A man of 42 years, a butler, was sent into the hospital by Dr. Bunn, of Norwood, through my then dresser, Dr. Roper. The patient was suffering from recurrent hæmaturia, causing anæmia. A year and a half before, during the night, he awoke feeling full of wind and unable to get his breath. Not then, but in the morning, on getting up, he passed four large clots, and afterwards the urine was for a while bloodstained. Three months later the patient had some pain in the hypogastrium during micturition, and the first part of the urine passed was darkened. For the following ten days there was hæmaturia. At intervals during the course of a year he was treated by Dr. Bunn with internal remedies, then a recurrence of hæmaturia was complicated by retention, necessitating catheterism. He was admitted to Charing Cross Hospital, where the hæmaturia ceased. His bladder was examined under an anæsthetic and also by X rays. The patient was after this told that no operation was indicated. The examination did not provoke hæmaturia; nevertheless, it recurred three days after leaving, with but little pain and no retention. He then went into the country and got stronger. But a month before, and again three days before admission to the Westminster Hospital, he had acute hæmaturia with retention.

His previous history and his family history presented nothing abnormal. He had not taken alcohol to excess, and had not been abroad. He was thin and anæmic. Micturition occurred normally about four times a day without pain. The urine was of a dark port-wine colour, acid, sp. gr. 1030, the albumen was not in excess of the blood, no sugar, and microscopically it contained nothing beyond the blood. Whilst in bed the patient sometimes passed large clots, which delayed the commencement of micturition, and once or twice he passed his catheter. No fine clots, such as come from the ureter, were to be seen. Whilst under observation the wasting and anæmia slightly increased.

Supra-pubic cystotomy was performed about eighteen months from the commencement of the disease. The bladder was filled with dark bloody urine, and there was some sediment. After washing this away nothing further was discovered. The wall of the bladder and also the prostate were normal, and the interior of the bladder showed no tendency to bleed as a result of the manipulations. Clear urine was seen coming rom the ureters, and when a vaginal speculum was pressed

down over each urethral orifice in turn only clear urine collected at the bottom. No blood nor clot came out from the urethra when a catheter was passed through the penis into the bladder. The supra-pubic wound was drained for a week. After three weeks quite normal urine was passed entirely by the urethra. A year later the patient had had no recurrence of the hæmaturia, but had one day passed a small phosphatic concretion. In a recent letter to Dr. Bunn the patient says he has had some recurrence of the hæmaturia without other symptoms.

Remarks.—Cases of hæmaturia unaccompanied by lesions have been referred to by Osler, who mentions Gull's term "renal epistaxis." So far as the evidence goes the foregoing two cases appear not to have been renal in origin. Epistaxis implies "dripping," and its origin in the nose is now for the most part known, whereas the hæmaturia here referred to occurred in attacks, apparently from the bladder. Klemperer, in discussing this subject, uses the term "angioneurosis." But among his cases are included those due to acute inflammatory congestion of the kidney, to calculus or retained urates, or to kinking of the ureter. Cases such as these are now common subjects for surgical treatment. If the term "angioneurosis" be thought a suitable one, then it may be held to occur and affect the bladder without any anatomical lesion. As such, the cases may be compared to those of post-operative hæmatemesis with fatal results, when no changes are found in the stomach. Many such fatal cases of hæmatemesis have, however, been attributed to sepsis, but this explanation is not applicable to my cases.

As to the term "hæmophilia," in neither of the two cases was there any evidence of inheritance. In the fatal case, in which the large vessels seemed rather thin, there had been no previous hæmorrhages.

XXIV.—*A case of Attempted Division of the Eighth Nerve within the Skull for the relief of Tinnitus.* By CUTHBERT S. WALLACE and H. J. MARRIAGE. (With a Report on the Resulting Degenerations by E. FARQUHAR BUZZARD). *Read March* 25, 1904.

M. C., female, æt. 23, milliner. In February, 1898, the patient developed left otitis media, which was quickly followed by a mastoid abscess. The abscess after being opened soon healed up, but the discharge from the ear continued. In October of the same year the mastoid was opened and a more or less complete operation performed. The result being unsatisfactory, in July, 1899, and again in March, 1900, the patient was admitted to St. Thomas's Hospital and more bone removed; on the latter occasion the cavity was grafted. In spite of this the discharge continued, necessitating a further removal of bone and granulations in December, 1901. On this occasion also the unhealed surface was covered with Thiersch grafts. After this operation the discharge ceased, and the whole cavity completely healed.

For a year all went well, but at the end of this period pain was experienced in the posterior part of the mastoid process. In addition to this the patient began to suffer from tinnitus and vertigo.

On admission (August 18, 1903).—An anæmic girl complaining of giddines, noises in the ear, and pain over the left mastoid and in the course of the small occipital and auriculo-temporal nerves.

The external auditory meatus and the middle ear were represented by a large smooth cavity lined with healthy white skin. The bony labyrinthine wall was intact.

One of us made the following note of the condition of the left ear.

"When speaking in a loud tone directly into the left ear, after closure of the right, sounds are heard, but no words can be distinguished. A loud ticking watch is heard only when placed in contact with the remains of the left mastoid. On the right side the same watch is heard at a distance of twenty-four inches. A tuning-fork placed on the forehead is heard on the right side only; when placed on the point of the chin the fork is heard slightly on the left side, but quite

distinctly on the right; the tuning-fork is not heard at all when held immediately opposite the left meatus, and only just heard when placed on the left mastoid. In the right ear the air conduction is considerably better than that of the bone, though slightly shorter than normal.

"The noises in the ear ceased on compression of the left common carotid artery."

There were two tender spots behind the ear; one at the junction of the posterior border of the mastoid process with the skull, and the other at the lowest part of the same border. The amount of tenderness varied considerably, but could always be elicited on pressure. There was no œdema or sign of acute inflammation.

The pain radiated in the distribution of the small occipital and auriculo-temporal nerves, but its severity varied greatly. The tinnitus was entirely confined to the left ear, sometimes being compared to the rushing of water, at others to the sound of bells; it was always present, but was most noticeable at night, especially if the patient lay on the left side. Its severity had increased to such an extent that sleep was seldom obtained without the use of hypnotics, and even with these was broken and disturbed.

The vertigo was of the type usually met with in Menière's disease; when an attack occurred the ground seemed to rise towards the face of the patient. There was no inclination to fall to one side or the other, nor did objects appear to pass from left to right or *vice versâ*.

The patient never dared venture outside the house without a friend by her side.

The general condition of the girl was pitiable, and it was evident that unless something was done she would soon be worn out by want of rest. She was quite convinced that the causes of her trouble were the noises in the ear, and that compared with these all other symptoms sank into insignificance.

Drugs were tried with absolutely no result, and it seemed that the only recourse left was division of the auditory nerve, for we decided that, although the noises ceased on compression of the common carotid artery, it was not advisable to ligature that vessel, since the results obtained by this operation were not satisfactory in the cases reported by Meyerson * and Grunert † (in the former case the noises returned after four

* *Vers. d. deutsch. Naturf. u. Aerzte*, 1895.
† *Archiv für Ohrenheilkunde*, vol. xxxv.

hours, in the latter after four months), while in the case reported by Linsmayer,* who ligatured the external carotid artery, the noises ceased only for a short time, but hemianopsia and deafness of the same side, with hemiplegia of the opposite side, developed, and at the autopsy on the patient, who died on the fifth day from pneumonia, extensive recent softening of the hemisphere was found.

With this end in view we undertook numerous experimental operations on the cadaver.

There are two routes through which the auditory nerve can be reached within the skull.

(1) By exposing the cerebellum in the usual way, opening the dura mater, and slowly compressing the cerebellum inwards until the facial and auditory nerves come into view.

(2) By the operation for exploration of the posterior surface of the petrous bone. This is an elaboration of the ordinary operation for the cure of mastoid caries.

After consideration it was decided to adopt the second of these routes. We were influenced in our decision by the fact that a large amount of bone had already been removed, and also by the fact that there were still pain and tenderness at the posterior border of the mastoid process, pointing to some abnormal condition in these parts.

Description of the operation on the cadaver.—The complete operation for mastoid caries was first performed, the lateral sinus being exposed and the posterior meatal wall removed down to the level of the facial canal. The dura mater over the temporo-sphenoidal lobe was next exposed, and by working backwards and downwards from this point the dura over the cerebellum for a distance of three quarters of an inch behind the lateral sinus was laid bare. This was found to be necessary in order to gain space for retraction of the cerebellum in the later stage of the operation.

The portion of the temporal bone forming the inner wall of the mastoid was next removed, starting from the groove for the lateral sinus, and extending forwards and inwards as far as the horizontal semicircular canal and the remains of the posterior wall of the meatus. The extent of dura mater in front of the lateral sinus exposed by this means was found on an average to be three eighths of an inch.

The anterior edge of the exposed part of the dura mater was then incised to the extent of about one inch.

A flat retractor, half an inch broad and bent on the flat to a

* Politzer's *Diseases of the Ear*, 4th edition, p. 778.

convenient angle, was introduced, and the cerebellum compressed until, with the aid of a forehead light, the auditory nerve was seen running obliquely into the internal auditory meatus.

The depth of this nerve from the cut edge of the petrous bone varied in different bodies from half to three-quarters of an inch.

Approached in this way the facial nerve cannot usually be seen as it lies deep, that is internal to the auditory; but occasionally, as they appear from behind the cerebellum, the edge of the facial nerve can be seen just behind (above, speaking anatomically) the auditory.

Pressure on the auditory nerve, applied as near the brain as possible, enables the facial to be brought into view; a blunt hook can then be easily passed round the eighth without damage to the facial, and the auditory divided either by traction or by the scissors. On the cadaver the operation is not difficult, and it only requires patience to successfully divide the auditory and leave the facial intact. We performed the operation many times, and verified the result after the removal of the skull-cap.

On September 3, 1903, the first operation was performed, it being then intended to complete the procedure at one sitting. The usual incision was made through the old scar, and from the middle of this another incision was made backwards for about an inch in order to provide for the exposure of the cerebellum. The steps above narrated were followed out except in so far as the process was shortened by the previous removal of bone. The lateral sinus gave considerable trouble, it was large, tensely distended, and protruded in such a way as to suggest that the normal flow through it was obstructed. In removing bone at the lower part of the wound and over the lateral sinus, as it turned in towards the foramen lacerum posterius, considerable bleeding occurred, which necessitated plugging and the postponement of the operation until the bleeding ceased. The wound was therefore closed and the patient put back to bed.

The operation caused at first a considerable amount of shock, but it passed off by the next morning; vomiting was also troublesome, and the patient complained of pain in the region of the left ear and eye. Pulse 100; temp. 99·2°.

During the next few days her condition improved, but she still suffered from headache. The noises in the ear caused her great distress.

On September 10, the pulse being 92 and the temperature 98°, the wound was reopened and the operation proceeded with.

The lateral sinus, although now filled with clot, was still very prominent.

The anterior border of the exposed part of the dura mater was divided, the incision being somewhat curved with the convexity forwards; its length was about one inch. A large amount of cerebro-spinal fluid at once flowed out.

A flat bent retractor was then introduced, and an attempt made to expose the nerve; it was found, however, that sufficient room could not be gained owing to the resistance offered by the lateral sinus, this was therefore divided between ligatures.

The cerebellum was next slowly pressed backwards, but a good view of the parts could not be obtained, owing to the continual flow of the cerebro-spinal fluid. In addition to this considerable trouble was given by bleeding, which proceeded from the surface of the cerebellum. After much difficulty a view of the nerve was obtained.

By means of a blunt hook the auditory nerve was pushed aside and the facial nerve exposed, the hook was then turned through a right angle and passed behind the auditory nerve, which by traction was torn across. At this moment bleeding again obscured the view, but when this had ceased the divided end of the auditory nerve could be seen lying in the internal auditory meatus, while the facial, distinguishable by its small size, was seen to enter the meatus intact.

As far as could be judged the operation had been successful. The wound was closed, a small gauze drain being inserted at the lower angle.

September 11.—There was no facial paralysis, the tinnitus had greatly subsided, but was still obvious to the patient, the temperature was normal, the pulse 80. The patient complained of considerable giddiness when she attempted to raise her head, and also of headache. The dressings were continually soaked with cerebro-spinal fluid.

September 12.—The flaps were found bulged by blood-clot, some of which was let out.

September 14.—The cerebro-spinal fluid was still being discharged in considerable quantities. The stitches were found to have given way, and a considerable amount of blood-clot to have been extruded. There was some hernia cerebelli.

There was no attempt at healing in the wound. Temp. 98·8°; pulse 84. Diplopia was present to a very slight degree. The headache still continued, but was less severe.

Patient had not rallied properly from the operation, and although she complained of giddiness her state did not admit of any attempt being made to learn the exact nature of this, beyond the fact that it did not trouble her if she kept quiet. There was occasional vomiting.

September 24th.—The general condition remained the same. The diplopia had cleared up. The flaps no longer bulged and the wound was quite clean, but showed no signs of healing; the discharge of cerebro-spinal fluid continued. The headache was at times severe, and required morphia.

The patient no longer complained of tinnitus. The ocular fundi were normal.

From this time until the day of her death the condition of the patient varied very little. She gradually lost strength and became more and more apathetic, so that no observations of value could be made. The wound never showed any reaction or made any progress in healing. The cerebro-spinal fluid continued to be discharged in large quantities. The pulse varied between 100 and 120, and the temperature between 99·4° and 97°, except on September 28 when it rose to 101°.

Death occurred on October 1, 1903, twenty-one days after the division of the nerve.

The post-mortem examination.—There was no meningitis at any point.

The cerebrum was healthy throughout. The right cerebellar hemisphere was also normal in appearance and consistence. The left cerebellar hemisphere was somewhat soft, but showed no loss of substance. The cortex was blood-stained and the vessels full of blood.

The cochlea and semicircular canals on the left side presented a perfectly normal appearance.

The facial nerve was intact. The auditory nerve had been divided with the exception of a strand, as thick as a fine piece of cotton, which lay next the facial nerve.

The other organs were healthy except for old caseous foci at the apex of the left lung.

Report by Dr. E. Farquhar Buzzard.—The material submitted to me for examination included the lower half of the pons Varolii and the entire medulla oblongata; unfortunately the cerebellum had been removed from the former so that

the ultimate destination of certain fibres of the vestibular nerve could not be ascertained.

The whole piece was divided transversely into a number of thin blocks which were stained by the Busch modification of the Marchi method, embedded in celloidin and cut. The sections obtained were mounted serially and examined under the microscope with the following results briefly summarised.

The cochlear nerve.—About two thirds of the fibres constituting the entering root of this nerve were degenerated, the non-degenerate fibres being distributed in its lateral and posterior part. The majority of the degenerate fibres terminated in the ventral cochlear nucleus, a very few could be traced as far as the dorsal cochlear nucleus, and a considerable number turned sharply inwards and cerebralwards to the region of the superior olive, and, *viâ* the corpus trapezoides, to the opposite side of the pons.

The vestibular nerve.—The whole of the entering root of this nerve was degenerated. The large majority of the fibres could be traced into the principal nucleus (nucleus nervi vestibuli medialis) or into the descending root where they could be followed in diminishing numbers as far down as a level corresponding to the middle of the hypoglossal nucleus. A smaller number of fibres broke up in the neighbourhood of Deiter's nucleus (nucleus nervi vestibuli lateralis), and a few turned directly into the corpus restiforme soon after their entry into the substance of the pons. In the absence of the lateral wall of the fourth ventricle it was impossible to say whether any fibres passed direct to Bechterew's nucleus (nucleus nervi vestibuli superioris) or into other parts of the cerebellum.

In addition to the degeneration resulting from the section of the eighth nerve much recent degeneration was seen in the descending spinal root of the fifth nerve of the same side throughout its length in the pons and medulla, suggesting that the afferent portion of that nerve had been damaged in its extra-medullary course.

Finally there was noticed a hæmorrhagic softening of the tissue immediately surrounding a small vessel which entered the pons on the medial side of the vestibular nerve, and which pursued a course inwards, dorsalwards, and cerebralwards without however penetrating as far as the corpus trapezoides. The degeneration resulting from this vascular lesion was confined principally to certain transverse fibres of the pons going to the middle cerebellar peduncle. I have

seen similar vascular lesions as the result of the operation for the division of posterior roots, and attribute them to accidental traction upon accompanying or neighbouring vessels.

This case shows the possibility of division of the auditory nerve within the skull without injury to the facial.

The chief difficulty to be feared is bleeding from the surface of the cerebellum which was encountered in this case, and to which must be attributed the failure to completely divide the nerve.

At the operation no remaining strand could be seen, owing we think, to the strand adhering to the facial, and thus escaping recognition. The blunt hook must have penetrated the nerve in such a way as to leave this small portion behind, and in attempting to sponge away the blood after the hook had been pulled out the small strand was in all probability pushed up against the facial nerve and remained in contact with it.

The cause of death was not ascertained with any certainty. Probably the wretched condition of the patient before the operation was a contributing factor, as it left no reserve force to properly combat the shock of the operation, and to produce a healing reaction in the wound, and so prevent the continual loss of the cerebro-spinal fluid.

The case was a failure both clinically and scientifically. There was no doubt that the tinnitus was present, though diminished, for several days after the operation, and it is doubtful if it really ever subsided.

Taking into consideration the degeneration described by Dr. Buzzard, the continuance of the tinnitus must be attributed to one of two causes:

(1) That the noises are central in origin; or

(2) That the causes of the tinnitus originate in the cochlea, and the impulses by which they become apparent are conveyed to the brain by the cochlear nerve (the vestibular nerve was completely degenerated).

PLATE V.

Illustrating Messrs. C. S. Wallace and H. J. Marriage's Case of Attempted Division of the Eighth Nerve within the Skull for the Relief of Tinnitus.

FIG 1.

FIG. 2.

Bale and Danielsson, Ltd.

Mau

XXV.—*Cases illustrating the value of the "X" Rays as a factor of diagnosis of Early Pulmonary Tuberculosis.* By A. Stanley Green, M.B., B.S., and W. H. B. Brook, M.D., F.R.C.S. *Read May* 13, 1904.

THAT the early diagnosis of pulmonary tuberculosis is a matter of vital importance will, I think, be conceded by all, and I am bringing this subject before you to-night with the object of pointing out a comparatively new method of diagnosis, which may seem to some physicians quite unnecessary, but which I hope to prove to you is of some value, at any rate to those who do not have the same opportunities of examining a large number of chests as do those whose work principally lies in diseases of this portion of the human frame. That even the most expert physicians experience difficulty in the diagnosis of early cases may be taken for granted. "In the majority of cases where, as the result of physical examination, the patient is said to be suffering from phthisis in the first stage cavities already exist" (Dr. Percy Kidd, *Clifford Allbutt's System of Medicine*, vol. v, p. 209). Again, on the next page, we find "it is a matter of everyday experience that cavities in the lung may escape detection during life" (p. 210). If, then, we can show that by means of the "X" ray examination this diagnosis is made more easy and more certain, it is clear that much time may be gained, and the prospect of cure will therefore be increased. To do this it is necessary to prove three points:

(1) That we *can* demonstrate the presence of the disease.

(2) That we do *not* show the disease when it is really absent.

(3) That we can demonstrate the presence and extent of the disease before it is recognisable by means of the ordinary methods of diagnosis, especially where both lungs are affected.

It must, however, be thoroughly understood that this method is only to be used as an adjunct to symptoms and physical signs, a careful note being made of the patient's history, and can never *replace* the careful examination of the patient's chest by all the well-known and thoroughly understood methods at our command, including the examination of

the sputum—in some early cases, however, it is difficult to obtain sputum, and even then bacilli may not be found. In order that there might be careful comparison between the physical signs and the evidence elicited by the "X" rays I have, in nearly all my cases, asked my partner, Dr. W. H. B. Brook (referee to the Kelling Sanatorium), to work out the physical signs prior to the patient coming under my hands. We each write out our report, and compare the evidence thus obtained. As a result, I have never missed finding the disease when the physical signs pointed to its presence, and in about 50 per cent. of the cases I have demonstrated a more extensive implication of one or both lungs than it had been possible to discover by the usual methods of examination. It is not, however, fair on this account to say that the evidence the "X" ray expert produces is merely confirmatory, and I do not think this is correct, as the following cases, in which I detected disease by screen and skiagram prior to its discovery by physical signs, will show, and especially is this shown in those cases where one apex being the seat of mischief, the other apex becomes diseased. This mischief can be detected earlier and with more certainty by means of the "X" rays than by any other method. In fact, I think that when the disease has sufficiently advanced in one apex to be revealed by physical signs it will be found by the "X" rays in a very large percentage of cases that the other apex is already involved.

Two cases showing this will be quoted further on.

I here show a normal adult thorax as seen from the back, the tube being placed twenty inches from the patient's chest, the anode directly facing the part to be observed with its surface parallel to the greatest transverse diameter of the chest. The skiagram was taken during deep inspiration, the lead points having previously been placed on the back at the spot where the diaphragm was seen to stop in the deepest expiration. We thus register the maximum excursion of the diaphragm on the two sides. This averages two and seven-eighths inches on the right side, and two and five-eighths inches on the left, the minimum, that is quiet respiration, being about half an inch on either side (Dr. Halls Dally). This movement of the diaphragm is in most cases of a plunging character like a piston, but in some cases, where the breathing is of a decidedly thoracic character, the vertical movement is almost *nil*, and the sides of the muscle seem to contract towards the central tendon, the movement being

horizontal in character. In some cases the movement of the diaphragm on one or both sides is jerky in character (cog-wheel respiration). The importance of this part of the examination will at once be seen when it is stated that most observers are convinced that unilateral impairment of diaphragmatic movement is the earliest sign of pulmonary tuberculosis, and can often be detected before any physical signs are present or any shadow is impressed on the "X" ray plate.

Of course the value of this is to a certain extent discounted if there is any history of pleurisy. The patient must also be examined with the screen placed on the chest and the tube at the back. The importance of this was shown by Dr. David Lawson in a paper read before the British Electro-Therapeutical Society in March of this year, where he discussed what he termed the "Associated Movements of the Diaphragm," showing that where consolidation was apparently more marked towards the posterior aspect of the lung the amplitude of the range of movement of the diaphragm towards the back, as measured by the screen shadows, was considerably less in extent than the amplitude at the front. Furthermore, the relative level of the diaphragm on the affected side as compared with that on the unaffected side, as seen from the back, was higher than that observed at the front. Thus, in one case, where the shadow of the apices of the two lungs was most marked at the back, the right lung being more affected than the left, during deep breathing the range of movement at the back was exactly half as seen at the front. Again, in another case, where the right lesion was most marked at the back and the left most marked at the front, the left side of the diaphragm, as seen from the front, was distinctly higher than the right, but from the back the normal relation was preserved, that is, the right was slightly higher than the left. Other points which can be seen in the screen examination are the slope of the ribs (especially roof-tiling), the width of the intercostal spaces, the position and size of the heart shadow, which may be pushed over to one side by fluid in the opposite pleural cavity or dragged over by the contracting lung (this is better seen with the screen on the chest and the tube at the back); the transradiancy of the lung tissue, and the effect of this on deep inspiration, also any shadows which may be present in the lung tissue. The patient may also be examined by the lateral oblique method of Mignon, as by this means the enlargement of the

posterior mediastinum by a full inspiration due to the throwing forward of the heart may be clearly seen. The patient should be stripped to the waist during the examination, which can be carried out in either the erect position or lying down on a table with vellum top, the tube being placed in a box beneath, freely movable in both directions, and with the anode directly facing the part to be observed with its surface parallel to the greatest transverse diameter of the chest. A few words may not be out of place in connection with the diagnosis of pleural effusions, empyemata, and pyopneumothorax. A pleural effusion casts a dark shadow, the upper surface of which is concave and has a quick rhythmical movement imparted to it by the pulsation of the heart, and which varies in density from above downwards, and does not, as a rule, completely obscure the shadow of the ribs, of which very little can be seen when the pleural cavity is full of pus. Dr. Lawson has shown that where there is fluid but no air in the pleural cavity the upper level of the fluid takes a somewhat irregular curved form, the edges of the shadow being drawn up to a considerable distance above the other portion of the curve. But where air is present, as in a pyopneumothorax, the upper level of the fluid is horizontal. I would here refer my readers to his paper quoted above, and also to one by Dr. Halls Dally which appeared in the *Lancet*, February 27, 1904, where this point is very ably discussed. Apart from physical signs, the diagnosis between fluid and a solid lung can easily be determined by asking the patient to change his position, as, unless the fluid is encysted, the outlines of the shadow will alter. An important point to note in pleural effusions, especially in young adults, is the increasing transradiancy of the lung as the fluid clears up or is removed and the lung expands. If this does not occur, there is probably mischief in the lung, which may not be perceptible at this stage by physical signs.

The differential transradiancy of corresponding areas of the two sides must be carefully compared, both in quiet and in forced inspiration. To enable this to be done the light in the tube must be under perfect control. The healthy part of the lung becomes lighter when filled with air, the diseased portion naturally does not alter, the position of the arms can be changed so as to avoid mistaking any shadows cast by the scapula—Dr. Dally. Shadows differ very much in character and density in different lungs and in different parts of the same lung. These have been classified by Dr. Dally as:

Röntgen rays.		*Percussion.*
Brightness	...	Hyper-resonance
Transradiancy	...	Normal resonance
Faint Shadow	...	Impaired resonance
Dense Shadow	...	Dulness
Opacity	...	Absolute dulness (tanquam femoris)

I do not pretend to say exactly what pathological condition is represented in these different shadows, but it is quite certain that we can differentiate between consolidation, cavitation, and some cases of fibrosis; when cavitation is suspected I consider it a good plan to examine the patient with the screen and then ask him to cough; an area of shadow, which at first appeared homogeneous, may, after a fit of coughing, show small light areas scattered through it, indicating cavitation.

One point that has puzzled me, and to which I would direct particular attention, is that after all physical signs have cleared up, in many cases the lung, as seen by the "X" rays, appears almost exactly as it did when first examined. I have several cases amongst my collection, and intend following up their future history carefully, one especially of a patient who put on twenty-one pounds in weight, and whose physical signs have entirely altered, and in the right lung have entirely disappeared, but whose negatives taken before and after his return from the sanatorium are exactly identical. I was, however, much struck with one case I sent to a sanatorium. She had a large area of opacity in the left apex, and a cavity in the axillary region level of fourth to sixth ribs. She stayed at the sanatorium three months, and was told when she left that her lung showed great improvement. My examination showed the density of the apical opacity to be the same, and the area slightly increased; the cavity was also seen to be in the same condition, and the ribs were falling together (roof-tiling), consequently I gave a bad prognosis. Unfortunately this proved to be the correct one, as now, in spite of open-air treatment, the whole of the left lung, except a small area at the level of the spine of the scapula, is quite opaque, and there is a small opacity in the apex of the right lung, the condition of the patient being much worse.

With regard to the relative value of screen examination and skiagrams I consider that they must be used together, as the screen shows the position and movements of the dia-

phragm and any variations in transradiancy, whereas the plate will often register shadows that are not visible to the eye by means of the screen, and where improvement is taking place, and the disease becoming less active, the movement of the diaphragm will in some cases show great improvement.

The case J. H. is now able to take a deep inspiration sufficient to move his diaphragm two and a half inches on either side.

The method I have always followed in taking my skiagrams is as follows:—The patient either sits up or lies down and either puts his arms above his head, and thus makes the space between the vertebral borders of his scapulæ and the spinal column wider (an important point), or else lets them lie at his sides, making an angle of 45° with his thorax, with the plate between his back and the couch, and the anode of the tube twenty to twenty-four inches from the plate, and either opposite the fourth rib of one side when each lung is taken on a separate plate or opposite the mid-sternal line at the same level, where only one plate is used for the whole chest. The advantages of using the plate to back method have been thoroughly discussed by Dr. Lawson in the paper before quoted. Briefly stated they are:

(1) Comfort of the patient, and therefore less liability to cough.

(2) The lesion in the apex is in the greater majority of cases nearer the posterior portion of the lung, and therefore a clearer shadow is obtained on the plate.

(3) Only the posterior portions of the ribs show on the plate, and the lattice-work appearance is avoided.

A ten-inch coil is used, the exposure varying from thirty seconds to sixty seconds, a heavy anode tube being used. Voltage at present 230 with Wodal jet interruptor. (I used to work with accumulators—40 volts and a MacKenzie Davidson break.) I have used many makes of plates, and I think that for lung work the Lumiere, if thoroughly developed, gives the most reliable skiagrams. The development should be done by the medical man himself and not left to a chemist or professional photographer, as, apart from ethical reasons, much can be learnt during the development of a plate which is not so easily demonstrated when the film is fixed. After using many developers I have finally come back to our old friend pyro-ammonia. I find that the process of development generally takes about twenty to twenty-five minutes. By this time the plate will be quite yellow, but the print will be

very bright. Whenever possible the exposure should be made *while the ribs are motionless*, and this can be done by causing the patient to take a deep inspiration, and then holding his breath from fifteen to twenty seconds (I always ascertain beforehand by experiment how long a patient can hold his breath, but find the average is fifteen seconds), the only difficulty experienced is that sometimes this occasions a fit of coughing, and no further exposure can be given on the plate. Where the respirations are very rapid the excursions of the ribs are not very great, and blurring of the rib margins are not very marked. Wherever possible stereoscopic views should be taken, and with my table this involves absolutely no trouble whatever. If chest radiography is to be carried out successfully all the apparatus must be in a state of readiness and efficiency, and the examination must be carried out as rapidly as is possible with efficiency.

I have so often discovered mischief in the area between the vertebral border of the scapula and the spinal column when physical signs have been absent here that I am always now on the look-out for its occurrence, but great care must be taken not to confound them with those faint lines which are seen in a large number of radiographs along each side of the mediastinal opacity; enlarged mediastinal glands may cause a bulging of the aorta to the left which might possibly be mistaken for an aneurysm, but this mistake would, of course, be avoided by a careful screen examination.

Fallacies must inevitably crop up in any new method, whether of treatment or diagnosis; the chief one I have met so far is that mentioned above, where the physical signs having disappeared the shadows remain in the skiagram, and it remains to be proved if this is a fallacy.

I will now quote a few cases in which the "X" rays have been of undoubted value in the early diagnosis of pulmonary tuberculosis.

G. A., æt. 7, was sent to us by Dr. Wilkinson, of Gainsborough, with the history that he had been ailing since July, 1903, and had had an attack of bronchitis with right pleural effusion in January of this year. The effusion cleared up without aspiration, but the evening temperature was consistently high. The child had a cough, but very little expectoration.

Present condition.—Pale strumous-looking child with enlarged cervical glands. Pulse 156; resp. 30 per minute.

Physical signs (Dr. Brook).—Right side of chest smaller than left, and more or less slight impairment of resonance in right infra-mammary region (site of old pleurisy). Breath-sounds well heard all over. No adventitious sounds whatever.

Screen.—The diaphragm was seen to move freely on both sides. The lung tissue of right while not showing any definite opacity was less transradient than the left side, and was less affected by a deep inspiratory movement than the left side.

Skiagram.—Exposure forty-five seconds. Amp. 3. Lumiere plate shows extensive small deposits scattered through the lung extending as far down as the eighth rib. On the left side the deposits are of the same character, but not so extensive.

The chief interest of this case is that the X-ray examination was sufficient to settle the diagnosis, and to show disease on both sides in spite of the absence of physical signs, and this in a case of pulmonary tuberculosis occurring after a pleural effusion, a condition very difficult to diagnose by the ordinary methods.*

The next case is of interest inasmuch as the X-ray examination discovered definite disease in the right lung six weeks before any physical signs could be detected, and when these latter were present the disease had then involved the left lung. The case had been photographed several times, and is now at Kelling Sanatorium. I treated him for a few weeks with the brush discharge from the H.F. current, and I think it helped him to tide over the time before he could be admitted to Kelling.

H. H., æt. 24. History of influenza April, 1903, followed by feeling of lassitude and depression, loss of flesh and cough since July; very little expectoration.

Physical signs (Dr. Brook).—Very slight dulness over right apex; no adventitious breath-sounds or abnormality.

Screen.—Movements of diaphragm. Right side quiet respiration quarter of an inch; left side half an inch. Maximum right side one inch, left one and a half inches. Right apex opaque with a less dense shadow extending down to the sixth rib behind. Left lung clear. Tubercle bacilli were *not* present in the sputum.

The skiagram showed well-marked opacity in right apex

* G. A. subsequently died July 4, having developed physical signs of pulmonary tubercle before death.

more extensive than the slight dulness indicated, and on the left side some slight mottling in the upper half of the lung.

One month later the patient returned; the physical signs were then pronounced on both sides.

Inspection.—Movements deficient, especially on left side.

Percussion.—Resonance impaired at left apex down to third rib, and to a slight degree over the supra-scapular region.

Auscultation.—An occasional crepitation heard over the right clavicle. Crepitations well marked on the left side from the apex down to the fourth rib.

An occasional crepitation heard over left supra-scapular region. The movements of the diaphragm on both sides less than a quarter of an inch, and the skiagram showed extensive opacity over the whole of the right apex, with mottling down to the eighth rib, and mottling throughout the whole of the left lung, with a small area of opacity in the apex.

The last skiagram was taken on the day previous to his departure for Kelling Sanatorium. Movements slightly deficient on right side, more so on left. No impairment of resonance on right side. Resonance impaired at left apex down to third rib and over the supra-scapular region. An occasional crepitation heard below the right clavicle. Crepitations all over the left front. Bronchial breathing and bronchophony from the apex down to the fourth rib. An occasional crepitation left supra-scapular region. Bronchial breathing below the spine of the right scapular.

The next case was also an interesting one, as it was carefully watched for many months.

Miss C., æt. 25. Unilateral case throughout the whole course; sent for me complaining of nasal catarrh. I found she had been losing weight, and had a slight but persistent cough. History of pleurisy on left side four years ago.

Physical signs (Dr. W. H. B. Brook).—Inspection: clear movements diminished on left side. Percussion: no impairment of resonance on right side. High pitched note in middle of left clavicle. Resonance impaired for two inches below left clavicle. No impairment of resonance behind. Auscultation: right side, no abnormal sounds. Left side, breathing supra- and infra-clavicular region and over the supra-scapular region.

Screen.—Diaphragm moves very little on left side. Right moves very well, descending a full inch. Left chest less

translucent all over than right, which is particularly bright, and the apex of left completely opaque.

Skiagram.—Mottling over left lung as far as eighth rib.

March 22.—After open-air treatment in South of England; general condition of patient improved. Nasal condition cured, very slight cough, appetite good.

Screen.—Left side: diaphragm does not move at all, even in forced inspiration. Right side: movement one and a quarter inches. Left side more opaque than on previous examination.

Skiagram.—Mottling darker and more extensive.

She then went to Kelling for five months, where she made good progress, and when she returned the physical signs were:—Right side: nothing abnormal. Left side: resonance impaired left clavicular and supra-scapular regions. Movements diminished. No abnormal breath sounds in front. Cavernous breathing, with coarse crepitations, over left supra-scapular region. The movement of the diaphragm improved, but the mottling is as pronounced as before. Right lung clear. Six months later I photographed her again, and you see the lung is becoming much more transradiant.

February 20, 1904.—Slight impairment of resonance at left apex in front. No abnormal breath sounds.

Another case showing the value of the rays in the diagnosis of bilateral cases is the following:—J. B., æt. 62, a thin man with stooping shoulders, had been complaining of cough and loss of appetite for two months. Physical examination revealed extensive disease in the right chest, especially in front; *nothing abnormal* in the left lung; and this was confirmed by an *expert physician.*

Screen examination showed very extensive movement of the diaphragm on both sides in deep inspiration (this is the first time I have seen the diaphragm move so freely with extensive disease in both lungs). Both apices were opaque, the right more so than the left, and the area over which this opacity extended reached as far as the sixth rib on the right, and fourth rib on the left side.

Skiagram.—The shadow on the right side covered nearly the whole lung as a dense opacity. On the left side the shadows were not so dense, but extended as far down as the eighth rib, interspersed with light areas. Tubercle bacilli were numerous in the sputum.

PLATE VI.

Illustrating Dr. A. Stanley Green and Dr. W. H. B. Brook's Cases illustrating the Value of the "X" Rays as a Factor of Diagnosis of Early Pulmonary Tuberculosis.

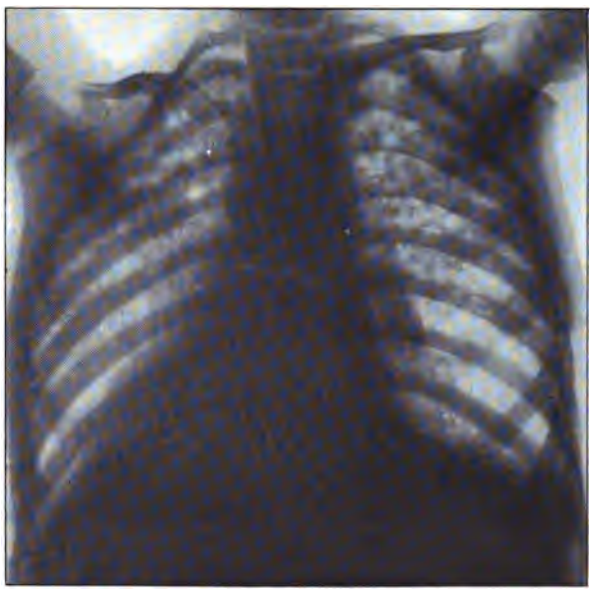

FIG. 1.

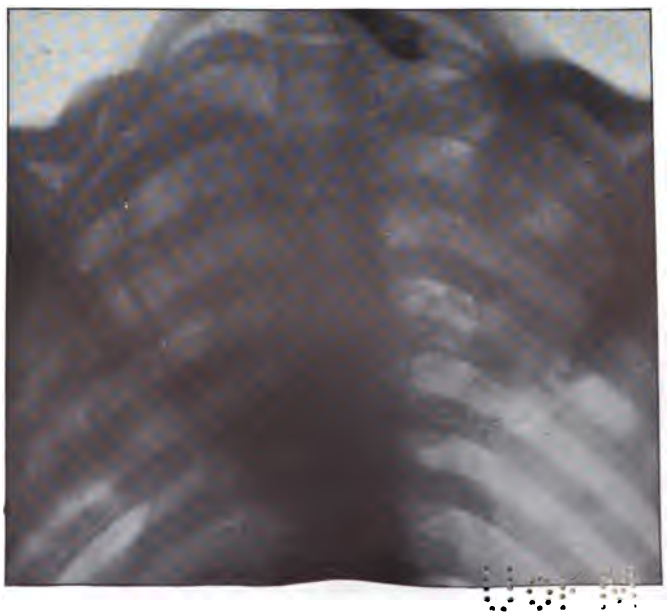

FIG. 2.

Bale and Danielsson Ltd

Mail

PLATE VII.

Illustrating Dr. A. Stanley Green and Dr. W. H. B. Brook's Cases illustrating the Value of the "X" Rays as a Factor of Diagnosis of Early Pulmonary Tuberculosis.

FIG. 2.

FIG. 1.

Bale and Danielsson, Ltd.

Mail

PLATE VIII.

Illustrating Dr. A. Stanley Green and Dr. W. H. B. Brook's Cases illustrating the Value of the "X" Rays as a Factor of Diagnosis of Early Pulmonary Tuberculosis.

FIG. 1.

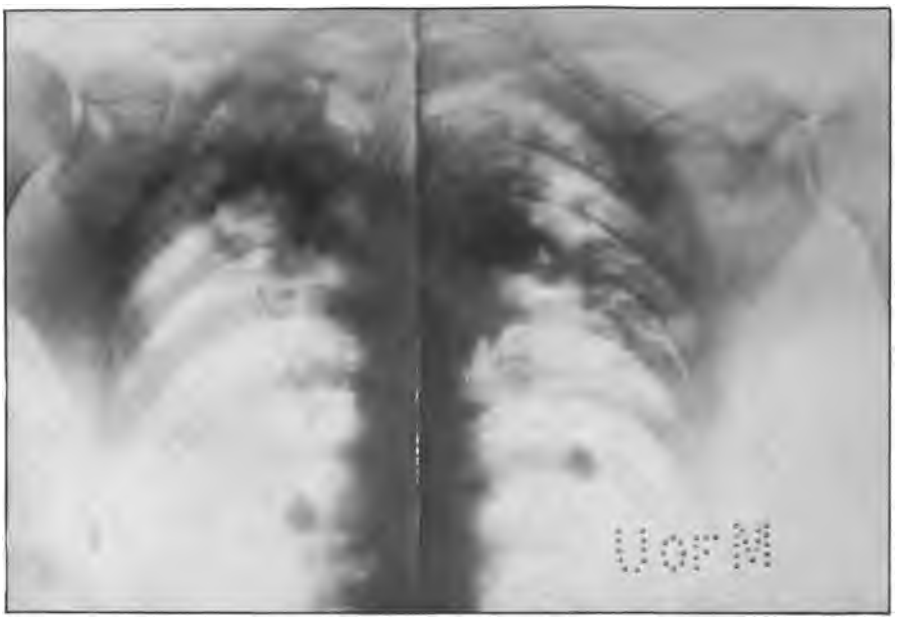

FIG. 2.

Bale and Danielsson, Ltd.

Not for Sale

PLATE IX.

Illustrating Dr. A. Stanley Green and Dr. W. H. B. Brook's Cases illustrating the Value of the "X" Rays as a Factor of Diagnosis of Early Pulmonary Tuberculosis.

FIG. 1.

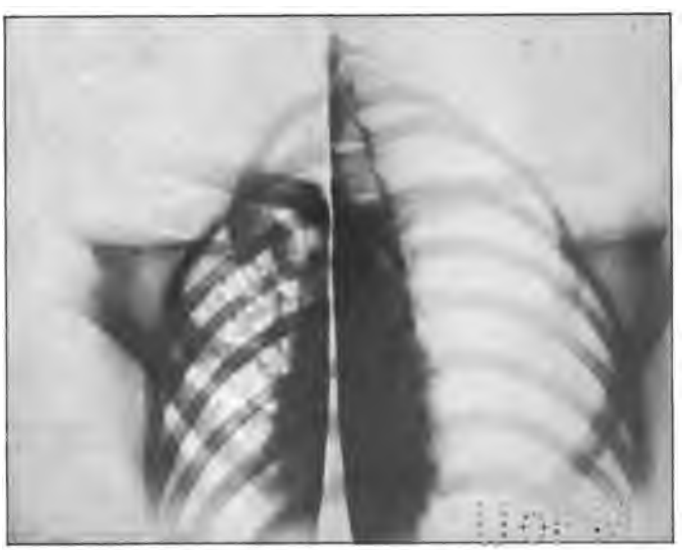

FIG. 2.

Bale and Danielsson, Ltd.

This case is of interest, inasmuch as the patient gained 21 lbs. in weight during his stay at the Kelling Sanatorium. His physical signs almost entirely disappeared, and yet his left lung has not cleared up, according to the X-ray examination.

W. K. W., æt. 26 years.

History.—Accepted for life assurance 1898. April, 1900, right pleurisy; October, 1901, left pleurisy; October, 1902, hæmoptysis; November, 1902, hæmoptysis; February, 1903, hæmoptysis. Has suffered from cough, and been losing flesh for some time.

Physical examination (May 18th, 1903).—Movements deficient on left side.

Resonance.—Slightly impaired left apex in front. Considerable dulness in left infra-axillary and supra-scapular regions. Slight dulness right supra-scapular region. An occasional inspiratory click at left apex. Harsh breath sounds in left infra-axillary region. Crepitations along the vertebral border of the left scapula. Broncho-vesicular breathing over the right supra-scapular region.

The patient was examined by the screen, and the movements of the diaphragm on the left side were seen to be greatly impaired, and were certainly less than half the normal on the right side. A dense shadow was seen in the left lung behind extending from the fourth to the seventh rib, with fainter shadows above and also below extending into the axilla. A faint mottling was seen throughout the greater part of the right lung.

The patient was then sent to Kelling Sanatorium, where he put on twenty-one pounds in weight, and returned, looking very brown and well, December 18th, 1903.

Physical examination.—Hardly any abnormal signs. Movements slightly deficient on left side.

Resonance.—Slightly impaired over left clavicular and supra-scapular regions. No abnormal breath signs.

Screen examination.—Practically no change, except that there is no free movement of the diaphragm on both sides.

The next case shows how faithfully the X rays will record the amount of disease present in a bilateral case and how improvement may be recorded on the plate from time to time.

J. A., æt. 39, a maltster, came to me in February, 1903, complaining of distressing cough when he came out of the

malt house into the cold air. On examination I found a long uvula and the oropharynx red and injected. Larynx normal.

Physical examination (February 22, 1903).—Respiratory movements deficient on both sides, especially on the right. Resonance impaired on the right side from the apex down to the third rib in front and at the back down to the angle of the scapula. On the left side slight impairment of resonance below the clavicle and over the whole of the scapula area. Bronchial breathing over the right clavicle down to the third rib and along the vertebral border of the right scapula. An occasional crepitation was heard below the left clavicle on deep inspiration.

Screen examination.—Movement of diaphragm very slight on either side, but decidedly on the right. Apices of both lungs opaque, but the right showed a denser shadow than the left, and this extended as far as the seventh rib.

Skiagrams show a very great amount of consolidation. In later photographs the consolidation of the left side had given place to a considerable amount of cavitation. He went to a sanatorium and returned August, 1903.

August 22, 1903 (after sanatorium treatment).—Movement slightly deficient on the right side more than on left. Resonance impaired over the three upper spaces on right and below the left clavicle. Cracked-pot sound above right clavicle. Cavernous breathing above right clavicle, with bronchial breathing heard down to the third rib. On the left side an occasional crepitation on deep inspiration over the second intercostal space.

Screen examination showed greatly increased movement of the diaphragm on both sides and the lung tissue more transradient, the shadows being less dense and extensive.

Skiagram showed clearing up of the mottling on both sides and a distinct fibrosis in the left apex, where the area of consolidation is now replaced by a concentric fibrous area.

May, 1904.—Movements fairly good. Resonance impaired down to the third rib on the right and over the scapular region, but less than on August 22. No impairment of resonance on the left side. Bronchial breathing and cog-wheel respiration heard over second left interspace. Bronchial breathing and pectoriloquy over right supra-scapular region and one inch below the spine of the scapula.

Screen examination showed the maximum excursion of the diaphragm to be more than two inches on each side.

Skiagram shows this movement, a lead across having been placed at the level of the diaphragm in expiration.

The last case I will show is that of a man æt. 21, who had been told five months before that he had nothing the matter with his chest.

F. H. W., æt. 21.

History.—Cough on and off for two years. Worse in winter.

Physical examination (April 9, 1904).—Movements deficient on both sides, especially on left. Slight impairment of resonance over the three upper spaces on the left. Distinct dulness over the left supra-scapular region. Cog-wheel respiration below left clavicle. Crepitations heard in left axilla and over the whole left scapular region. Bronchial breathing and bronchophony well marked on the vertebral border of the left scapula. No abnormal sounds on the right side.

May 5, 1904.—Dr. Burton Fanning, of Norwich, reports that there are fine crepitations on coughing immediately below the right clavicle and the spine of the right scapula.

The conclusions I have arrived at are—

1. Unilateral limitation of diaphragmatic movement is the earliest sign of the onset of pulmonary tuberculosis, and can often be detected by means of the X-ray screen before physical examination reveals its presence.
2. The onset of disease in the second lung is detected earlier by X-ray examination than by any other method at present at our disposal.
3. The progress of the disease can be watched and registered.

XXVI.—*Notes of Two Cases illustrating the advantages and disadvantages of X-ray Treatment in Recurrent Carcinoma of the Breast.* By E. A. Peters, M.D., F.R.C.S. *Read May* 13, 1904.

Mr. President and Gentlemen,—I had hoped to have shown one of these cases to the Society, but unluckily her death occurred on April 26, so I propose to read the notes of this case and those of a similar recurrence of carcinoma of the breast.

Case 1.—Miss J., æt. 42. October 10, 1901.—Mr. Charters Symonds performed an extensive operation for removal of the right breast, with an extensive area of skin and contents of the axilla.

The X-rays were first applied June 24, 1902; the following condition was at that time present. A large adherent cicatrix extended across the right chest into the right axilla, and at its upper end there was a hard nodule of growth. Near the lower end of the cicatrix was a small weeping ulcer surrounded by an œdematous zone. There were three points tender to pressure on ribs one, two, and three.

The patient was treated for twenty-two months with X rays, applied in the first instance to the right anterior wall of the thorax and supra-clavicular space, and later to other parts included in the extension of the disease.

A twelve-inch coil, using a current of one and a half to two and a half ampères at eighty volts was employed to actuate a Cox record tube of four to five inches "hardness."

The exposure took place three times a week at a distance of eight to ten inches. If erythema lasted two days after an application, exposure of that part was discontinued. Lead screens were used to cover up other parts of the body. There were in all 146 exposures.

At first the patient noticed a burning sensation of the exposed skin, but soon the nodules gave her no discomfort. The nodules softened, the small ulcer healed. When the treatment was discontinued for two or three months the nodules increased in size, but on treatment disappeared to

such an extent that it was impossible to say from a clinical examination that the process was still active.

In August, 1903, there appeared, near the angle of the right scapula, beneath the skin, and adherent to the surrounding structures, a mass three to five inches across; this also yielded to treatment, leaving a hide-bound condition behind, which extended over a considerable area.

October, 1903, a nodule was detected in the supraclavicular fossa, and the arm became swollen. At the end of the same month there was an extensive weeping dermatitis of the upper part of the chest, and a small, white, sloughy spot appeared in the cicatrix over the third rib. This extended till it formed an ulcer three by two inches; it caused considerable local pain. The ulcer commenced to heal in six weeks' time, and had contracted considerably the last time I saw her, April 11. From time to time the edges would break down and a flake exfoliated from the third rib.

In the middle of December the arm became much more swollen, and the patient suffered from pressure neuralgia referred to the forearm and hand.

In March of this year a mass appeared in the left breast and several nodules in the skin covering the left side of the thorax. Treatment was directed to these parts also.

The patient suffered a great deal from the pressure neuralgia, which the rays seemed powerless to relieve. Ultimately this subsided to a great extent, and on April 11, when I saw her for the last time, she was fairly comfortable, although it was obvious that she had lost a great deal of ground in the last three months. I had examined her chest a few days previously, but could find no increase of dulness.

Two days subsequent to this a severe pain in the left side seized her, with symptoms of lung involvement. She was out of doors in ten days, but was attacked again with great pain in the chest, and died suddenly April 26, having the previous day decided to come to London from Folkestone to resume treatment, so impressed was she with the relief obtained.

Case 2.—Mrs. M, æt. 63. In 1892 Mr. Charters Symonds removed the left breast. The axilla and some recurrent nodules were later dissected out, and skin-grafting employed.

On March 4, 1902, the day of the commencement of the X-ray treatment, there were six nodules of recurrent growth about an inch in diameter, adherent to the skin and

ribs. There was also an area of impaired resonance below the sixth rib. X-ray treatment was carried on for two months. The nodules had completely disappeared, and the dulness very materially diminished. A rather extensive dermatitis followed, but cleared up at the end of a month. The patient died shortly afterwards of lung trouble.

The points I should like to call attention to in these cases are—

1. The invariable improvement in superficial recurrences and the healing of ulcers due to carcinoma.

2. The extension of the disease to the neighbouring subcutaneous areas, and inhibition of the disease in the areas exposed to the rays.

3. Liability of ulcers to break down from dermatitis and the great pain caused thereby.

4. Great relief of pain, except when the nerve-trunks are attacked.

XXVII.—*A case of Tuberculous Pyopneumothorax treated by Incision and Removal of Ribs.* By David W. Finlay, M.D. *Read May 27th*, 1904.

A CASE with which I had to deal in May, 1894,* first suggested to me the necessity of reviewing from an independent standpoint the opinions then current regarding the treatment of purulent effusion occurring in cases of tuberculous pyopneumothorax. The circumstances of that case, and an appreciation of the general principle of giving pus free exit where possible, led me to the conclusion that such cases should, as a rule, be treated on the plan now practically always adopted in purulent pleural effusions of the more ordinary kind.

The following case, although up to the present only partially successful, is offered as a small contribution to what is admittedly a difficult and important point in the therapeutics of this very serious lesion.

Charles K., æt. 17, by occupation a paper-worker, came under my care in the Aberdeen Royal Infirmary on June 27, 1900. He is one of a family of eight, of which all the others are alive and healthy, with the exception of one brother who died at the age of ten, the cause of death being unknown. His mother died of consumption. His own health had been good up to the present illness.

In the month of February preceding admission he began to suffer from cough, which had continued up to date, being occasionally accompanied by yellowish expectoration. Five weeks before admission he was attacked by sharp pain on the left side when he coughed, and also by shortness of breath, which has persisted. For the last few weeks he has been losing flesh, and has complained of sweating during sleep.

On admission his pulse was 104; resp. 44; temp. 100°; weight 7 st. 12 lbs. His complexion was pallid, his muscles

* Briefly recorded, along with others of pneumothorax, in the *Scottish Medical and Surgical Journal*, July, 1899, vol. v, p. 10.

flabby, and he had a short cough with scanty muco-purulent expectoration, and suffered from marked dyspnœa. He lay with most comfort on the left side.

Respiratory system.—On inspection the intercostal spaces were less evident on the left front than on the right, and the movement on the left was much impaired. The semicircumference of the chest at the nipple level was fifteen and a half inches on the right side, and sixteen inches on the left. Tactile fremitus was markedly diminished over the left front, and the percussion-note was over-resonant (obliterating the normal area of præcordial dulness) except towards the apex where it was somewhat impaired. The bell sound was readily elicited in the over-resonant area.

On auscultation faint breath-sounds of tubular quality were audible over the greater part of the left front, being best heard just below the clavicle; vocal resonance was also very feebly heard over the same area together with a few distant crackles and sibilant sounds. Over the right front tactile fremitus was well marked, especially at the apex, and here the percussion-note was distinctly impaired as far down as the lower border of the second rib. In the same area the breath-sounds were of bronchial quality, and the vocal resonance was increased. Numerous inspiratory crackles and a few sibilant sounds were also noted.

The area of præcordial dulness extended from the lower border of the third rib at the right border of the sternum outwards to the point of maximum cardiac impulse which was situated in the fifth *right* interspace near the parasternal line. Posteriorly tactile fremitus was abolished on the left side except in the supra-spinous region where also percussion resonance was impaired. From this downwards to a level about an inch below the inferior angle of the scapula the note was over-resonant, and below this impaired. The bell sound was well marked except at apex and extreme base, and the succussion sound was also present; breath-sounds were scarcely audible. On the right side tactile fremitus was well marked, percussion resonance impaired in the supra-spinous region, vocal resonance distinct, and the breath-sounds harsh and of bronchial quality; numerous râles were heard all over this back.

With the exception of the cardiac displacement there was nothing worthy of note in the circulatory system.

No abnormality was detected in the abdominal organs, excepting that the spleen could just be felt below the left

hypochondriac margin, and that the liver extended about a finger's breadth below the right.

The urine was slightly turbid, acid, with a specific gravity of 1017, and was free from abnormal constituents.

After a few days the catarrhal signs over the lower part of the right lung were found to be much diminished, and the cough had improved, but tubercle bacilli in abundance were found in the sputa; the sweating increased, and he was losing weight.

In about a week the heart's maximum impulse had become further displaced towards the right, and the semicircumference of the chest had increased on the left side by half an inch. Notwithstanding, there was no change for the worse in the boy's general condition; he took his food well, and was fairly comfortable. The fluid in the left pleura, however, was gradually increasing, and the bell sound disappeared. At the same time there was but little cough, a good appetite, scanty sputum, and no marked dyspnœa; sweating also was no longer complained of.

On September 6 he complained of some pain in the third right interspace, about the nipple line, where friction was perceptible, otherwise the physical signs on the right side remained as formerly noted.

An exploration of the left pleural cavity made about this time revealed clear serous fluid containing only a very few pus cells; and it was noted that the patient was feeling very well and sleeping well, with no cough to speak of, no pain, and no dyspnœa. Dulness over the left side, however, gradually extended, until about the end of November, when it was found to be present almost from apex to base.

On a second exploration fluid was obtained, which on standing deposited a considerable layer of pus, and a few days later sixty-four ounces of similar fluid were withdrawn by paracentesis. The temperature was now rising, and there was some sweating at night, the cough also having become rather troublesome.

A little later, the signs of active disease at the right apex having disappeared, it was decided to drain freely the pleural cavity, and to this end about three inches of the ninth and tenth ribs respectively, in the posterior axillary line, were removed, the pleura opened, and eighty-three ounces of pus, along with some thick curdy material, evacuated. The cavity was irrigated with a solution of boric acid, and a large drainage-tube inserted. The patient did not take the anæs-

thetic well, or a more liberal removal of ribs might have been undertaken.

The immediate effect was so far satisfactory, but although his general condition was fairly good there was for some time a daily discharge of pus amounting on the average to about four ounces, diminishing later to about two ounces, and later still to somewhat less. During this time he retained a good appetite and slept well; temperature was but slightly raised, and there was little sweating. A note made on May 17, 1901, states that there is considerable retraction of the left side, the breathing over the right side is generally harsh, and at the apex of bronchial quality, but free from adventitious sounds even after coughing. The amount of discharge is estimated to be about an ounce and a half daily. Improvement, although slow, has been quite distinct, since the pleura was freely drained.

On May 22 he was sent to the convalescent home on Deeside, where he remained for a month, after which he was readmitted to the hospital for further treatment.

His temperature was now steadily normal, and he had gained three pounds in weight, but there was practically no diminution in the amount of the discharge, and the urine was found to contain a trace of albumen. He was now transferred to the balcony of the ward, practically in the open air, but protected overhead by the balcony of the floor above; and I may remark here that he remained in the open air day and night, with a few short intervals, during the remainder of his stay in the hospital, even in the midst of frost and snow.

Here he felt very well, maintaining his weight and good appetite, free from cough and sweating, and with no pyrexial temperature; but the physical condition had remained for a considerable time unchanged, and as the limit of improvement under present conditions appeared to have been reached it was arranged to have more of the chest-wall taken away; and accordingly on September 7, 1901, portions of the fifth, sixth, seventh, and eighth ribs* were removed under the usual conditions. Again the patient did not take the anæsthetic well, but he recovered satisfactorily when taken back to the ward. The process of healing went on normally, and after the lapse of a few days he was returned to the balcony.

The discharge gradually diminished, amounting on the average to about a couple of drachms daily, and progress

* The lengths removed were the following:—5th rib 2½ in., 6th 3½ in., 7th 4¾ in., 8th 5¼ in.

seemed fairly satisfactory, although there was less shrinking of the side than might have been expected. There was no cough or sweating, and no rise of temperature.

On November 21 his weight was 7 st. 8½ lbs.; a month later it was 7 st. 12 lbs., and the amount of discharge was very trifling.

His general condition continued to improve, so that in the following March (1902) his weight was 8 st. 3½ lbs., but the discharge of pus still continued, although never more than a drachm or two, and it was found to contain numerous tubercle bacilli.

A cyrtometric measurement taken on April 8, 1902, showed the transverse diameter of the left side to be five inches, and of the right six and one eighth inches. (On June 27 the measurements were, left four and one eighth inches, right six and a quarter inches.)

Towards the end of May he was sent again to the convalescent home in the hope that the discharge might cease and the wound close. After a stay of four months, however, this hope was not realised and he returned to the hospital, as I had determined on removal of more of the chest-wall. The daily discharge of pus now averaged about a drachm and a half; his weight was 8 st. 5½ lbs, the highest noted.

On November 8 portions of four ribs were removed. He stood this operation and took the anæsthetic well, although he had some sickness and vomiting afterwards. Subsequently his temperature became febrile, but he felt very comfortable, and made a good recovery from the operation. A week later he was again put out into the open balcony, and remained there during the further progress of the case, with the exception of a few days when he suffered from a bronchial catarrh, accompanied by a return of the crepitant sounds at his right apex. Examination of the sputa for tubercle bacilli gave a negative result; the cavity appeared to be gradually diminishing in extent, and the external wound was healing satisfactorily. About the same time, however, albumen was found in the urine to the extent of 0·2 per cent.

During a period of about two months succeeding the last operation he lost nearly two stones in weight; but the crepitant sounds at the right apex soon disappeared; the temperature returned to a normal range, cough and sputa were trifling in amount, and the discharge from the pleural cavity did not much exceed a drachm on the daily average, no tubercle bacilli being found in it. The urine also showed

merely a trace of albumen. His weight in three weeks increased by nine pounds, and he continued to gain steadily in this particular, till by the end of the year he was found to weigh 7 st. 7 lbs. He was sent out daily when the weather allowed to take exercise in the hospital grounds.

In June of last year he was discharged, and sent again to the convalescent home with instructions to report himself at the hospital for examination at intervals of a month or thereby. The capacity of the cavity within the chest had been estimated from time to time by the amount of liquid which it would contain. At this time it held about one and a half ounces. His general health was excellent; weak breath-sounds were audible as far down as the level of the nipple on the left side, back and front; no adventitious sounds being heard anywhere. The edge of the liver was felt about half an inch below the costal margin in the right nipple line, and the spleen could be felt about an inch below the costal margin in the left nipple line.

He appeared for examination on July 18, 1903, when the only thing of importance noted was that his weight had increased by three and a half pounds.

On September 2 he came again reporting that he had been engaged for six weeks in herding cows in the neighbourhood of one of the villages on Deeside. His weight was then 8 st. 3 lbs., a gain of 3 lbs. since last visit. The discharge of pus was little more than a drachm. Albumen was still present in the urine.

Further opportunities of examination were afforded on January 25, February 8, and April 4 of this year. On the first of these occasions his weight was found to have gone up by two pounds, and on the second by three and a half pounds additional. There was very little pus on the dressings (from ʒj to ʒij daily); he had no cough; very little shortness of breath was complained of, and on the last occasion he reported that he had been able to do a little gardening in the country where he had formerly tended the cows. No increase had taken place in the size of liver or spleen.

On the 7th of the present month (May) I overhauled him for the last time before finishing this report and found his condition as follows:—Pulse 64, of fair strength; resp. 18; temp. 97·8° F. Weight 8 st. 8½ lbs; appetite good; no cough; no sweating; colour excellent. A small quantity of pus on the dressings (applied twenty-seven hours previously) coming from a very small wound, which had to be dilated

with a soft bougie (No. 8) before the cavity could be tested as to its capacity. It and the sinus held about one and a half ounces of fluid.

Left side of chest is much retracted especially towards the front; the transverse diameter of left side at nipple level is four and one sixteenth inches, that of right six and a quarter inches. Percussion resonance is impaired all over front and back of left side, except in the axillary region above the opening, and faint breath-sounds of bronchial quality are audible, accompanied above the nipple level in front by a few scattered creaking sounds on deep inspiration. The right side moves very freely, and is rather over-resonant generally, with normal breath-sounds, except at the apex, where they are slightly bronchial; no adventitious sounds are present on this side, even after cough.

The heart's apex is not palpable, but the first sound is best heard in the fourth interspace between the left border of the sternum and the parasternal line.

The edge of the liver is found about a finger's breadth below the right costal margin in the nipple line, and the spleen is just palpable on pressing the tips of the fingers up behind the left hypochondriac border.

The urine has a specific gravity of 1014 and contains about 0·34 per cent. of albumen.

The patient has been continuing his occupation of gardening, to which he again returns with instructions to have the bougie passed through the sinus daily in order to keep the opening patent.

I may add that the medicinal and dietetic treatment consisted chiefly in the use of creasote in thirty minim doses with cod liver oil, together with plenty of milk, butter, and fat bacon.

I do not, of course, put this forward as an entirely satisfactory case, but I think it will bear comparison with any conceivable result which could have been looked for under any other method of treatment. Although the cavity has not closed, and does not appear likely to do so unless still further operation is resorted to, the patient is now feeling well, and is not living the life of an invalid, having strength and comfort for engaging in useful occupation. So far as the end aimed at has not been attained, I think that this is probably due to the fact that the removal of fluid and ribs seemed always to lag behind the necessities of the case. The reason for this on the first and second occasions of rib removal was

that the patient took the anæsthetic badly, and it was considered risky to prolong the operation; and the delay in having recourse to operation at an earlier period in the first instance was due to the fact that I was rightly, or wrongly, held back by the obvious tubercular disease at the upper part of the lung of the opposite side. When the mischief there died out I considered the way clear to dealing radically with the pyopneumothorax, but the result of waiting was a condition of lung which could not expand, and thickening of pleura which prevented the necessary amount of shrinking of the chest wall to close the pus-secreting cavity.

I think there has been a growing tendency of late towards the view which I have endeavoured to illustrate by the foregoing case, but some recent writers dealing with the subject do not discuss the removal of the pus at all, and others pass it over with the briefest reference to paracentesis. In at least one noteworthy instance a decided opinion is expressed against radical measures. Fowler and Godlee * maintain the view that except where the amount of fluid is large, and for the relief of the dyspnœa, it is better to leave the effusion alone. "The extraction of the air, or the fluid, or both," they say, "is followed by very temporary relief, and a free incision is almost certain to be followed by disastrous results. This conclusion is arrived at as the result of sufficient personal experience. After an incision the patient is for a time improved, but the lung shows no tendency to expand, and before long, in spite of great precautions, it usually happens that septic changes occur. It has seemed as if the tubercular processes were stimulated to increased action as the result of the operation, and before very long the patients have fallen victims to the combined effects of tuberculosis and sepsis." This is a very weighty opinion, and the material upon which it has been formed has been, no doubt, much greater than any that has been at my command, but I may mention that the view which I have put forward has not been based upon the present case alone. Of two other cases treated by free incision and drainage, one, a young man twenty-one years of age, appeared to derive considerable benefit (being, however, only three months under observation); the other, a man aged thirty, was so far improved that he was able to return to his occupation as a canvasser for an insurance society. He died two and a half years after the evacuation of the pus, but he would pro-

* *The Diseases of the Lungs*, 1898, p. 643.

bably have enjoyed a further considerable prolongation of life if he had not fallen into habits of intemperance.

It seems reasonable, at all events, that the whole subject should be reconsidered apart from the influence of old established usage and predilection, especially in view of the recent advance in the treatment of tuberculous affections generally. If the outlook in cases of pulmonary tuberculosis is now more hopeful than it was a few years ago, there ought to be a corresponding encouragement attending the treatment of its complications.

XXVIII.—*Two cases of Tumour of the Left Auricle of the Heart, simulating Mitral Stenosis.* By Dr. H. T. Thompson and Dr. C. U. Aitchison (introduced by Dr. Percy Kidd). *Read May 27th*, 1904.

THE comparative rarity of tumours of the heart together with the remarkable resemblance of the clinical features to those of mitral stenosis have induced us to place these two cases on record.

Case 1.—Annie H., æt. 15, was admitted into the London Hospital on June 11, 1902, under the care of Dr. Percy Kidd, complaining of pain in the chest and shortness of breath. She had had good health until about twelve months before admission when she began to have pains in the chest. The shortness of breath had troubled her for about nine months. For the last five months she had had occasional vomiting, and this continued to be a marked feature all through the course of her illness. Three weeks ago she noticed that her legs and abdomen began to swell, and she was brought up to the out-patients, where she had been attending since May 28.

She had never had rheumatic fever, chorea, or pains in the joints, but was stated to have had sore throats occasionally. The only other illness from which she had suffered was a slight attack of erysipelas when three years old.

Her parents were healthy, and she had seven brothers and sisters alive and well. There was no family history of rheumatism or heart trouble.

The patient was a fairly well-developed child, with a pale face showing a well-marked flush over the malar bones, and reddish-blue congestion of the tip of the nose. The lips were blue, and the conjunctivæ slightly œdematous. The legs and feet were considerably swollen, but there was no œdema of the eyelids, and no free fluid in the abdomen.

She had considerable dyspnœa, especially on exertion, and had once fainted after running a few yards.

On examination of the heart the apex-beat was found in the sixth space four and one quarter inches from the mid-sternal line. Pulsation was felt in the epigastrium and over the right border of the sternum. Over the apex of the heart a short thrill presystolic in time was distinctly felt.

The area of cardiac dulness extended above to the third intercostal space, on the right to the right border of the sternum, and on the left to four and one quarter inches from the mid-sternal line.

On auscultation over the apex a short presystolic murmur was heard leading up to a short sharp first sound. This was followed by a systolic murmur almost musical in character, which was conducted out into the right axilla, and was heard behind at the angle of the scapula. A reduplicated second sound followed this murmur. The pulmonary second sound was accentuated, and the heart-sounds were normal at the aortic area.

The pulse was 100 to the minute, regular, and of small volume and low tension.

The respirations were quiet and 29 to the minute. The lungs were clear.

The liver was distinctly palpable two fingers' breadth below the right costal margin. The enlargement was regular, the surface appeared smooth, and it was somewhat tender on palpation.

The spleen was not felt. About thirty ounces of urine were passed in the twenty-four hours. The urine was acid, of sp. gr. 1020, amber in colour, and contained one eighth of albumen, but no other abnormal constituents. No casts were found.

The tongue was clean and moist, but the appetite was small, and the patient occasionally vomited the small amount of food she did take.

The case was considered to be one of mitral stenosis with slight failure of compensation, and was treated accordingly.

She was kept in bed on a light but nutritious diet, and a mixture containing bismuth and strychnine was ordered.

The pain in the chest continued, and she vomited at intervals during the day. Fluid began to collect in the abdominal cavity, and on July 12 130 ounces were drawn off by trocar and cannula.

On July 14 the patient had a smart attack of hæmoptysis, and continued to cough up small quantities of blood for some days.

On August 10 the right arm suddenly became very swollen and painful. The swelling extended from the fingers upwards to the shoulder. In the axilla and on the inner side of the arm hard circumscribed masses were felt along the course of the great veins. The external jugular vein also contained a

hard tender mass, and both it and the right subclavian veins seemed to be thrombosed. The arm was kept at rest, and glycerin of belladonna applied, and the thrombosis cleared up in about four weeks. Fluid again collected in the abdomen, and on September 5 240 ounces were removed. The liver was tender and easily felt by dipping. The auscultatory signs remained the same, with the exception that at times a triple rhythm was heard over the sternum. Both presystolic thrill and murmur were marked. During this period the pill of digitalis, squills, and mercury was given.

The urine still contained the same quantity of albumen, and some twenty to thirty ounces were passed daily. A small deposit was found to consist of epithelial cells and mucus only.

The œdema persisted, and on September 5 240 ounces were removed from the abdominal cavity, and on September 21 207 ounces were drawn off from the legs by means of Southey's tubes.

On September 14 the patient's condition was as follows:— The thrombosis of right arm had quite disappeared, but there was still much general œdema.

The heart's apex-beat was in the sixth space, five and a half inches from the mid-sternal line, being one and a quarter inches further out than it was on patient's admission. The area of cardiac dulness extended upwards to the third rib and reached well over to the right border of the sternum. At the apex a presystolic murmur, a short sharp first sound, a systolic murmur, and a reduplicated second sound were heard. The second sound was accentuated at the pulmonary area. There was some dulness and a few crepitations at the base of the right lung.

On September 27 the presystolic murmur and thrill ceased to appear and were never heard again up to the time of the patient's death on March 18, 1903, nine months after admission.

There was still a good deal of œdema, and the liver was now felt nearly down to the umbilicus. The right side of the heart was dilating as shown by palpation and percussion, and the urine was passed in smaller amount.

On October 23 the patient began to lose her appetite, and was sick after food, and on the following day her temperature suddenly rose to 102° F. Her tongue was dry and coated with brown fur, and she vomited four times during the day. The right leg was œdematous and very tender. The dorsum

of the right foot was red, hot, and tender, and black blebs formed upon its surface. Dry dressings were applied. She was seen by Mr. Barnard, who diagnosed thrombosis of the dorsalis pedis artery, and advised no interference as the circulation in the legs seemed to be gradually improving The temperature remained high for about seven days, and then became normal. A large ulcer formed on the dorsum of the right foot where the black blebs had broken down. The general condition remained the same, and on November 14 the ulcer on the right foot showed signs of healing at the edges.

On the 21st of November the following note was made of her condition:—Pulse 104, fair stroke, low tension. Venous pulsation in neck, but veins small and not dilated. There was visible and palpable pulsation all over precordial area.

The area of cardiac dulness extended above to the third rib, to the right to quite one inch beyond the right sternal margin, and to the left as far as the position of the apex-beat, which was situated in the sixth space, four and three quarter inches from the middle line. A systolic thrill was felt over the ventricles.

At the apex a loud first sound was heard followed by a systolic murmur, almost musical in character, conducted outwards, but not heard far round in the left axilla. The second sound was accentuated in the pulmonary area, while the heart-sounds were heard clearly at both tricuspid and aortic areas. The lungs were clear, the liver enlarged down to the umbilicus, but not very tender. The patient's general condition had much improved, and there was no ascites. The ulcers on the dorsum of the right foot were healing slowly.

On December 4 she got up in a chair in the evening. She had no pain and no dyspnœa, and seemed much brighter. All through December her general condition remained good, and the temperature remained quite normal.

On December 29 her pulse was 108, regular, small, but strong impulse and low tension. There was no dyspnœa and no pain. The heart's apex-beat had come in towards the nipple line, and was now in the sixth space, and only three and a quarter inches from the middle line of the body. The area of cardiac dulness reached above to the third rib to the right to half an inch outside the right border of the sternum, and to the left to three and a quarter inches from the middle line.

On auscultation over the apex the first sound was absent,

but a loud and musical systolic murmur was heard followed by a faint second sound. As one passed into the axilla the murmur became much quieter and lost its musical character. In the third and fourth spaces to the left of the sternum and over the pulmonary area a first sound, a systolic murmur, and a loud second sound were heard. In the aortic area both sounds were heard clearly, while in the tricuspid area the first sound was followed by a systolic murmur and a faint second sound.

The liver was enlarged down to the umbilicus, and was not very tender. There was no œdema anywhere, and the sore on the right foot had nearly healed.

On January 2 the patient suddenly became much worse; her temperature rose to 101·5° F., and she became very blue and restless. Her breath became very short, and she vomited frequently clear fluid and food *débris*. She was given $\frac{1}{60}$ grain of strychnine and grain 1 of caffeine four-hourly, but continued to be very cyanosed and short of breath. The temperature continued to be irregular until January 8, when she was again very sick, and her face became swollen and puffy. She passed twenty-four ounces of urine of sp. gr. 1034, smoky in appearance, acid, and nearly solid with albumen. There was a diffuse cloudy deposit consisting of epithelial cells, leucocytes, red blood discs, and many epithelial and granular casts. On the following day the face was still puffy, the cheeks cyanotic, and œdema of the conjunctivæ was noted. She was drowsy, and complained of pain in the right loin and of headache. She felt sick and vomited several times, and her temperature was 102° F. A diagnosis of subacute nephritis was made.

The heart failure became more pronounced. The pulse was feeble and threadlike, the stroke small, and the tension low. It was very irregular both in rhythm and force. The heart, as felt over the apex, was beating 150 times a minute, but less than one third of the beats could be felt in the radial pulse. Epigastric pulsation was marked, but the veins of the neck were not distended. The apex beat was in the sixth space and four and a quarter inches from the middle line. The area of cardiac dulness remained as before, and there were no signs of pericardial effusion. Over the apex a gallop rhythm was heard, the heart beating rapidly and irregularly. The second sound at the pulmonary area was accentuated. The veins over the abdomen were dilated, but no signs of fluid in the abdomen were detected. The edge of the liver

had receded to two and a half inches below the costal margin, and it was not tender on palpation. The spleen was not felt. There was slight œdema of the legs.

On January 10 she passed thirteen ounces of urine; acid; sp. gr. 1030; solid, with albumen on boiling; and the deposit contained many casts and red blood cells. The compound digitalis pill was omitted; stimulants and hot packs were ordered, and the patient's condition improved.

She remained in much the same state with the exception that fluid again began to collect in the abdomen, which was tapped three times during February, 1903. She only passed about eight ounces of urine daily, and this contained a large amount of albumen with many casts, both granular, fatty, and epithelial.

She died on March 20, 1903, an attack of diarrhœa with blood-stained evacuations supervening just before the end.

Briefly, the case seemed clinically to be one of mitral stenosis with failing compensation. It was complicated by an attack of thrombosis in the left subclavian vein, and later on by a similar process in the right dorsalis pedis artery, which led to superficial gangrene on the dorsum of the right foot. A good recovery was made from both these conditions, and she improved very considerably under treatment. An attack of nephritis, however, supervened, from which she never rallied.

At the *post-mortem* examination there was an excess of fluid in both right and left pleural cavities, with some adhesions on each side.

The pericardium contained about six ounces of fluid, its surface was quite smooth, and there were no adhesions.

The heart weighed ten ounces. The left ventricle was dilated, and its walls were somewhat thinner than normal. The right ventricle was dilated and hypertrophied. Both auricles were dilated. The left auricle was very dilated and its wall very thin. The endothelium lining it was opaque and very much thickened.

Springing from the auricular septum, and projecting into the left auricle, was a large, irregular, pendulous mass the size of a hen's egg, which, by means of a pedicle, passed through the mitral valve and hung freely in the left ventricle. Its outer surface was irregularly lobulated and glistening. On section it was firm, and its surface was coarsely granular, and showed evidence of longitudinal striation with some intervening red streaks. The most external parts were of a

translucent red colour. The tumour measured 2¼ inches by 1⅛ inches, and its attachment to the auricular septum was three quarters of an inch above the free edge of the mitral valve. The mitral valve was very little altered in structure; the curtains were very slightly thickened, and the chordæ tendineæ showed some slight shortening. The apices of the musculi papillares were obtuse. The tumour had no connection with the valve, and hung quite freely between the two curtains. The aortic and pulmonary valves were normal.

The peritoneal cavity contained much clear yellow fluid. The spleen was four ounces in weight, was firm, and somewhat pale. The kidneys each weighed six ounces. The capsule stripped easily, and left a pale, soft surface, upon which were the scars of several contracted infarcts. On section the surface was mottled. The cortex was increased in proportion to the medulla, and was swollen above its surface. The line of demarcation between cortex and medulla was very indistinct.

The liver weighed three pounds. The surface was irregularly scarred, especially the under surface. It was stated to have the appearance of an early atrophic cirrhosis, except that there was evidence of congestion and the capsule was not very much thickened. On section the liver substance projected prominently between fibrous strands, and such parts were soft and fatty, although the organ as a whole was firmer than normal.

The pancreas was covered with numerous patches of fat necrosis on its outer surface, and the gland substance was fibrosed throughout.

For the microscopical examination and report we are indebted to Dr. R. N. Salamon, director of the Pathological Department.

The tumour of the heart was examined microscopically, portions being removed at the base from the centre and from the most dependent part of the polyp.

At its attachment a large growth of connective tissue with well-formed nuclei was seen; this connective tissue was continuous with that of the auricular septum.

Calcareous deposits were found in this connective tissue near the base of the tumour. On making sections nearer the centre of the polyp it was found to consist of a low type of myxomatous connective tissue. In this were abundant blood vessels, which possessed a distinct endothelium, and on the outer side of which was some condensation of the connective

tissue. In the walls of some of the blood vessels a trace of elastic tissue could be made out.

Evidence of numerous hæmorrhages was present, and a considerable amount of blood pigment was met with. This was lying free in the fibrin and connective tissue, but was also contained in the mulinuclear leucocytes, of which large numbers were present. There were a few uninuclear cells and some large pigment containing giant cells. On staining sections with Weigert's fibrin stain no evidence of recent fibrin was discovered.

The polyp, then, is of simple structure from its attachment downwards. At its pedicle connective tissue with well-formed blood-vessels is easily recognisable, while below its structure is of a soft myxomatous nature with delicately-walled blood-vessels—a structure which might well be derived from a connective tissue metaplasia of fibrin.

It is possible that the growth started as a small true fibrous polyp of the septum, and increased in size by accretions of fibrin.

The liver showed a round-celled infiltration beneath the capsule, which was distinctly thickened. The connective tissue in Glisson's capsule was increased, but there was very little evidence of the formation of fibrous tissue between the liver cells. There was fatty degeneration of the cells both at the centre and at the periphery of the lobules.

The kidneys showed changes both in the cells and in the supporting tissues. The capsules of the glomeruli were swollen with albuminous exudate, contained a few red cells, and leucocytes imbedded in it. The vessels of the glomerular tuft were distended with blood. In the convoluted tubules the cells were swollen, the nuclei stained faintly, and the protoplasm had a granular appearance. The lumen was in many cases obliterated by cellular *débris;* fatty degeneration was seen in the portions of the cells adjacent to the basement membrane. In the collecting tubules hyaline blood and epithelial casts were seen. Between the tubules lay a fibro-cellular exudate rich in nuclei. There was no evidence of arterial disease.

Case 2.—The patient, a woman æt. 51, was admitted into the London Hospital, under the care of Dr. Warner, on the night of the 12th February, 1904, with signs of severe cardiac failure. She gave the following history:

About five years ago she began to suffer from general

weakness, and to get short of breath on the least exertion. If she stooped down her heart would beat violently, and she would experience a choking sensation in the throat. There was no pain.

These symptoms continued for about two years. She then had an attack of what she described as "congestion of the lungs and pleurisy," for which she was confined to bed for eight weeks. After this she was apparently free from symptoms for about a year, until she went to live in a house where she had to go up three flights of stairs. The same dyspnœa from which she had previously suffered then returned and gradually increased.

About last August she began to lose flesh, to have œdema of the legs, and to experience such distress on the slightest exertion that she was unable even to walk about the house, and had to take to her bed.

Until the onset of this illness five years ago she had always enjoyed good health. She had had scarlet fever at the age of sixteen, but never rheumatic fever or chorea, and no other illnesses. Occasionally during the last few years she had suffered from muscular rheumatism.

Her youngest daughter suffers from "rheumatism," and her eldest sister from "heart disease."

On examination the patient was sitting propped up in bed, and had considerable dyspnœa, some cyanosis, and much wasting. A band of herpes extended round the left side of the chest at the level of the nipple. The abdomen was prominent and the superficial veins dilated.

The heart's apex beat was extremely irregular and diffused over a large area, the outermost point of which was situated in the fifth space three fingers' breadth outside the nipple line. A distinct presystolic thrill could be felt. The area of cardiac dulness extended one finger's breadth to the right of the sternum, upwards to the lower border of the third rib, and outwards to the apex beat. The pulsation of the right ventricle could be distinctly felt in the epigastrium.

There were signs of the presence of a considerable quantity of fluid in the abdomen, the upper part of which was distinctly tender, but the edge of the liver could not be felt until after the abdomen had been tapped, when it was found to be almost a hand's breadth below the costal margin.

On auscultation at the apex there was a definite presystolic murmur leading up to a short, sharp first sound. This was followed by a blowing systolic murmur, which was well con-

ducted round to the back. There was no second sound. At the pulmonary area both sounds were heard. The second sound was not noticeably accentuated. At the aortic area both sounds were normal, and there were no murmurs. The pulse was small, feeble, and very irregular, but not very rapid, being on the average about 96 beats per minute. The respirations were 32 per minute.

The urine was scanty, concentrated, and contained about one quarter of albumen, and a heavy deposit of urates.

The patient remained in the same condition for six days, and then began to show slight improvement, the quantity of urine rising from nine to twenty ounces.

On the afternoon of the seventh day, however, she became suddenly unconscious. A nurse who was standing at the next bed at the time states that the attack came on quite suddenly; it was preceded by a groan and followed by slight twitching of the fingers of the right hand. The left eye was closed; the right partly open.

On examination the patient was found to be suffering from right-sided hemiplegia.

Throughout the next day the patient remained in this condition, having complete incontinence, and never regaining consciousness.

At about midday on the 21st the breathing suddenly became slow and irregular, and finally stopped.

At the *post-mortem* examination all the organs showed the usual back-pressure appearances. The heart was found to be greatly enlarged, weighing eleven and a half ounces. The left ventricle was hypertrophied and dilated, the right ventricle was also dilated, but did not show very marked hypertrophy. Both auricles were much dilated. The mitral and tricuspid valves each admitted three gloved fingers. The pulmonary and aortic valves were competent to the water test. In appearance all the valves were healthy.

On opening the heart a soft mass of greenish-brown gelatinous material (suggesting old clot) fell out of the left auricle. It was more or less spherical in shape and measured about two and a half inches in its longest diameter. It had apparently been broken off from its base during the insertion of the fingers into the auricle to measure the size of the mitral valve, for on one aspect of the mass was a freshly-torn surface measuring about one and a half inches in diameter, whilst on the wall of the left auricle a corresponding area presented the adherent remains of similar material over the

edges of which was reflected a membrane, which to the naked eye resembled in all respects the thickened endocardium. This area was situated on the inter-auricular septum, the fossa ovalis forming a large part of its base.

The following is the report on sections cut through the base and wall of the tumour (by Dr. R. N. Salaman):—"The covering membrane is composed of flattened out non-cellular fibrous tissue, possibly derived from fibrin. There is no elastic tissue in it at all. On the other hand the elastic tissue of the endothelium of the auricular wall passes straight on beneath the tumour mass and across to the other side, thus forming a more or less definite base to the growth. From this elastic lamina there spring numerous elastic threads which permeate a short distance into the tumour, whilst between the elastic membrane and the muscle tissue of the auricular wall there is a new formation of fibrous tissue, and some branches of the coronary artery which show a well-marked endo- and peri-arteritis. The tumour itself at its base is composed of fibrous tissue and very thick strands of unstriated muscle-tissue which lie round about small vessels. The remainder of the tumour is made up of true myxomatous tissue in which there run vessels (though scanty), which possess a definite endothelium, and a very thick but irregular coat of unstriated muscle. In the myxomatous tissue there is much pigment—probably derived from old hæmorrhages. These are embedded in the tumour cells of two types:—(1) a few coarsely granular eosinophil cells; (2) a large number of mast cells.

The tumour appears to be a myxomatous polyp springing from the region of the fossa ovalis."

There are several very carefully recorded cases of primary tumours of the left auricle.

Caron, *Bull. Soc. Anat. de Paris*, 1854, vol. xxix, p. 77—100, gives a detailed account of a case of a polypoid tumour of the left auricle, which hung down into the left auriculo-ventricular orifice and distended it. It occurred in a woman of thirty-six. There was no history of rheumatism, and no family history of rheumatism or heart disease. She presented the picture of cardiac failure, malar flush and livid lips, dyspnœa, palpitation, and dropsy. There was a systolic mitral murmur and an accentuated pulmonary second sound. The neck veins were not dilated. She suffered from hæmoptysis and eventually died of cardiac failure. At the *post-mortem* a pedunculated tumour fibrous in nature was hanging

from the left side of the auricular septum into the left ventricle through the mitral curtains.

That the heart is, as a rule, very tolerant of these tumours is evidenced by the following reported cases:

Letulle, *Bull. Soc. Anat. de Paris.* 1895, vol. lxx, p. 471, relates the result of a *post-mortem* on a woman of seventy-two who died of phthisis and amyloid disease of the viscera. In the left auricle was a fibrous pedunculated tumour in the substance of which were many calcareous patches. Microscopically it was a fibroma.

Hartill, *Brit. Med. Journal,* 1886, vol. 1, p. 73, relates a *post-mortem* examination upon a farmer who had always enjoyed good health and dropped dead suddenly by his plough. In the left auricle was a fibrous tumour weighing 9½ ounces, and about the size of a pullet's egg. No other cause of death was found.

Iabobsthal, *Archiv für Path. Anat.*, Berlin, 1900, vol. cix, p. 351—361, gives a plate of a fibro-myxoma of the left auricle hanging down into the left ventricle. The microscopical findings are almost exactly similar to those of the first of our cases.

The symptomatology of intra-cardiac tumours is discussed by Pavlowsky, Berlin Klin. Wochensch., 1895, vol. xxxii, p. 393—413.

The cases presented the features of cardiac failure together with the signs of embolism, fibroma, myxoma, sarcoma, and lipoma are all described.

A. Robin, *Archiv. de Med. Experiment de Anat. Path.*, 1893, p. 802—806, relates a case of myxoma of the left auricle with embolism of the left middle cerebral artery.

A most comprehensive account of these tumours and the possibility of their clinical differentiation from old valvulitis is given by Dr. Lion Berthenson, *Archiv. de Med. Experiment and de Anat. Path.*, Paris, 1893, p. 386—403. He relates the case of a woman, fifty-five years old, who had been troubled with cardiac symptoms for three years only. Her face was pale with a malar flush. There was œdema and dyspnœa, and a systolic murmur was heard at the heart's apex. As there was some compression of the left lung, difficulty in deglutition and increase of the area of cardiac dulness, aortic aneurysm was diagnosed. Embolism of right middle cerebral artery occurred.

At the autopsy a myxoma was found hanging from the auricular septum between the curtains of the mitral valves.

Dr. Berthenson regards the following points as suggestive of intra-cardiac tumours:

1. Absence of rheumatic history.
2. Signs of cardiac failure together with embolism due to fragments of the tumour breaking away.

In twenty-eight cases which he analysed the intra-cardiac tumour occurred seven times in the right auricle, three times in right ventricle, seven times in left auricle, five in the left ventricle, and six times in the wall of the heart. Sarcoma occurred nine times, myxoma seven times, fibroma six times, and lipoma twice.

I have been unable to find a case in which a definite presystolic murmur was heard, the cases having come under observation at a late stage. A mitral systolic murmur was frequently noted.

The only case of an obstruction murmur is that famous case of Sir W. T. Gairdner, *Edin. Hosp. Report*, 1893, 221—234. Here an obstruction to the tricuspid orifice was diagnosed ten years before death. The man complained of a venous wave in his neck, and went to Mr. Syme thinking that something surgical could be done. Sir William Gairdner found a well-compensated heart with an auricular systolic murmur best heard over the tricuspid orifice.

At the autopsy ten years later a fibroma of right auricle was found, which hung by a stalk between the tricuspid curtains.

In our two cases there co-existed well-marked signs of obstruction to the passage of blood through the mitral valve together with embolism in the one case of the dorsalis pedis artery, and in the other of the left side of the brain.

In the first case a well-marked presystolic murmur was heard in the earlier stages, but when the heart's failure became pronounced it disappeared and gave place to a systolic apical murmur.

In the second case a presystolic murmur was present till the end.

PLATE X.

Illustrating Dr. H. J. Thompson and Dr .C. U. Aitchison's Cases of Tumour of the Left Auricle of the Heart simulating Mitral Stenosis.

FIG. 2.

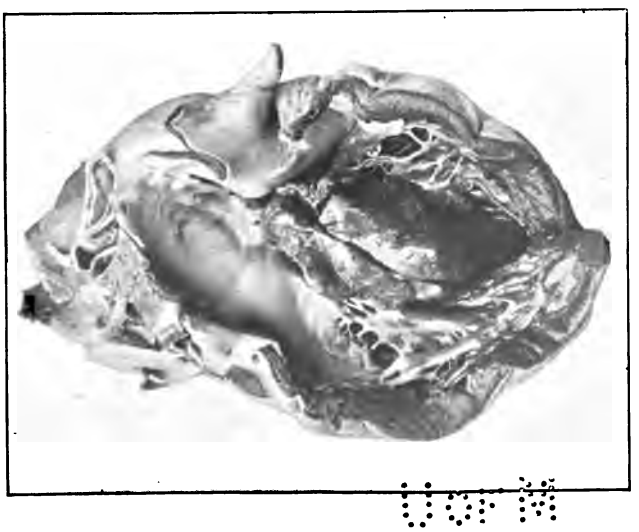

FIG. 1.

Bale and Danielsson, Ltd.

Digitized by Google

XXIX.—*Femoral Aneurysm in Hunter's Canal; Ligature of the Superficial, Femoral, and Popliteal Arteries; Cure of the Aneurysm; Death from Cardiac Disease ten weeks later.* By Henry Betham Robinson, M.S.Lond. *Read May 27th*, 1904.

FEMORAL aneurysms, or those occurring from that part of the vessel supported by muscles, are rare, and particularly so those strictly limited to Hunter's canal. They have been recorded involving both this part of the vessel with the popliteal in addition, the popliteo-femoral variety. In this case it was proved, as will be shown later, that the aneurysm was not of this type.

Lisfranc, in a table comprising 179 cases excluding the aorta, gives eighteen from the femoral artery, not including those in the groin, but he does not state the exact point of origin nor whether the popliteal was also involved.

Henry S., æt. 48, was admitted under my care into St. Thomas's Hospital, on August 19th, 1901.

His father died of a burst blood-vessel. He himself had always been a healthy man, without any history of syphilis, but owned to indiscretions with alcohol during the last four years.

Fourteen weeks before admission he had a bad attack of pneumonia. Four weeks before he began to have very great pain in his right thigh, lasting for hours at a time, for which various remedies had been tried without any relief. During the last ten days the leg had been very swollen, more than at the present time, and he had also noticed that the swelling in the thigh pulsated.

On admission there was a fairly large pulsating tumour occupying the middle third of the thigh (Hunter's canal), which was extremely painful and tender to touch; the pulsation was expansile. The right dorsalis pedis artery was much weaker than the left. There was double aortic disease with cardiac hypertrophy, but no evidence of thoracic dilatation. The pulse was moderately water-hammer, and the vessels obviously thickened.

A few days' observation showed him to have an irregular temperature, never exceeding 101·0°. As to the cause, ulcerative endocarditis was questioned unless due to the local

condition. Dr. Turney was certain there was no condition of lung remaining to account for it. There was no albuminuria.

As the aneurysm was of rapid onset and progressive, and so very painful, I decided to operate, so on August 28 I ligatured the superficial femoral artery at the apex of Scarpa's triangle. The vessel here seemed quite healthy, and three floss-silk ligatures were used and tied by the "Ballance and Edmunds" method. Any idea of excising the aneurysmal sac, if entertained, would have been impracticable as the sac was too diffuse. The ligature temporarily stopped all pulsation in the sac, but before the wound was stitched up it had returned with fair force. To combat this I ligatured the upper part of the popliteal, cutting down on it just below the opening in the adductor magnus, which procedure was perfectly successful in stopping all pulsation. The limb was dressed and well bandaged in cotton-wool.

August 30.—Considerable pain still in leg since the operation, but eased by morphia. The leg is fairly warm. The temperature remains irregular.

September 4.—Wounds healed and all stitches removed; no pulsation in the sac; condition of limb good; slight pulsation in dorsalis pedis; great complaint of the pain down the leg, which seems especially referred to the area supplied by the internal saphenous nerve.

September 11.—Pulsation now very distinct in the dorsalis pedis; very great pain in the leg; temperature irregular, ranging from 98·0° to 101·0°.

October 11.—Since the last note the pain in the leg has been just as severe; whether due to this cause or not his mental condition is very unsatisfactory.

October 14.—To try and remedy the severe pain down the leg the internal saphenous nerve was cut down on at the upper part of Hunter's canal, and one and a half inches of it resected.

October 17.—Considerable relief of pain followed the nerve resection, but unfortunately this proved only temporary, as he now again complains of its severity, and refers it particularly to the calf of the leg. His mental condition is most unsatisfactory, bordering on maniacal, so it is difficult to estimate the real character of his pain.

October 19.—After being in a most excited state all the night he says he feels very much better this morning.

October 21.—Quietor the last two nights, and able to do

without morphia; was given paraldehyde, but he sleeps very badly. He is getting very emaciated. There is still pain in the calf of the leg.

November 2.—Patient is very restless and excitable, complaining still of the great pain in the calf and foot. He lies with his legs drawn up, and cannot be made to straighten the right one.

November 5.—Died quite suddenly this morning from syncope.

P.M. report.—Aneurysm so much reduced in size as to appear as a slightly enlarged vessel with very thick walls, and filled with clot. Extensive aortic disease; left ventricle dilated and hypertrophied. Atheromatous patches on the mitral valve. Atheroma of aorta and coronary arteries. Spleen very large and soft, with superficial scar at one spot, either of infarct or gumma. Kidneys large and firm.

In the treatment of the above case the use of compression was negatived from the associated aortic disease with its attendant mental irritability.

The treatment adopted was the orthodox Hunterian operation; this was succeeded by immediate return of pulsation in the sac. To what was this rapid recurrent pulsation due? This is usually attributed to a free anastomosing circulation through a vessel communicating with the sac. Here it was very probable that the anastomotica magna did communicate with the sac, but the pulsation could not have been transmitted through it, for why did ligature of the popliteal above the upper articular arteries stop the pulsation? According to accepted views it is considered unlikely for pulsation to be transmitted to the sac through the lower end of the vessel, but yet in face of the facts it looks as if such were the case. We must suppose that there was such a free anastomosis between the descending branch of the external circumflex and the articular vessels already established that the heart's contractions were able to be transmitted to the sac's contents.

It may be urged that the ligation of the popliteal artery was unnecessary as the pulsation would have ceased in a short time, as is considered to be the usual sequel; it must be borne in mind there was also a probability in the other direction and the pulsation was very free. The adoption of a novel and what seemed a more certain course of action did not appear to be fraught with any danger, and was putting the patient in much the same position as in excision of the sac after ligaturing above and below.

The effect on the sac is worth noting. It will be remembered that the sac was an ovoid one of very rapid formation, and the presumption is that with this dilatation there had been next to no deposition of hard clot. The soft clot shut up in the sac with the vessel's wall underwent such rapid shrinkage that at the autopsy ten weeks later the only evidence where the dilatation had been was a slightly dilated vessel with very thickened walls.

As to the cause of the aneurysm it would appear that it was embolic. There were old vegetations on the aortic valves, and superimposed on this was recent endocarditis. His irregular temperature with pneumonia suggested that this was infective, and the acute development of the aneurysm was in accordance with such a view.

The only other point for consideration is what was the nature and origin of the severe pain in the leg. For a time I suspected the possibility of inclusion of the nerve in the ligature, but the painful area was not defined enough; it was proved subsequently not to be the origin because the nerve was shown not to have been included, and resection of a portion of it did not remove it. It is possible the attacks of pain were due to arterial spasm or arterio-sclerosis, the symptoms being allied to those met with in the condition of "intermittent claudication" first described by Charcot, and more recently by Osler, Levy, and Riesman.

CLINICAL CASES

EXHIBITED.

*** Published in accordance with the regulation relating to the exhibition of patients at the meetings of the Society, viz. that each case shall be accompanied by a brief written description of the points it illustrates; such description to be published or not in the *Transactions* as the Council may direct.

I.—*A case of Diffuse Lipoma* (Adiposis Dolorosa?) *in a Man.* By LEONARD WILLIAMS, M.D. *Exhibited October* 23, 1903.

THE patient up to two years ago was a sofa-frame maker who had always enjoyed good health. At that time, owing to lack of employment, he became barman at a beer and wine shop. His present trouble began soon after this change of work, and has developed gradually since.

There are bilateral, more or less symmetrical, swellings distributed over the trunk and upper arms; the face, forearms, legs, hands, and feet being free. Some of these swellings are typical lipomata, others give the sensation of a varicocele, while the larger ones suggest the feeling of a mamma. Their development was accompanied by pain, which gradually subsided as they reached their present condition. Pain is, however, very easily elicited by rough handling, and paroxysms of pain occur not infrequently without any obvious cause. There is a great tendency to hæmorrhages over these swellings, especially after any exercise of the underlying muscles.

The patient has become progressively asthenic since he came under observation two months ago. There is only one other recorded case of this disease in a male.

II.—*A case of Ectopia Vesicæ after Operation.* By Thos. H. Kellock, M.A., F.R.C.S. *Exhibited October* 23, 1903.

THE patient, a boy now æt. 4½ years, was the subject of complete ectopia vesicæ. There is nothing noteworthy in the family history, and he has enjoyed fairly good health.

The operation was performed in two parts. On the first occasion, in June, 1903, the penis, which was as usual in a condition of entire epispadias, was dissected from its anterior attachments, drawn through an opening made through the scrotum behind what represented the symphysis pubis, and fixed in that position by sutures.

At the second operation in August, 1903, the whole of the visible portion of the bladder was dissected up, turned down, and drawn under the arch of skin in front of the symphysis by sutures passed through its margins, left long, and attached to the skin of the thighs; a few sutures were passed through the back of the bladder thus turned down to fix it to the back of the bridge of skin. It was intended to graft the raw surface left where the bladder had been, but this healed over so rapidly that it was not required.

A small leak occurred at the side of the inverted bladder, which was treated by a slight plastic operation, and it has now practically closed.

All the urine now passes along the penis into the perinæum, where it is hoped it will be possible to collect it in an apparatus without much inconvenience to the patient.

III.—*A case of (?) Tumour at the Base of the Skull.* By Thos. H. Kellock, M.A., F.R.C.S. *Exhibited October* 23, 1903.

THE patient is 2½ years old, there is no history of syphilis; the father, mother, and one other child are alive and healthy.

When the child was three months old the mother noticed that the right eye was getting larger and the side of the head

projecting, and this condition has increased slowly to the present time, without apparently causing any pain or inconvenience. Shortly before admission the child had a fall, and was unconscious for some time. He is quite intelligent, shows some signs of rickets, the anterior fontanelle is not quite closed. The right eye is prominent, and the globe seems tobe enlarged and a little lower than the left. There is considerable bulging in the right temporal region, the swelling is bony; the head measures twenty-one inches in circumference. and there is a little bulging in the corresponding position on the left side. The upper jaw is apparently a little further forwards on this side, and the interval between the central incisors is to the left of that in the lower jaw.

There is a difference between the ears on the two sides, that on the left being more pendulous. On examining the back of the pharynx there is a distinct prominence—apparently the normal tissues pushed inwards—on the right side.

There are no paralytic symptoms in the face or rest of the body; the knee-jerks are normal. Scattered over the front and back of the trunk are numerous oval-shaped spots of light brown colour; these are said to have been present since birth.

Examination of the abdomen reveals nothing abnormal in the region of the left kidney; the right is covered by the liver, which is pushed downwards by the shape of the chest.

Report on the condition of the eyes by Mr. Lister.—"Right globe proptosed with slight displacement downwards, slight ptosis. Movements of globe free in all directions. Right cornea distinctly larger than left. Tension +. Pupil dilated, inactive to light. Anterior chamber deep. Media normal. Fundus well marked; cupping of disc. Left fundus, no cupping of disc, no sign of neuritis."

IV.—*Case of Vascular Naso-pharyngeal Fibroma of Extensive Origin, finally removed by a combined operation through the soft and hard palate and extensive removal of anterior wall of left superior maxillary bone.* By HERBERT TILLEY, M.D., B.S., F.R.C.S. *Exhibited October* 23, 1903.

F. S., male, æt. 14, complained of complete nasal obstruction associated with a blood-stained discharge from left nostril of five months' duration. Patient was weak and very anæmic. A large granular, easily-bleeding mass distended and projected slightly from the left nostril. Right nasal fossa quite occluded by septum, which was deviated to the right by pressure of growth in left nasal cavity. The tumour could be seen and felt projecting from the roof of left posterior choana on to the naso-pharyngeal wall, and gradually shading off into the mucous membrane of the latter. No protrusion of eye in any direction.

First operation (November 20, 1901).—A ∩-shaped incision was made over bridge and sides of nose, and the latter turned downwards, thus fully exposing anterior half of growth filling nasal fossa. This portion was removed with snare, forceps, etc., but the hæmorrhage was so free that remainder of growth was left and the nose sutured in place again.

Second operation (December 7).—In order to avoid the free flow of blood into lungs which occurred on the former occasion, a preliminary laryngotomy was performed and large sponge introduced above glottis. The soft palate was then divided in the middle line and the left half of hard palate removed. The easily visible growth was then removed by means of scissors and forceps. Hæmorrhage was easily controlled by sponges.

Third operation (March 15, 1902).—Growth had recurred, and operation identical with the second performed.

Fourth operation (July 31).—Owing to recurrence of growth (in spite of many attempts to reduce same by injections of formalin and insertion of galvano-cautery), it was determined to make one more attempt at removal and to explore the maxillary antrum. With preliminary laryngotomy as before an incision from the right to left malar prominence in the gingivo-labial fold was made, and the soft tissues of face

turned upwards. The nasal septum was divided along its lower attachment, and then the front wall of left maxillary antrum and the lower half of ascending process of superior maxillary bone was removed. The growth was then seen growing from the whole inner surface of the antrum and firmly attached to its walls; also from the ethmoidal and basi-sphenoidal region (from which it had previously been removed). The tumour was seized in strong forceps, and, with the help of a raspatory, was peeled completely and cleanly from its attachments. A loose packing of gauze was inserted into antrum, and the soft tissues of face returned to their normal position and secured there by a few sutures. The patient made an uninterrupted recovery, and has remained free from recurrence till the present. Since the last operation he has grown four inches, and is now the picture of health.

March 16, 1903.—The edges of the soft palate were freshened and sutured in the middle line. Immediate union occurred.

Remarks.—Histologically the tumour consisted chiefly of fibrous tissue traversed by large blood-vessels, and was described by the pathologist as a fibro-angioma. It was a typical example of a form of new growth which is clinically but not histologically malignant.

The preliminary laryngotomy and insertion of a sponge above the larynx were of immense service in the second, third, and fourth operations, for it not only enabled one to keep blood from entering the lungs, but also allowed the anæsthetist to narcotise the patient without interfering in any way with the operation.

V.—*Two cases of Osteitis Deformans.* By Herbert French, M.B. *Exhibited October* 23, 1903.

CASE 1.—William C., æt. 54, a painter. Has had no illness of any kind except gout. No syphilis.

Chief points.—Marked thickening of both tibiæ and fibulæ, with increase of curvature. Thickening of right patella, right femur, right clavicle. Kyphosis in dorsal region, lordosis in lumbar. No affection of cranium. Right leg half an inch shorter than left; walks bow-legged, and is obliged to use a stick.

FIG. 8.

FIG. 9.

The condition began three years ago, and has slowly progressed. He first noticed it after an acute attack of gout.

CASE 2.—Emma M., æt. 53, widow. Has had no serious illness. Has had one child, still-born.

Chief points.—Both tibiæ thickened and bowed forwards, especially the left. Right femur swollen and bent with convexity outwards, the maximum bend being five inches above the patella. Kyphosis in dorsal region, lordosis in lumbar. No affection of cranium. Right leg one inch shorter than left; walks with a limp, but can do so without a stick.

The condition began ten years ago, and has been slowly progressive. She first noticed it coincidently with the menopause; it began in the left tibia, and for six years no other bone was affected.

VI.—*A Creasote Inhaler removed from the Œsophagus by Gastrotomy, with skiagraph showing the inhaler* in situ. By HERBERT J. PATERSON, B.C., F.R.C.S. (introduced by Mr. A. A. BOWLBY, C.M.G.) *Exhibited October* 23, 1903.

THIS specimen is chiefly interesting as showing the feats which can be performed in the way of swallowing by persons other than professional sword-swallowers. This cylindrical metal case, measuring four and a half inches long and almost three quarters of an inch in diameter, was swallowed by a gentleman suffering from phthisis. Inside the metal case was a glass inhaler containing a drachm of creasote. The accompanying skiagraph shows the metal case lying to the left of the spine, and with its long axis almost parallel to the vertebral column. Its presence could not be detected by abdominal palpation even under the anæsthetic. I opened the stomach and removed the case. It was impacted in the œsophagus, with about one inch of its lower end projecting into the cardiac end of the stomach. The patient made an uninterrupted recovery.

VII.—*Case of a Child with apparently Complete Absence of Sexual Organs.* By EDGAR BEAUMONT, L.R.C.P., M.R.C.S. *Exhibited October* 23, 1903.

GERALD Hastings N., born August 14, 1902.

With the exception of the abnormal formation that lends the chief interest to the case, the child's condition is quite normal.

The child is very intelligent—indeed, exceptionally so,—and of prepossessing appearance. The parents are both healthy, and there has never been any other trace of deformity in the family.

The child has cut eight teeth normally. The only special feature noticed in the child since its birth is that at times when micturating the urine dribbles away for a few moments and then passes freely, to perhaps revert again to the dribbling; but this is only occasional, and at other times the urine is passed freely and without effort.

VIII.—*A case of Sarcoma of the Left Supra-renal Body with Secondary Deposits in the Cranial Bones, with the specimen of a second case.* By HAROLD L. BARNARD, M.S. *Exhibited October* 23, 1903.

S. D., æt. 2½, fell upon his head six weeks ago. His cheeks and eyes began to swell next day. A week later he became listless, peevish, without appetite, and he vomited twice the same week. The swelling steadily progressed, and his eyelids became black with an extravasation of blood. Since his admission to the hospital three weeks ago the swelling has increased with great rapidity. The entire head is now enlarged, and the clouded eyes are being forced out of their sockets. Soft masses project from the forehead; the temples and the cheeks are smooth and white with pressure. The blood-count shows that there is moderate anæmia. The leucocytes are not increased above 8000, and the differential count reveals only a slight increase of lymphocytes.

In the left hypochondrium is a tumour which is probably a supra-renal one. It lies deeply and is irregular. There is gut in front of it, and it has no sharp edge or notch.

The specimen, which was obtained from an almost identical case, shows a soft hæmorrhagic sarcoma separating the pericranium and dura from the membrane bones of the skull. The supra-renal was the only other growth in the body.

IX.—*A Pedicle Trident for Multiple Ligature of Pedicles and Omentum.* By HAROLD L. BARNARD, M.S. *Exhibited October* 23, 1903.

THERE is no doubt that broad pedicles and large masses of omentum should be ligatured in several pieces, otherwise there is great danger of the central part of the mass retracting; the ligature becoming slack and finally slipping off.

The present methods of applying these numerous ligatures are unsatisfactory for these reasons—

1. They are slow.

2. There is risk of portions of the pedicle, but especially of omentum, being omitted.

3. The corresponding ends of ligatures become confused. The wrong ones are tied together. This leads to delay; or one or more ligatures are pulled out, when they are most difficult to replace accurately.

4. It is seldom known for certain whether the ligatures are interlocked or not.

5. The tissue is often cut through too near one or more of the ligatures.

Having experienced these difficulties, I had this trident made, which seems to obviate them all.

The trident.—The trident consists of a short stout handle, which gives a firm grip, but which can easily be sunk into the abdomen so as to raise the points out of the wound. The prongs are long and specially curved, so that when a pedicle has been transfixed deep in the pelvis, by sinking the handle the points may project from the wound in order to be threaded. The eyes of the prongs are lateral, so that all three may be simultaneously threaded by one needle

carrying four feet of silk or catgut. There may of course be more or less prongs to the instrument, but three is a convenient number, allowing the mass to be ligated in four pieces.

The method of application (Figs. 10 and 11).—The pedicle is caught with powerful clamp forceps, A, and the superfluous

FIG. 10.—The trident has transfixed the pedicle, has been threaded, and the thread has been pulled out ready for the trident to be withdrawn.

part cut off. The points of the trident are then passed below the clamp and by a little lateral movement easily transfix the pedicle. The short handle is sunk, and the points come well up into the wound. A large needle carrying four feet of No. 4 silk or catgut is then passed through all three eyes simultaneously. The length of the separate ligatures is

arranged by pulling out the silk between the prongs. (This stage is shown in Fig. 10.) The trident is then withdrawn and laid flat on the towels, and the corresponding ends are caught together by Spencer Wells'. (This stage is shown in Fig. 11.) The silk is now cut opposite each eye and the trident removed. We now have the whole pedicle divided between

FIG. 11.—The trident has been withdrawn. The corresponding ends of ligatures have been clipped with forceps. The trident now is cut free and the ligatures tied.

four ligatures, no part omitted, the ends not confused, and none of the ligatures interlocked. The ligatures are now tied. I usually tie and cut short the two outer ligatures first; then pull tight the first knot of the two middle ligatures, remove the clamp, tighten the knots, and finish in the usual way. Catgut can by this method be safely used for broad-ligament pedicles, and the drawbacks of silk avoided. The powerful kidney clamp acts as an angiotribe, and further ensures the ligatures being applied a safe distance from the end of the stump.

X.—*Diffuse Lipomatosis in a Woman without any Associated Pain.* By F. PARKES WEBER, M.D. *Exhibited January* 22, 1904.

ELLEN G., æt. 34, single, shows typical diffuse lipomata below the lower jaw, on the upper arms, and on each side of the front of the thorax near the costal margins. A typical bilobed diffuse lipomatous mass on the lower part of the back of the neck between the shoulders has recently been removed by operation. The patient has always enjoyed good health, and has been till lately employed in a confectioner's shop. She seems active and not excessively fat. There is no evidence of any disease of the thoracic or abdominal viscera or of the nervous system. The thyroid gland can be felt and is apparently not abnormally small. There are some varicose veins and cutaneous telangiectases in both external femoral regions. Menstruation is regular. She has been accustomed to take a little beer and occasionally whisky. The lipomatosis was first noticed about two years ago, soon after she had suffered from a dental abscess in the lower jaw, which led to a fistulous opening on the face. There has never as yet been any pain in connection with the lipomata. The patient has been treated by thyroid tabloids (only one a day); this treatment has been followed, she thinks, by a diminution in the size of the fatty masses.

The occurrence of typical diffuse lipomatosis in women is rare, though Dr. Weber is inclined to believe, with Dr. P. Thimm (*Monatshefte f. prakt. Derm.*, vol. xxxvi, p. 281), that at least some, if not all, of the cases described as examples of Dercum's adiposis dolorosa,* an affection which has been noted almost exclusively in women, are only varieties of diffuse lipomatosis. Thimm even suggests that adiposis dolorosa bears the same relation to ordinary diffuse lipomatosis which painful encapsuled lipomata bear to ordinary multiple encapsuled lipomata. It is questionable whether painful symptoms

* It is curious that Dercum in 1892 made no mention of any form of disease named diffuse lipoma when he wrote an account of, and first suggested a name for, the three first recognised cases of "adiposis dolorosa" (*Amer. Journ. Med. Sci.*, Philadelphia, 1892, vol. civ, p. 521), though one of the cases had the lipomatous mass at the lower part of the back of the neck so characteristic of diffuse lipoma. The well-known English account of diffuse lipoma by W. Morrant Baker and A. A. Bowlby was, however, only published in 1886 (*Medico-Chirurgical Transactions*, London, vol. lxix, p. 41).

similar to those which have been described as characteristic of adiposis dolorosa may not likewise occur in patients without any adiposis at all. Moreover, some of the published cases of adiposis dolorosa have commenced without any pain. One or two of the more recent cases, for which the diagnosis adiposis dolorosa has been suggested, have never had any pain to speak of in connection with their lipomata, and if the diagnosis be insisted on they will have to be termed *adiposis dolorosa sine dolore*; but, of course, in such cases it is always open for anyone to say that the pains of adiposis dolorosa will develop ultimately if the patients live long enough.

Among the few published cases of diffuse lipomatosis in women one of the most typical was accompanied by general wasting; it was under the care of Dr. Lejars, of Paris, and is figured by Launois and Bensaude in the *Presse Médicale* (Paris, June 1st, 1898, p. 296). These authors, on account of their theory of the origin of diffuse lipomatosis, name the disease "adeno-lipomatosis," and the title of their paper is "L'Adéno-lipomatose Symétrique à Prédominance Cervicale."

As, however, the French theory of there being a kind of semi-inflammatory development of fat, spreading from diseased lymphatic glands, cannot, in the present state of knowledge, be supported, Dr. Weber prefers the term "diffuse lipomatosis" to "adeno-lipomatosis." "Adiposis," on the other hand, merely means obesity, whilst "lipomatosis" implies a process of tumour-formation.

XI.—*Diffuse Lipomatosis in a Man with slight General Wasting.* By F. Parkes Weber, M.D. *Exhibited January* 22, 1904..

F. W., æt. 52, shows typical diffuse lipomata of neck, arms, pubic region, etc. There is slight general wasting, but no certain sign of disease of thoracic or abdominal viscera. The veins in the upper arms near the lipomatous masses are considerably dilated. The man was formerly a carman, but is now connected with a public-house. He has often been used for clinical demonstrations of diffuse lipoma. As a boy he was fat, and used to be called "tubby." He is married and has children. His father suffered from epileptic fits.

The lipomatous masses first appeared in 1868, following an injury (fracture of the right patella). His body has been getting thinner during the last six or seven years. He has never had pain connected with the lipomata.

In connection with the slight wasting there might possibly be a cirrhotic change in the liver, though this cannot be decided. Cases of diffuse lipoma with general wasting sometimes develop ascites, as in a case often seen by Dr. Weber, which was under the care of his colleague, the late Dr. Port, at the German Hospital in 1898. The patient was a "musician," æt. 66, with typical diffuse lipomata (neck, axillæ, upper arms) and general wasting. The ascites first appeared about May, 1898, and large amounts of ascitic fluid had repeatedly to be drawn off before the patient's death, which took place about January, 1899. There was no *post-mortem* examination. That case of Dr. Port reminds Dr. Weber very much of the case shown on October 23, 1903, at the Clinical Society of London (a man, æt. 47) by his colleague, Dr. Leonard Williams, the latter patient having since that date been tapped at the hospital for ascites. As far as Dr. Weber knows, however, there are no published *post-mortem* records to show whether the ascites which sometimes develops in patients with diffuse lipomatosis, is really due to associated hepatic cirrhosis (as one would suppose) or to some other cause.

XII.—*Tumour of the Liver in a Boy æt.* 10 *years.* By A. E. Garrod, M.D. *Exhibited January* 22*nd*, 1904.

WHEN the patient was first seen in August, 1903, he was said to have been ailing for a year, and to have had pain and swelling in the left side for three months. He is the fourth living child of a family of five. There were two miscarriages between the fourth child and this one.

In August, 1903, the liver was much enlarged, and reached below the umbilicus. It was firm, and not tender. One large and several smaller swellings were felt on the surface of the right lobe, near the costal margin. They were hard, and yielded no fluctuation. There was a chain of large

lymphatic glands on the right side of the neck; the other superficial glands were little, if at all, enlarged. The spleen extended about a finger's breadth below the costal border. There was, and is, double dacryocystitis with conjunctivitis, and interstitial keratitis more marked in the left eye. There are no changes in the fundi. The teeth are badly formed, but not characteristic of congenital syphilis.

Since August he has taken iodide of potassium almost continuously. The glands in the neck quickly subsided. The liver is considerably smaller, but the lump is, if anything, larger and more subdivided. The boy has lost weight (5 lbs.).

It is thought probable that the tumour is of gummatous nature, but the diagnosis of hydatid has also been advanced. The blood has been repeatedly examined. There is no leucocytosis and no eosinophilia.

XIII.—*Case of Total Paraplegia due to Caries of the Mid-dorsal Vertebræ, for which the operation of Costo-transversectomy has been Performed, with Complete Recovery.* By W. H. B. Brook, M.D. *Exhibited January* 22, 1904.

ARTHUR A., æt. 18. Angular curvature of the mid-dorsal region was first noticed in November, 1901; treated by est and a plaster jacket without benefit.

Symptoms of paraplegia came on in August, 1902; this became total in three months, and there was incontinence of urine and fæces, with bed-sores.

On November 8, 1902, the right transverse process of the eighth dorsal vertebra was removed, together with the head and neck of the rib, giving exit to a quantity of thick pus. The body of the eighth vertebra, which was practically destroyed, was removed with a sharp spoon.

Sensation began to return in twenty-four hours, and movement on the third day. In three months he had regained the power of walking, with complete recovery of sensation and control over the bladder and rectum.

XIV.—*A case of Chronic Periostitis (Syphilitic), with Skiagram.* By JOHN R. LUNN. *Exhibited January 22, 1904.*

FRANK F., æt. 29, an old soldier, was admitted into St. Marylebone Infirmary, August 9, 1902, and gave the following history:—When in India, 1895, he had syphilis. When he was at Netley, in 1900, he first noticed slight pain and swelling at the knees.

Present condition.—The lower ends of both femora are markedly and uniformly enlarged; no pain or tenderness on pressure. He has a scar on the glans-penis.

The left testicle is harder and larger than the right, but there is no loss of testicular sensation. He states that he had it tapped in 1896.

The right breast is distinctly enlarged, and some dilated veins are visible on its surface; no enlarged glands found in the axilla.

There is a general œdema of both feet and legs (after he has been up any time) as far up as Poupart's ligament on either side, which diminishes with rest in bed. No phthisis. Heart apparently slightly hypertrophied. Urine *nil.*

XV.—*A case of Ununited Fracture of Radius and Ulna.* By JOHN R. LUNN. *Exhibited June 22, 1904.*

JOHN F., æt. 74, was admitted into St. Marylebone Infirmary, October 13, 1903, with an ununited fracture of radius and ulna. The man stated that when he was thirty-six years of age he was splitting bullocks' hides for making shoes when his arm was caught between two rollers of the machine and broken. Both he and his wife remember seeing the bones protruding through the sleeve of the coat he was wearing. He was seen at the London Hospital, where he was advised to have his arm amputated, but he would not consent, and has managed to get his living ever since, until he was obliged to go into the workhouse in May, 1903.

The skiagram shows very well the ununited fractures.

XVI.—*Bilateral Enlargement of Testicles in a Boy æt.* 10. By W. G. Spencer. *Exhibited January* 22, 1904.

BOTH testes are swollen to be about of adult size, and firmly elastic, but not tender, the right vas is rigid and enlarged, the left less so. A sinus exists over the front of each testis, which has ceased to discharge pus, and appeared to be healing. *Per rectum* the vesicula on the right side is perhaps a little enlarged. The patient does not present any further signs of past or present disease.

An indefinite family history furnishes suggestions in favour both of tubercle and syphilis. The boy has been under observation since December 29th, and has been treated with mercury internally and locally, and with a little iodide. Meanwhile œdema of the scrotum and cord, which was marked on admission, has much diminished, and the testicles are certainly no larger, whilst the sinuses have certainly tended to heal.

P.S. (July).—The boy has been at a country home for six months, during which the disease has not made any progress.

XVII.—*A case of Ophthalmoplegia Externa with Blindness of Acute Onset, in a Child æt.* 5 *years.* By F. E. Batten, M.D. *Exhibited January* 22, 1904.

THIRTEEN weeks before admission to hospital the child had whooping cough, which was said by the mother to have been of moderate severity. From this the child recovered, and was well in about six weeks.

Two weeks before admission the child had headache, pain in the abdomen and across the shoulders, and was restless at night; there was no vomiting.

One week before admission to the hospital the mother noticed that the child could not see, and the child asked her mother to bring a candle because it was dark. At the same time it was noticed that the pupils were very large and she

could not move the eyeballs. There was no loss of consciousness; no convulsions.

On admission the child was well nourished, intelligent, and suffered no pain.

There was no ptosis, but complete ophthalmoplegia, with a slight divergent strabismus. The pupils were widely dilated, and did not react to light. There was complete blindness. There was slight optic neuritis, more marked in the right eye than the left.

There was no weakness of the muscles of the face, tongue, palate, or limbs. The child walked with the unsteadiness of a blind person, and there was a very slight inco-ordination of the movements of the right arm.

All the deep reflexes were abolished.

The superficial reflexes were present. The plantar reflex gave a variable response, sometimes definitely flexor, at other times a typical extensor response was elicited.

Within a week after admission the movement of the eyes had greatly improved, but the pupils remained dilated, and there was no return of vision.

Fourteen days after admission the movements of the eyes had become normal, the pupils were no longer so dilated, and the optic neuritis was much less. There was no return of vision, and the knee-jerks still remained absent. While in the hospital there was no rise of temperature, no headache, no vomiting, and the child was generally bright and intelligent.

It is suggested that the case is one of polio-encephalitis inferior affecting the region of the oculo-motor nuclei.

XVIII.—*Congenital Absence of the Phalanges of the Left Hand.* By Lawrie McGavin, F.R.C.S. *Exhibited January* 22, 1904.

THE patient, who is the sole member of the family afflicted by bodily deformity, is healthy in every other respect, excepting the presence of a small femoral hernia. The skiagram shows that the whole of the phalanges have been suppressed; the metacarpal bones, with the exception of the

first, are markedly deformed, being stunted and irregularly twisted, while the fourth and fifth appear to be fused together at their distal extremities.

Opposition of the remainder of the thumb can be performed, the patient being able to hold a needle while it is threaded. The case is a good example of the value of even a portion of the thumb, as the patient, who is married, has brought up a family of five children, and made all their clothes herself.

XIX.—*Translucent Cyst (probably Dermoid) of Root of Nose.* By Raymond Johnson. *Exhibited January 22, 1904.*

THE patient, a man æt. 28, first noticed a small lump at the root of the nose three years ago. No cause could be assigned, and the swelling slowly increased without pain.

At the present time the root of the nose is considerably enlarged, chiefly in a transverse direction, by a swelling which bulges in front of each inner canthus. The whole swelling gives a well-marked sense of fluctuation, and even in its most posterior part is very translucent. It does not pulsate, and no variation can in any way be produced in its tension.

Before the translucency of the swelling was detected the possibility of chronic abscess was entertained.

The varieties of translucent cyst which have been considered in the diagnosis are meningocele, mucous cyst of the upper part of the nasal cavity, hydatid, and dermoid. The last is believed to be the nature of the case.

Bland-Sutton figures a translucent dermoid of the root of the nose, and explains the origin of the cyst as due to sequestration of small portions of skin or epithelium during the development of the nasal bones in front of the cartilaginous fronto-nasal process. According to the same authority dermoids in this situation contain an oily fluid and are translucent, on account of the extreme thinness of their walls.

It is of interest that in this case the nasal bones appear to be displaced laterally by the cyst and to be in part wanting.

Subsequent operation proved the cyst to be a thin-walled dermoid containing opalescent fluid. During its removal the upper extremity of each nasal cavity was opened.

XX.—*A case of Multiple Aneurysm in which the largest, affecting the Brachial Artery, was excised.* By RAYMOND JOHNSON. *Exhibited January* 22, 1904.

THE patient, a man æt. 47, came under my care in July, 1902, at University College Hospital. There was a large globular aneurysm of the upper part of the right brachial artery. Small aneurysms were also situated on the left brachial artery at the bend of the elbow, and on the left popliteal artery. The man's general health had been good, and there was no history of syphilis or rheumatism. There was no evidence of valvular disease of the heart. The large aneurysm of the right brachial artery was excised. The operation was rendered difficult by the close connection between the sac and the adjacent veins and nerves.

At the present time, the patient having continued heavy work as a wheelwright for nearly eighteen months, the aneurysms of the left brachial and popliteal arteries remain *in statu quo*, and, although they still pulsate vigorously, have not increased in size since the patient first came under observation. The strength of the right upper limb is unimpaired, and there is a good pulse at the wrist. The patient's arteries generally do not appear to be extensively degenerated.

XXI.—*Two cases of Post-Diphtheritic Chronic Bulbar Paralysis.* By WILFRED HARRIS, M.D. *Exhibited January* 22, 1904.

CASE 1.—M. L., æt. 25. Four years ago she suffered from a slight attack of ulcerated sore throat. Six weeks afterwards noticed slight difficulty in swallowing, with nasal

regurgitation, and was found by her doctor to have paralysis of the soft palate. There was no affection of vision, nor any weakness of the limbs. Soon after this her lips became affected, so that she could no longer purse them up or whistle, but it was not until twelve months after the sore throat that much difficulty of articulation was noticed. There were slight occasional improvements, followed by relapse. Eighteen months after the onset of the throat affection she became unable to close the eyes.

Present state.—Almost complete paralysis of the orbicularis palpebrarum and orbicularis oris on each side, with all the other facial muscles normal. Complete paralysis of the soft palate, with paresis of the constrictors of the pharynx, and of the abductors and internal tensors of the vocal cords, with considerable wasting of the tongue. No ptosis or ocular palsy. During last few months occasional weakness and coldness of the hands. All deep reflexes brisk. Flexor plantar.

Electrical reactions.—Very diminished and sluggish to faradism in orbiculares oris et palpebrarum, with slightly better marked contractions to galvanism, K>A. Soft palate reacts only to galvanism, sluggishly, with K>A. No myasthenic reaction in facial muscles, or in deltoids or biceps

Case 2.—L. C., æt. 29, married. This case was ten years ago very similar in appearance to Case 1, but she has now completely recovered, after the paralysis had remained almost stationary for over six years.

Eleven and a half years ago she developed paralysis of the palate, with nasal regurgitation, three weeks after an illness which her doctor told her at the time was diphtheria. Soon after this she had difficulty in moving her tongue, slight diplopia, inability to close the eyes or to purse up the mouth, and some weakness of the fingers. Two years after the diphtheria she commenced to improve slightly; the nasal regurgitation and the diplopia passed off, but there still remained practically complete paralysis of the orbiculares palpebrarum and orbicularis oris, and of the soft palate, with some clumsiness of the tongue in eating.

The *electrical reactions* showed considerable diminution to faradism in the paralysed muscles, with normal electrical reactions in the other facial muscles. The condition of the face and soft palate remained much the same for another

* Both these cases are published in full in *Brain*, 1903, winter number.

three and a half years, or more than five years after the diphtheria. She then married, and soon after the birth of her first child noticed rapid improvement in the face, and at the present time there is no trace of weakness remaining in any of the formerly paralysed muscles, and the electrical reactions are now normal.

XXII.—*Congenital Elevation of the Shoulder.* By Charles R. Keyser. *Exhibited January* 22, 1904.

Grace J., æt. 9, was brought to hospital on December 17, 1903, because of deformity of the left shoulder-blade, which had been noticed one month. There was no history of accident or infantile paralysis. No other member of the family has a similar or any other deformity. The patient has always been "delicate," but has no definite symptoms.

On examination the left scapula is two and a half inches higher than the right, but the bone is of the same size as its fellow. Movement of the arm, both active and passive, is normal. There is no osseous bridge to be felt between the vertebral border of the scapula and the spine, nor is there any lateral curvature of the spine. The spinous process of the third dorsal vertebra, however, feels thicker than normal, and is apparently displaced slightly to the left. The inferior angle of the scapula is on a level with the interval between the sixth and seventh dorsal spines. There is no paralysis of any muscle. X rays show nothing abnormal, and the two arms are of the same length. The child's head is rickety in appearance, but there are no other signs of rickets, nor any other deformity. The teeth are slightly notched and ridged, as is commonly the case in ill-nourished children.

XXIII.—*Congenital Absence of the Fibulæ.* By Charles R. Keyser. *Exhibited January* 22, 1904.

Reginald S., æt. 2½, was brought to hospital because of congenital club-foot. On examination there is bilateral talipes vagus due to absence of the fibulæ. With X rays no

trace of a fibula can be seen on either side. About the junction of the middle and lower thirds of the leg there is a slight bending forwards of the tibia and a well-marked scar-like dimple in the skin over the crest of the tibia. There are only four toes present on each foot, one of the small toes being absent on each side. There are no other deformities present.

With a strong boot fitted with an outside iron the child walks very well.

XXIV.—*Two Cases of Osteitis Deformans.* By C. Gordon Watson. *Exhibited January* 22, 1904.

Case 1.—Man æt. 73, a driller. For about ten years has noticed an alteration in shape of his left thigh which has gradually increased; his head has also grown larger, and the soft hat which he wears and has worn for nine years is now much too small. His back has gradually become bent since the thigh began to bend. He suffers no pain, and has not had syphilis, rheumatism, or gout, and is otherwise healthy.

Present condition—Head.—Frontal eminences very prominent; temporal fossæ filled up; vertex high and prominent. Head is top-heavy, and held projected forwards. Maximum occipito-frontal circumference twenty-five inches.

Left femur.—Well-marked curvature forwards and outwards, and general increase of circumference. Surface of bone smooth. No shortening or lengthening of limb as measured from anterior superior spine to internal malleolus. A skiagram shows that the compact bone is uniformly thickened throughout, that the medulla is not encroached on, and that there is no irregularity of surface or periosteal thickening. All the other long bones are normal.

The sternum is distinctly thickened and prominent at the angle of Ludovitch.

There is well-marked kyphosis in the upper dorsal region, with the summit opposite fifth dorsal. The curvature is fixed.

Case 2.—A woman æt. 53, has noticed left tibia larger than right for "many" years. Eighteen months ago began

to have pain in left leg of shooting character, and thinks leg then increased in size. Suffers greatly from headache. No history of syphilis, gout, or rheumatism.

Present condition.—Marked anterior curvature, and thickening of left tibia. Skeleton otherwise normal. Skiagram shows uniform curvature of the shaft with no localised thickening, the increase of the compact bone is uniform, and the medulla appears neither unduly increased nor encroached on.

XXV.—*A Case of Fracture-dislocation in the Upper Cervical Region without Symptoms.* By William Henry Battle. *Exhibited January* 22, 1904.

A. A., a stout man æt. 56, a potman, was sent to me on May 20, 1903, by Mr. H. A. Easton with the intimation that the patient had a fracture of the axis as proved by a skiagraph which he had with him.

The history of the case was that the patient had fallen down a flight of stairs in his house about a month before he came to St. Thomas's Hospital, and had struck the back of his head on the wall at the bottom of the stairs bending the head forwards into the chest. He does not appear to have suffered very much in his own opinion as the result of this fall, for he went to work again next day, and continued to do it daily for a fortnight. There was, however, stiffness of the neck, and he had frequently to rest his head on his hands. He has also had some pain at the back of the neck and across the shoulders. There had been no dysphagia or paralysis of any kind.

He presented the appearance of a patient with rigidity—the result of spinal caries,—the nodding movements of the head were good, but he could not rotate the neck satisfactorily, and held himself with the head carried forward as in the photograph, not making attempts to turn it in the direction of anyone addressing him. The neck was thickened laterally in the upper cervical region, and there was some tenderness in both sides of the spine in this part. A prominence could be felt from the mouth on examination with the finger which corresponded with the displaced body of the second cervical.

A skiagraph taken by Dr. Greg confirmed in all particulars

the one forwarded by Mr. Easton. A fracture of the axis vertebra is seen passing through the body of that bone from behind the odontoid process downwards, so that the body of the axis remains in its normal relationship to that of the atlas

FIG. 12.

and odontoid process, whilst there is dislocation of the body of the axis forwards from its spine and the third cervical vertebra. Excepting for this local condition there was nothing worthy of remark. He had no symptoms, and considering that the fracture had been sustained a month before no special treatment was adopted. The rest in bed appeared to give some relief to the pain of which he complained on admission,

and there was less rigidity when he left Hospital on June 24, 1903.

The possibility of the occurrence of such a fracture as this without instantaneous death has hardly been contemplated, and it is only the X-ray photograph that renders proof possible.

Now that attention is drawn to the subject other instances of the unsuspected fracture of vertebræ in this region will be recorded, and, although at the present time they are curiosities, still they possess considerable importance from the medico-legal point of view, and their proper treatment is essential to recovery.

This patient was first shown to the Society in June, 1903.

XXVI.—*Fracture of both Pedicles of the Axis.* By EDRED M. CORNER. *Exhibited January* 22, 1904.

A CABMAN, whilst dozing in a chair on Sunday afternoon, nodded so much that he rolled out of it, hurting his neck. He kept at home for four days, and after a fortnight he came to St. Thomas's Hospital. The skiagraph shows the fracture. An additional feature of interest is that he complained of pain up his great occipital nerve, which is situated immediately above the injury.

There were no paralytic or sensory symptoms.

XXVII.—*Fracture of the Body and Laminæ of the Fifth Cervical Vertebra.* By EDRED M. CORNER. *Exhibited January* 22, 1904.

A YOUNG gymnast, in the course of his display on the stage, turned a somersault and hurt his neck. He was discharged from the Infirmary in ten days, and about three weeks after the accident he came to St. Thomas's Hospital. The skiagraph shows a comminuted fracture of the body of the fifth cervical vertebra, and also fractures of the laminæ.

There were no paralytic or sensory symptoms.

XXVIII.—*Congenital Absence of the Small Muscles of the Hands and Deformity of the Feet in Mother and Infant Daughter.* By H. Batty Shaw, M.D. *Exhibited February* 26, 1904.

L. B., æt. 20, a married woman, has had misshapen hands all her life, and has always experienced difficulty in executing the finer movements as in writing, buttoning clothes, etc. Inability to completely close the eyes was noticed by her parents when she was an infant. So far as she knows no other member of her family, other than her daughter, has been similarly affected. There is no evidence of syphilitic taint.

Her mental condition is excellent. Sensation is everywhere normal, nor is there any dissociational sensory disturbance. The knee-jerks are brisk and equal; there is no ankle clonus; the plantar response, when present, is flexor in type; the supinator and biceps jerks are not exaggerated. There is no sphincter disturbance. The confinement was protracted, but instruments were not used.

The frontalis muscle is exceedingly weak; only on extreme effort can any movement be detected. There is no concomitant action of the frontalis muscle when the eyes are raised in looking upwards.

The orbiculares palpebrarum are weak, so that the patient is unable to completely close the fissures; when asleep the sclerotics are always visible. There is possibly some weakness in drawing back the angles of the mouth. No other defect can be noticed in any of the cranial nerves. The pupils, though usually dilated, react to light and accommodation, and are equal.

When the hands are at rest the digits are held flexed; the index fingers are curved laterally, and seem to be more separated from the remaining fingers than is usual; the convexity of the curve is towards the preaxial side of the limb. The interosseous spaces and the thenar and hypothenar eminences are wasted; the base of the third metacarpal bone gives rise to a marked prominence on the back of each wrist. Flexion and extension of the wrists are readily performed. Flexion of each digit is fairly normal, being perhaps a little weakened from the impaired synergic action of the extensors of the fingers. The extensors of the fingers and thumbs are

a little weakened, especially those of the little fingers. Separation and approximation of the digits is only possible in extension and flexion of the fingers respectively; it is impossible to demonstrate the action of the lumbricales and interossei. True apposition of the ball of the thumbs to the ends of the remaining digits is impossible; they can only be approximated by combined flexion of the thumbs and fingers; it is impossible to demonstrate any action attributable to the small muscles of the thenar or hypothenar eminences.

FIG. 13.

Photograph by E. S. Worrall.

Neither by faradic nor by galvanic currents can any of the muscles which fail to respond to volitional impulses be made to act. The changes in the hands are quite symmetrical, though more marked in the right hand; the patient writes with the left. No other muscles of the limbs or body are paralysed, nor is there any fibrillary twitching of the muscles. Radiograms show that the digit above described as a thumb is really a thumb being provided with a metacarpal bone and two phalanges. There is no other abnormality, but slenderness of the fourth metacarpal bone.

The only abnormality in the feet is that the plantar

arches are more marked than usual and the middle toe in each foot is depressed below the level of the others. There is no paralysis to be detected in the small muscles of the feet.

N.B.—The infant daughter of L. B., æt. 2 months, presents similar deformities in the hands and feet. The facial muscles appear to be normal. The infant reveals no other disturbance of the nervous or muscular systems.

The defects in the hands in mother and daughter are apparently due to a congenital defect of the anterior horn cells of the sixth and eighth cervical, and possibly first dorsal, spinal segments, the extreme weakness of the mother's frontalis muscle being possibly due to a similar defect in that part of the nuclei of the third nerves which subserve the control of the upper facial muscles.

XXIX.—*Sporadic Case of Friedreich's Disease.* By Bertram Abrahams, M.B. *Exhibited February* 26, 1904.

F. I., æt. 13, the third of eight children, of whom the others are perfectly healthy. No family history of neurosis; no intermarriage. Patient had had no illness beyond childish ailments till five years ago, when some unsteadiness in standing with the eyes shut was noticed. After this he began to be restless at night and to fall out of bed. The other symptoms—of which the ataxy of the legs is the one chiefly complained of—have been increasing progressively and somewhat rapidly during the past three years.

Present condition.—An intelligent boy, but owing to frequent absence is only in the third standard. There is some weakness of the neck muscles, so that the head is habitually hung forward. It is constantly moving in short jerks; after any exertion the movements become more typically choreiform.

There is slight lateral nystagmus, better marked in the left eye. The pupils are widely dilated, but react briskly to light and accommodation. The fundi are normal.

He can stand, with some considerable swaying, with his eyes shut and his feet far apart. As soon as he brings his feet together he collapses entirely. The gait is ataxic upon

a wide base, and is described by his mother as being like that of a drunken man. There was at one time some tendency to fall over to the left, but this is not now so marked. There is slight extensor spasm at the knees, which are accordingly kept a little stiff.

Speech is nasal, slow, slurred, and monotonous.

There is well-marked ataxy of the hands, particularly seen when fine movements are attempted.

There is no obvious anæsthesia, but there is some analgesia of the legs, more especially the left. The muscular sense does not appear to be markedly affected. Both knee-jerks are lost. The plantar reflexes are of the extensor type, and they are much brisker on the left side than the right.

There is well-marked pes cavus on both sides. There is distinct dorso-lumbar scoliosis.

It is proposed to try the effects of graduated exercises such as those devised by Fränkel for the relief of the ataxy of tabes.

XXX.—*Morbus Cordis. Pulmonary Regurgitation associated with Mitral Stenosis.* By J. Porter Parkinson. *Exhibited February* 26, 1904.

THE patient is a girl æt. 19, has had six attacks of acute rheumatism, and shows deformities of the finger-joints with ulnar deviation of the fingers. She was admitted into the London Temperance Hospital for dyspnœa and precordial pain.

The cardiac impulse was most marked in the fourth intercostal space just internal to the nipple. There was on admission increase of the heart's dulness to the right side extending a finger's breadth beyond the right edge of the sternum; the other limits of the heart, as ascertained by percussion, appeared normal. At the apex there were presystolic and systolic murmurs with a short sharp first sound, and the second sound was inaudible here. At the base was heard a loud double murmur most marked in the second intercostal space on the left side close to the sternum, the diastolic murmur being well conducted downwards towards the manubrium sterni.

The pulse was of normal frequency, small, regular, and compressible.

Beyond slight enlargement of the liver there were no other abnormal physical signs, and there was no dropsy.

There is little doubt that this patient is suffering from mitral disease, but the cause of the basic murmurs is not so clear, the absence of any water-hammer character in the pulse and of any signs of enlargement of the left ventricle seem to contra-indicate the presence of aortic regurgitation, and if this be correct one is driven to conclude that the diastolic murmur is due to some reflex through the pulmonary orifice, probably resulting from dilatation of the pulmonary artery, a condition which is occasionally found in cases of mitral stenosis by *post-mortem* evidence, and it is probable that the condition occurs much more frequently than that evidence proves, for an orifice which during life has been sufficiently stretched to allow leakage, may appear normal after death.

XXXI.—*A case of Enlargement of the Bones of the Cranium, Jaw, and Thorax (? Syphilitic).* By W. G. Stone, M.D. *Exhibited February* 26, 1904.

C. R., a lad of 18½, with the appearance of one of lesser age and much emaciation. There is a bony prominence in the right temporal region, which has been observed by the patient's parents for two years; it has decreased very noticeably under antisyphilitic treatment during the last two months. A swelling of the lower jaw has also decreased, and, while two months ago there was practically no movement at the temporo-maxillary joint, the patient can now separate the teeth. The thorax shows considerable bony enlargement, especially of the sternum, and great deformity. His parents report that he has always been "pigeon-breasted," but that a greater degree of deformity has appeared during the last two years. There is well-marked evidence of disease at the apices of both lungs, especially the left; no tubercle bacilli have yet been found in the sputum. In the left rectus abdominis muscle there is a well-defined flattened mass.

The mother has had twelve children, five of whom died before they were six months old. She has had no miscarriages.

The patient died in St. Thomas's Hospital, not long after being shown to the Society. There was some disease of the liver found *post mortem*, but no satisfactory evidence of its nature has been obtained from sections yet cut.

The spleen showed some destruction of the Malpighian bodies, and some infiltration with epithelioid cells.

The *kidneys* were very much diseased, and showed great cellular infiltration and increase of the fibrous tissue.

The *sternum* showed infiltration of the marrow by epitheloid cells, and a large mass attached to the sternum was composed of fibrous tissue containing numerous foci of small cell infiltration. There was also a mass attached to the pericardium, composed largely of epithelioid cells.

The lungs were extensively diseased, and the condition resembled somewhat that known as "white pneumonia."

There was no caseation in any part such as one would expect in a case of syphilis, and the mass on the pericardium bore a striking resemblance to sarcoma, but the former diagnosis of the case appears on the whole the most probable.

The case is being further investigated by Dr. Powell White, on whose preliminary examination of the organs the above report is based.

XXXII.—*A case of Achondroplasia with Spinal Curvature (? Rachitic).* By Charles R. Keyser, F.R.C.S. *Exhibited February* 26, 1904.

GEORGE A., æt. 15 months, was brought to hospital on February 18 for "rickets." On examination the child showed the typical appearances of achondroplasia. He is the first and only child of healthy parents, and is bright and intelligent for his age. The hair is plentiful, fine, and soft. The head is very large, of brachycephalic type, and measures 18½ inches in circumference. The fontanelles are large and widely open, and there is a slight degree of craniotabes present in the occipital region. The frontal and parietal bosses are exaggerated, and the forehead somewhat over-

hangs the face, which appears small. The bridge of the nose is markedly depressed, owing presumably to synostosis of the basi-occipital and basi-sphenoid portions of the skull. There are six teeth present, and these were erupted in the normal order. The disproportion between the length of the body and the limbs is most marked; the child's height is 23

FIG. 14.

inches, the length from the occiput to the coccyx being 11 inches, whereas the lower extremity measures only $7\frac{1}{4}$ inches. Of this, the femur is $4\frac{1}{4}$ inches long and the tibia 3 inches. In the upper extremity, from the tip of the acromion process to the external condyle of the humerus measures $2\frac{3}{4}$ inches, and the forearm also $2\frac{3}{4}$ inches. The hands, when the arms are outstretched, only just reach below the umbilicus. The fingers show the typical appearance of the disease, the index and middle fingers curving to the radial and the ring and little fingers to the ulnar side, so that the interval between

the points of the middle and ring fingers is much greater than that between those of any other pair of digits. There is also present in a slight degree the abnormal movements of the fingers commonly seen in achondroplasia; thus the little finger can be made to touch the back of the forearm without difficulty, but the other fingers cannot be hyperextended quite so far as this.

In the lower extremities there is a certain degree of genu valgum with a good deal of lateral movement at the knee; there are also marked annular folds in the skin, as if there was a superabundance of tissue for the length of the limb.

The bones of the limbs are very slightly curved and the epiphyses are not enlarged; there is no tenderness about the bones. The lower ribs are much everted, and the abdomen is prominent; Harrison's sulcus is present, and the upper part of the chest is somewhat constricted. There is practically no beading of the ribs. When the child sits up there is a prominent antero-posterior curve of the spine in the dorsi-lumbar region; on lifting the child up or on placing him in the prone position the spine becomes quite straight. There is not at any time any tenderness or rigidity about the spine; no lordosis is present.

The condition of the thyroid gland is difficult to ascertain in so small a patient, but there does not seem to be any abnormal deficiency in the lower and anterior part of the neck.

The child has been brought up by hand on milk, and has had no patent foods or biscuits, etc., of any kind. The mother has noticed that there is excessive sweating about the head at night. One point of interest is in connection with the physical appearance of the child's father. He is only about 4 feet 8 inches in height; but although his limbs are very short, they do not seem out of proportion to his body, and the shape of his head and face does not suggest achondroplasia.

Achondroplasia, or, to use a better term, chondro-dystrophia fœtalis, is now generally regarded as a disease quite distinct from rickets, and it is therefore of interest to note in this case the marked spinal curvature similar to that seen in rickets, the appearance and shape of the chest and ribs, the excessive sweating about the head at night, and other signs which are so frequently associated with rickets.

XXXIII.—*A case of Pyopneumothorax due to Phthisis; Operations on the principles of Estlander's (Thoracoplasty), healing with an Aërial Fistula.* By Edred M. Corner. *Exhibited February* 26, 1904.

W. C., æt. 32, was admitted to St. Thomas's Hospital on February 25, 1901, with phthisis and a right-sided pneumothorax. On February 27 air and pus were aspirated; the temperature was 102·4°.

On March 2 (temp. 101·4°) part of the seventh rib on the right side were resected. The temperature remained up for a fortnight before it became normal. The discharge continued, and the lung would not expand, so that on June 1 an Estlander's operation was done, portions of the fourth to the ninth ribs being excised. In all about thirty to thirty-two inches of rib were removed. The wound healed well except for a cavity under the scapula, at which place the skin could not fall in. Patient had improved markedly in his general condition.

On October 5, 1901, a further attempt was made to close the cavity under his scapula. More of the ribs, fourth to the ninth, were removed. After this operation he improved rapidly.

On May 17, 1902, the incision was again opened up. The lung and pleura had now expanded everywhere except under the scapula. The lower third of the scapula were removed. One or two stitches were put in uniting the skin to the visceral pleura. Part of the tenth rib was removed. Patient continued to improve until September 1, when he was readmitted.

On November 7 his left testis was excised for tubercular disease. During November, 1902, he had unexplainable attacks of malaise and vomiting. He also complained of pain in the lumbar region of the back. He has had a fistula in ano for years.

In his history it is ascertainable that his lungs were first attacked early in 1898, in the November of which year he had an hæmoptysis. At this time he was a champion middleweight boxer. As he is now he presents marked scoliosis. The skin of the right side of the chest has fallen in and moves with the diaphragm. All the wounds are soundly healed, except in one place where there is an aërial fistula in connec-

tion with the lung, through which expired air can be forced. In many ways he is better, the vomiting has ceased, he sleeps and eats better, and has no cough. But he is losing weight, from 11 st. 7 lbs. to 10 st. 10 lbs. in six months. The liver is enlarged, and there is albuminuria.

The case presents several points of interest: the man has undergone several severe operations to close the empyema cavity; the whole condition has healed perfectly except for the aperture in the lung and visceral pleura, which probably gave rise to the original pneumothorax. In consequence there is now an aërial fistula. The tubercular trouble has extended to the testis, and to all appearances the man is steadily going downhill.

From the surgical point of view the following facts may be pointed out:

1. The subdivision of the operation of Estlander into two or three parts, done with intervals of time in between.
2. The difficulty of getting the skin, etc., close to the spine to fall in, and so heal the empyema.
3. The necessity of removing the lower third of the scapula to obtain the result.
4. The aërial firstula connected with the lung.
5. The progress of the tuberculosis.

XXXIV.—*Cyst arising in Connection with the Organ of Giraldes.* By Donald Armour, M.B., F.R.C.S. *Exhibited February* 26, 1904.

G. B., æt. 20, nine months ago noticed a swelling in connection with his right testis. It has always remained the same size. It is only painful when doing heavy work. Otherwise he is not conscious of its presence. Cause of origin unknown. No history of injury, gonorrhœa, or syphilis.

There is a swelling the size of a large marble at the upper end of the right testis, in front of the spermatic cord. It is translucent. It can be moved upwards a quarter of an inch from the upper end of the testis. The globus major of the epididymis can be felt distinct from the swelling.

XXXV.—*Contracture of Hip and Knee treated by Elastic Traction.* By T. H. Openshaw, C.M.G. *Exhibited February* 26, 1904.

H. H., female æt. 31. Infantile paralysis of the right lower extremity. Sudden onset at the age of two years. Contracture of the right knee-joint for fifteen years. Treated at various hospitals till nine years of age, then walked with hand on knee till fifteen. Since then has been obliged to use a crutch. Came under my care July, 1903, with hip flexed, knee contracted to an angle of 120°. Slight power of flexion of knee, none of extension. Calf muscles atrophic, talipes calcaneus, leg one and a half inches short. Hessing's appliance with elastic traction at hip and knee and ankle put on October 3. End of November knee straight, after some synovial effusion. Since the instrument was applied has only required the use of a stick. Confidence in walking and the power in the leg is slowly increasing. February 1, 1904, contraction of hip corrected, pelvic band and elastic traction removed. Since Christmas patient has been able to extend the knee when in bed voluntarily, after fully flexing it. This she could not do before treatment, pointing conclusively to the regaining of muscular power in the quadriceps muscle.

XXXVI.—*A very large Femoral Hernia.* By William Henry Battle. *Exhibited February* 26, 1904.

THE patient, a woman æt. 55, was admitted to St. Thomas's Hospital on February 18, 1904, with a large hernia which presented the appearance shown in the illustration. It extended from the right groin to the knee, was pear-shaped, and irreducible. At its greatest circumference it measured more than the thigh on which it was lying, and caused great discomfort from its size and weight. The surface was eczematous in patches, and the skin very thin.

The hernia had commenced seventeen years before, and had increased much more rapidly of late.

The woman herself was somewhat emaciated, and suffered from a chronic cough, which made the hernia increase in size, and necessitated the postponement of any question of operation. There was no evidence of valvular disease, or of disease of the lungs.

Note.—All attempts at reduction by means of rest in bed, improvement of the cough, and the application of bandages appeared to be without result in diminishing the size of the

FIG. 15.

hernia, but the skin covering it became normal. She was anxious for operation, and the hernia was reduced on March 25, although with some difficulty, the patient being under the influence of chloroform.

The contents of the sac consisted of several feet of small

intestine, the cæcum and appendix vermiformis, about a foot of large intestine, and the gall-bladder. The small gut was reduced with comparative ease, but in order to effect reduction of the other contents it was necessary to divide Poupart's ligament.

Closure of the abdominal opening after excision of the sac and some of the skin was facilitated by the use of a staple inserted into the bone. The impression given when the operation was completed was that the diaphragm was compressed by the return of contents of the abdomen, which had long been absent from their place, and that the abdominal muscles were much more resistant than had been expected.

Two days after operation the patient died with pulmonary symptoms. At the *post-mortem* examination the local condition was quite satisfactory.

The case is interesting for various reasons. In the first place it is the largest femoral hernia of which a record can be found.

2. There had never been any operative interference with the part, *i. e.*, no abnormal scar tissue had formed in the line of resistance to pressure from within the abdomen, as in most cases of large femoral hernia.

3. The gall-bladder has not been previously met with in the sac of a femoral hernia.

XXXVII.—*Case of Movable Knee-joint Three and a Half Years after Operation for Extensive Tuberculous Disease.* By F. J. Steward, M.S., F.R.C.S. *Exhibited April* 22, 1904.

AMELIA W., was admitted into the Great Ormond Street Hospital on August 22, 1900, and was then one year and seven months old.

The right knee joint became tuberculous eight months before admission, and the disease rapidly progressed. The joint had been opened and scraped by another surgeon three months before admission, but this operation did not stop the progress of the disease, in fact it resulted in the formation of a sinus.

On admission the right knee was fixed and flexed almost

to a right angle, very tender, and much swollen. A scar crossed the front of the joint, and at its inner extremity a sinus communicating with the joint cavity was present. There were no other signs of tuberculosis, and no signs of congenital syphilis present.

Operation (August 25).—Under chloroform the joint was opened by a transverse incision, the patella being divided. The whole of the synovial membrane, which was extensively diseased, was dissected away. The cartilage over the outer condyle of the femur, the patella, and the outer tuberosity of the tibia was healthy and was left, but that over the inner condyle of the femur and the inner tibial tuberosity was much eroded, and was therefore in great part removed. A large carious patch in the inner condyle, three quarters of an inch in diameter, and extending to a depth of one and a half inches, was thoroughly curetted and afterwards plugged with pieces of decalcified cancellous tissue and washed iodoform. A smaller carious patch on the internal tuberosity was similarly treated. The anterior crucial ligament was destroyed but the posterior was in great part saved. The patella was then sutured, the sinus excised, and the wound closed. Primary healing took place, and the child left the hospital in a plaster-of-Paris case.

The child was seen from time to time, and the plaster changed. In August, 1902, *i. e.* two years after the operation, as no heat or other sign of recurrent disease had been observed subsequent to operation, all splints were discarded. At this time there was a very slight degree of mobility; this has slowly but steadily increased up to the present time.

The present condition of the limb is as follows:

There is no heat, tenderness, or other sign of disease; the muscles are less developed than those of the sound limb, but there is no shortening; the leg can be completely extended, and can be flexed almost to a right angle; there is no lateral mobility whatever.

According to the mother the child can run, skip, etc., like other children of her age, and never complains of the knee in any way.

XXXVIII.—*Case of Polycythæmia with Enlarged Spleen and Chronic Erythromelalgia of the Left Foot.* By F. Parkes Weber, M.D., *Exhibited April* 22, 1904.

THE patient, Mrs. Sabina R., æt. 36, a Jewess from Roumania, has been under observation for a considerabe time on account of erythromelalgia (see description in the *British Journal of Dermatology*, February, 1904, p. 70), but the presence of polycythæmia with splenomegaly has only recently been recognised. She came to England ten years ago, and up to that time had enjoyed fair health. She never had malaria. Both her parents reached old age. Her husband, a traveller, is living and healthy, and she has two children, both living and healthy, aged seven years and nine years respectively. Before these children she had two abortions at the third month. After her last confinement (seven years ago) she suffered from "inflammation of the womb," and the whole of her left lower extremity was swollen for a month.

Three or four years ago she commenced to have "burning" in both feet during summer, and gradually she became unable to put on her boots without pain. For the last two years she has suffered much from headache and feelings of giddiness and prostration. On account of the foot trouble she has been practically confined to bed for eighteen months. When Dr. Weber first saw her in the summer of 1903 her feet were turgid with blood (some of the toes were purple), painful, hyperæsthetic, hyperalgesic, and moist with sweat. All the signs were much more marked in the left foot, which was objectively the hotter of the two. Considerable improvement occurred, but the left foot has not completely recovered. At the present time the erythromelalgia is practically limited to the left foot. Even when the patient is lying down and resting one can always observe livid patches of skin, which are sometimes apparently slightly swollen, on the big toe and along the inner border of the foot, and this region is tender to pressure; but when she sits up with the feet in a dependent position the whole left big toe becomes blue and painful and hot to the touch. There are two or three purple patches of skin on other parts of the left lower limb, which, Dr. Weber thinks, may be regarded as minute erythromelalgic islets.

There is no distinct cyanosis of the face and extremities, such as has been noted in most other cases of polycythæmia with splenomegaly, although the tongue, and sometimes the fingers also, are of a bright red colour with a bluish tinge, resembling the colour of raw butcher's meat. No disease can be detected in the heart or lungs. There is no dyspnœa. The cardiac apex-beat is in the fifth left intercostal space, internal to the nipple line, and the area of cardiac dulness is not increased. The radial pulse is about 88 in the minute and regular (though the rate is markedly affected by any mental excitement); it is of medium volume and generally rather increased tension. By abdominal palpation nothing abnormal can be detected except enlargement of the spleen, which is felt rather hard and extending two finger-breadths below the costal margin. Menstruation regular. Some tendency to chronic constipation. The urine is at present abundant, pale, of specific gravity about 1010, and free from sugar and albumen; but on a former occasion a trace of albumen was noted.

Examination of blood: Hæmoglobin, about 125 per cent. of the normal; red cells, about 9,000,000 in the c.mm.; white cells, about 8100. The differential count (Dr. G. L. Eastes, April 13) of white cells gives small lymphocytes 17·25 per cent., large lymphocytes 8·5 (total lymphocytes 25·75), polymorphonuclears 73·75, eosinophiles 0·5. During a count of 400 white cells one mast cell was found. No myelocytes or erythroblasts were detected.

On a subsequent occasion (April 19, late afternoon) Dr. J. H. Drysdale kindly examined the blood from the patient's finger and found that the red corpuscles numbered 8,660,000 per cubic millimetre, and the white cells 9000. This confirms the previous counts in regard to the polycythæmia. Dr. Drysdale also reported that the differential count of the white cells (polymorphonuclears 77·6, lymphocytes 18·5, large mononuclears 3·5, and eosinophiles 0·3 per cent.) did not differ much from that in ordinary persons.

There is slight deafness, possibly due to dry catarrh, and occasionally a subjective "roaring" sound is complained of. Knee-jerks obtained with some difficulty on both sides. There is slight wasting of the calf of the left leg (2 cm. difference in circumference, 14 cm. below knee-caps). A radiogram shows that the bones of the toes and distal part of the tarsus in the left foot give a decidedly fainter shadow to Röntgen's rays than in the right foot.

In many respects the present case resembles that recently brought before the Society by Drs. Weber and Watson, in which, however, there was no erythromelalgia (March 11, 1904). The association of splenomegalic polycythæmia with erythromelalgia has already been noted by W. Türk, of Vienna (*Wiener klinische Wochenschrift*, 1904, Nos. 6 and 7).

Treatment.—The acute erythromelalgia in the present case rather suddenly subsided whilst faradism was being tried, but nothing has seemed to influence the chronic condition. For various reasons the patient is now to be put on a diet consisting chiefly of milk.

Addendum.—The general condition appeared to remain uninfluenced by treatment, and the milk diet was not long continued owing to great objection on the part of the patient. On the morning of May 30, 1904, an examination of the blood showed hæmoglobin 165 per cent. of the normal; red corpuscles 10,600,000 in the cubic millimetre, white cells 7200. Small doses of arsenic (two to three drops of Fowler's solution three times daily) had been tried for the three weeks preceding this blood count, but were then discontinued. Dr. G. L. Eastes kindly examined blood-films taken on May 30, and confirmed the absence of myelocytes, of erythroblasts and of any poikilocytosis. The differential count of 300 white cells gave small lymphocytes 26·5 per cent., large lymphocytes 4·0, polymorphonuclears 68·8, eosinophiles 0·7.

XXXIX.—*Case of Firm Ankylosis and Contracture of Left Knee treated by Elastic Steel Bar Traction.* By T. H. Openshaw, C.M.G. *Exhibited April* 22, 1904.

J. S., æt. 15, came under my care at the London Hospital in January, 1904, with close fibrous ankylosis of the left knee and contracture to an angle of 112°.

Knee first became painful and stiff when five years of age. Treated with plaster of Paris and Scott's dressing. Abscesses formed; burst. Sinuses discharged, and knee became flexed.

Now two cicatrices above external condyle, and one over ligamentum patellæ.

During 1903 leg has been getting more flexed. There was, when first seen, the faintest possible trace of movement at the knee. Muscles of thigh are wasted. No paralysis or other deformity. Patient walked well, with the toes on the ground, but the pelvis dropped four inches in order that the toes might reach the ground. There was marked left dorsal lateral lumbar curvature.

On February 26 the knee was put up in Hessing's splint with elastic steel bar traction, the knee being at an angle of 112°.

On March 1 the angle was 120°, on the 4th 125°, on the 10th 135°, on the 17th 145°, etc., etc.

On April 15 it was 180°.

There has been practically no heat and no pain during the process. The patient has walked about the whole time. There is more movement at the knee than when the treatment was commenced. The steel bar is now replaced by elastic traction bands.

XL.—*Case of Arthritis of Knee, following Fracture of Femur, improved after Removal of Pressure by means of Splint.* By T. H. Openshaw, C.M.G. *Exhibited April* 22, 1904.

J. H. first came under my care October, 1903, at the National Orthopædic Hospital, with enormous bony outgrowths of the right knee, acute pain, and inability to stand or walk upon the knee. He is a man of extreme muscular development, an acrobat. Whilst performing with an elastic knee-cap on the knee the femur fractured. It is now united, with some deformity. The arthritis of the knee-joint developed after the injury. A splint, by means of which the weight of the body was transferred from the pelvis to the ground, was applied, and the knee-joint thus given rest. The pain, the swelling, and the bony outgrowths have slowly decreased in size and severity. He is now able to walk all day long without discomfort. He has no sign of any disorder of sensation. He has had syphilis, and is not rheumatic.

XLI. — *Case of Early Acromegaly.* By WILFRED HARRIS, M.D. *Exhibited April* 22, 1904.

A. L., a young girl, æt. 20, previously in domestic service, has suffered for some years past from headaches, which have been especially severe for the last twelve months. For the last two years has frequently suffered from slight epileptiform attacks, sudden pain through the eyes from left to right, followed by loss of consciousness for about half an hour, and talks at random, and is otherwise "queer" for some little time after. Her memory is bad, and her temper has become very irritable during last two years.

During the last twelve months her brothers have chaffed her on account of her being unable to make her teeth meet. The lower jaw is markedly underhung, the lower incisor teeth being a third of an inch in front of the upper teeth. The face is long and oval, with large nose and lower lip. The tongue is moderately large. The hands are large, with thick spudgy fingers, size 8, though she used to take 6½ gloves. A ring on one of her fingers has become obviously tight. The spine and chest show no marked alterations. The visual fields are normal. Optic discs normal. No glycosuria or albuminuria. Catamenia have almost ceased during last six months.

XLII.—*A Case of Congenital Heart Disease. ? Patent Ductus Arteriosus.* By LEE DICKINSON, M.D. *Exhibited April* 22, 1904.

THE patient is a delicate-looking, but well-developed young woman of 27, married, and the mother of three children. Heart disease is known to have existed since early childhood; there is no history of rheumatism. She first came under my care in December, 1896, at which time she was suffering from chlorosis, albuminuria, and œdema of the legs. The cardiac murmurs and thrill were then much as now, but even more pronounced. Last February she reappeared at St.

George's complaining of attacks of faintness, which had been worse since her last confinement three months before. After a few weeks' rest in the hospital she regained fair health, and she is now going about as usual. The albuminuria persists, but there is no œdema of the legs except what may be due to varicose veins. The pulse is of low tension, and the arteries are not thickened.

Heart.—The heart is slightly enlarged, more to the left than to the right, the apex being in the fifth space just inside the nipple line, the impulse heaving. There is appreciable pulsation in the episternal notch, and the prevascular dulness is somewhat extended on the left, probably indicating dilatation of the pulmonary artery.

The murmur and thrill were thus described by Dr. W. L. Ascherson, one of the medical registrars: "A thrill, the intensity of which seems diastolic in time, is felt in the second and third left spaces close to the sternum. In the second left space close to the sternum is an exceedingly loud rumbling murmur. It seems to begin with the systole, but occupies not only the systole, but practically the whole diastolic interval, and is therefore continuous. No second sound is audible in the pulmonary region. The murmur is conducted all over the præcordium, masks the first sound at the apex, and is heard in the aortic area; it is also audible down the spine at the back, but not over the abdominal aorta. No second sound is heard in the aortic region, but an aortic second sound is audible in the neck."

The only addition which I would make to this note is that sometimes, at any rate, the murmur is double, the shorter portion, which is definitely systolic, being of a more blowing and less rumbling character than the rest; but always the whole cardiac cycle is occupied by a murmur or murmurs.

Remarks.—This is almost certainly a case of congenital heart disease, but the obtrusive character of the physical signs is out of all proportion to the severity of the lesion. It is more than probable that some malformation exists at the orifice of the pulmonary artery, allowing of regurgitation perhaps as well as obstruction.

The continuous murmur, however, cannot be explained in this way, and there is certainly no very serious pulmonary obstruction, for the patient is well-developed, reasonably active, not cyanosed, and, at the age of twenty-seven, she is free from phthisis.

The chief interest of the case consists in the question of patency of the ductus arteriosus.

Perhaps the signs which are most generally held to be characteristic of patent ductus arteriosus are a late systolic murmur and thrill in the second left interspace followed by an accentuated pulmonary second sound, but in some cases that have come to a *post-mortem* examination there has been a diastolic murmur also, or a continuous purring throughout both systole and diastole, the pulmonary second sound being indistinguishable. It is impossible, however, to be confident about any signs as being proper to patent ductus on account of its almost invariable association with other congenital lesions, of which the simplest and commonest is stenosis of the orifice of the pulmonary artery, associated or not with dilatation of the trunk of the vessel.

A comparatively simple case of patent ductus arteriosus is recorded by Dr. Greenhow in *Clin. Trans.*, vol. ix. There were two murmurs in the pulmonary area—a harsh systolic murmur ending abruptly, accompanied by a thrill, and a continuous humming murmur during all the rest of the cardiac cycle. The systolic murmur was traced after death to the pressure of enlarged glands upon the pulmonary artery, but the continuous humming murmur was attributed to the patent duct and the flow of blood through it from the aorta into the pulmonary artery.

In the presence of a continuous humming murmur Dr. Greenhow's case seems to have been very similar to the one now brought forward, and upon which the opinion of the Society is sought.

Addendum.—Dr. Frederick Taylor reminds me that the late Dr. Hilton Fagge published the complete history of a case of patent ductus arteriosus, which case should certainly be studied by anyone interested in the subject (*Guy's Hosp. Rep.*, vol. xviii, 3rd ser., p. 23). See also Dr. Frederick Taylor's Clinical Lecture in the *Guy's Hospital Gazette*, 1901, pp. 197—221.

XLIII.—*Case of Congenital Malformation, Upper Limb and Ear.* By R. P. Rowlands, M.S. *Exhibited April* 22, 1904.

R. W., æt. 32. Skiagram by Dr. Graham shows—

1. Absence of radius, of upper part of humerus, and of two metacarpal bones.

2. *Presence* of only four carpal bones: os magnum, pisiform, unciform, cuneiform.

3. *Presence* of only third, fourth, and fifth metacarpal bones. The third and fourth are articulating with first phalanx of a finger which is probably the fourth.

The clavicle and scapula are both poorly developed, and the former is very low at its sternal end.

The elbow is flail, and the shoulder-joint is malplaced.

Maldevelopment of ear showing on left side—

1. Complete facial paralysis.
2. Complete *nerve* deafness.
3. Ill-developed ear represented by (*a*) a funnel-shaped depression half an inch deep; (*b*) piece of cartilage representing tragus and (?) antihelix; (*c*) Eustachian tube is present.
4. Accessory tragus (pedunculated).
5. Mandibular tubercle.
6. Scar over anterior edge of sterno-mastoid.
7. Great depression over petro-mastoid, which is very small; assymmetry of face secondary.
8. There is loss of taste in anterior two-thirds of tongue on left side.

Nature.—Probably primary absence of the otic vesicle, and secondary non-development of seventh and eighth nerves, and of petro-mastoid bone and tympanum, and also of proper auricle.

XLIV.—*Case of Early Puberty.* By R. P. Rowlands, M.S. *Exhibited April* 22, 1904.

BOY, æt. 2, of vicious temper and general overgrowth. He has attained puberty, and has large external genitals with long pubic hair; faint moustache. Mental development is about the average.

XLV.—*A Case of Gangrene of the Tips of the Fingers of Both Hands.* By C. J. SYMONDS, M.S. *Exhibited April* 22, 1904.

A MAN of 45 lost the top of the left forefinger in the winter of 1902. During last winter he has lost the tips of several other fingers on both hands. He attends to horses during the hunting season. He has not been exposed to more cold than this occupation would suggest. There is no arterial or nerve disease, nor any diabetes. The patient is under the care of Mr. Golding-Bird at Guy's Hospital, who sent him up.

The case was thought to be probably one of modified frost-bite, as there is no history of Raynaud's disease.

Note.—Rapid healing took place after he was exhibited. The necrosed bone was removed with marked benefit. The rapid recovery seemed to confirm the frost-bite view.

XLVI.—*Case of Spontaneous Fracture of the Neck of the Femur.* By C. J. SYMONDS, M.S. *Exhibited April* 22, 1904.

A MAN of 42, when kneeling to open a cupboard, heard a curious crunching noise, leading him to turn round and look for its cause. From that time he felt inconvenience in the hip, which gradually increased, although he was able to walk about without pain. One day he became suddenly worse; there was enormous swelling about the hip, and the leg was shortened. The neck of the femur appears to be broken, the head remaining in the acetabulum. There were at the time of this occurrence no signs of locomotor ataxy.

The patient was under the care of Mr. Tom Brown, of Kennington, to whom I am indebted for the notes of the case. When first seen there was great swelling about the hip, suggesting either a rapid effusion into the joint with dislocation, on a new growth. The skin in a still earlier stage, was stretched and reddened. With all this there was no pain. Gradually the effusion subsided to the present condition. He was placed under chloroform with a view of reducing a dis-

location and fixing the joint. It was clear, however, that the neck was broken, for the trochanter could be moved freely up and down, the stump of the attached neck grating over the half still in the acetabulum.

There are no definite signs of locomotor ataxy, except that the eyesight is perhaps becoming defective.

There is a history of syphilis, and I think that the case is probably one of spontaneous fracture as an early symptom of ataxy. He is obliged to use crutches at present.

PLATE XI.

Illustrating Mr. C. J. Symonds' Case of Spontaneous Fracture of the Neck of the Femur.

Bale and Danielsson, Ltd.

INDEX.

PAGE

ABRAHAMS (Bertram, M.B.), sporadic case of Friedreich's disease 237
Achondroplasia, with spinal curvature (? rachitic) (C. R. Keyser) 240
Acromegaly, early (W. Harris, M.D.) 253
Adiposis dolorosa ? (diffuse lipoma) in a man (L. Williams, M.D.) 209
Adults: congenital narrowness of pyloric orifice cause of chronic gastric disease in adult (A. E. Maylard) 63
AITCHISON (C. U.) and THOMPSON (H. T.), two cases of tumour of the left auricle of the heart, simulating mitral stenosis (introduced by Dr. Percy Kidd) 192
Anæmia (malignant): two cases, without signs of erythrocytolysis, and associated with suppuration about jaws (N. Dalton, M.D.) 101
——— pernicious, case presenting unusual features (W. Pasteur, M.D.) 35
ANDREWES (F. W., M.D.), notes from the Pathological Laboratory on Sir Dyce Duckworth's and Professor Howard Marsh's case of pneumococcal peritonitis 88
Aneurysm (femoral), ligature of superficial, femoral and popliteal arteries; cure of aneurysm (H. B. Robinson) 205
——— (multiple): case in which the largest, affecting brachial artery, was excised (R. Johnson) 228
Ankylosis and contracture of left knee treated by elastic steel-bar traction (T. H. Openshaw, C.M.G.) 251
——— of both temporo-maxillary joints (J. J. Clarke) . . . 110
ARMOUR (Donald), cyst arising in connection with the organ of Giraldes 244
Artery, ligature of superficial, femoral and popliteal arteries, for femoral aneurysm in Hunter's canal; cure of aneurysm (H. B. Robinson) 205
——— (brachial): case of multiple aneurysm in which the largest, affecting brachial artery, was excised (R. Johnson) . . 228

PAGE

Arthritis of knee, following fracture of femur, improved after removal of pressure by means of splint (T. H. Openshaw, C.M.G.) 252

Ataxy: see *Friedreich's* hereditary ataxy.

Auricle (left) of heart, two cases of tumour, simulating mitral stenosis (H. T. Thompson and C. U. Aitchison) . . . 192

Axis vertebra: fracture of both pedicles of (E. M. Corner) . . 234

BARNARD (Harold L.), a case of sarcoma of the left supra-renal body, with secondary deposits in the cranial bones, with the specimen of a second case 216

——— a pedicle trident for multiple ligature of pedicles and omentum 217

BATTEN (Frederick E., M.D.), case of myositis fibrosa, with pathological examination 12

——— a case of ophthalmoplegia externa with blindness of acute onset in a child æt. 5 years 225

BATTLE (William Henry), a case of fracture-dislocation in the upper cervical region without symptoms 232

——— a very large femoral hernia 245

BEAUMONT (Edgar), case of a child with apparently complete absence of sexual organs 216

Bladder (inverted): case of ectopia vesicæ (T. H. Kellock) . 210

Blindness of acute onset in case of ophthalmoplegia externa (F. E. Batten, M.D.) 225

Bone-marrow: case of chronic polycythæmia with enlarged spleen, probably disease of bone-marrow (F. Parkes Weber, M.D., and J. H. Watson, M.B.) 115

BOWLBY (Anthony A., C.M.G.), a case of acute hæmorrhagic pancreatitis 5

——— a creasote inhaler removed from the œsophagus by gastrotomy (by H. J. Paterson, introduced by A. A. Bowlby, C.M.G.) 215

Boy: tumour of liver in boy æt. 10 years (A. E. Garrod, M.D.) . 222

Breast (carcinoma, recurrent), advantages and disadvantages of X-ray treatment in (E. A. Peters, M.D.) 180

Bronchus: foreign body impacted in; removal by operation (W. Pasteur, M.D., and T. H. Kellock) 141

BROOK (W. H. B., M.D.), case of total paraplegia due to caries of the mid-dorsal vertebræ, for which the operation of costo-transversectomy has been performed, with complete recovery 223

PAGE

BROOK (W. H. B., M.D.) and GREEN (A. Stanley, M.B.), cases illustrating the value of the "X" rays as a factor of diagnosis of early pulmonary tuberculosis 167

Bulbar paralysis: see *Paralysis* (Bulbar).

BUTLIN (H. T., D.C.L.), and DUCKWORTH (Sir Dyce, M.D., LL.D.), a case of erosive gastric ulceration with severe hæmatemesis; operation; recovery 1

BUZZARD (E. Farquhar, M.D.), a case of attempted division of the eighth nerve within the skull for the relief of tinnitus (by C. S. Wallace and H. J. Marriage, with a report on the resulting degenerations by E. Farquhar Buzzard) . . . 164

Calculi in case of fibroid disease of the pancreas, accompanied by jaundice and subsequently by diabetes (S. Phillips, M.D.) 96

Carcinoma of breast, recurrent: advantages and disadvantages of X-ray treatment in (E. A. Peters, M.D.) 180

Caries of mid-dorsal vertebræ causing total paraplegia (W. H. B. Brook, M.D.) 223

Cerebral defect, severe, following measles (G. N. Pitt, M.D.) . 32

Cervical region: see *Neck*.

CLARKE (J. Jackson), a note on a case of ankylosis of both temporo-maxillary joints 110

Coma with measles in an adult: recovery (G. N. Pitt, M.D.) . 23

Contracture and ankylosis of left knee treated by elastic steel bar traction (T. H. Openshaw, C.M.G.) 251

——— of hip and knee treated by elastic traction (T. H. Openshaw, C.M.G.) 245

CORNER (Edred M.), primary and secondary local thrombosis of the thyroid gland 112

——— fracture of both pedicles of the axis 234

——— fracture of the body and laminæ of the fifth cervical vertebra 234

——— a case of pyopneumothorax due to phthisis; operations on the principles of Estlander's (thoracoplasty); healing with an aërial fistula 243

Costo-transversectomy in case of total paraplegia due to caries of mid-dorsal vertebræ, with complete recovery (W. H. B. Brook, M.D.) 223

Council: List of Officers and Council (1904–5) xix

——— Report of the Council, 1903 li

Cranial bones: secondary deposits in cranial bones present in case of sarcoma of left supra-renal body (H. L. Barnard) . 216

PAGE

Cranium: see *Skull.*
Creasote inhaler removed from œsophagus by gastrotomy (H. J. Paterson) 215
Cyst arising in connection with organ of Giraldes (D. Armour) . 244
——— (dermoid): translucent cyst, probably dermoid, of root of nose (R. Johnson) 227

Dalton (Norman, M.D.), two cases of malignant anæmia, without signs of erythrocytolysis, and associated with suppuration about the jaws 101
Deformity of feet, congenital, in mother and infant daughter (H. Batty Shaw, M.D.) 235
Dermoid cyst: translucent cyst, probably dermoid, of root of nose (R. Johnson) 227
Diabetes following jaundice in case of fibroid disease of pancreas, with calculi (S. Phillips, M.D.) 96
Diagnosis of early pulmonary tuberculosis; value of X rays as a factor in (A. Stanley Green, M.B., and W. H. B. Brook, M.D.) 167
Dickinson (W. Lee, M.D.), a case of congenital heart disease. ? Patent ductus arteriosus 253
Diphtheria (sequelæ of), post-diphtheritic chronic bulbar paralysis: two cases (W. Harris, M.D.) 228
Dislocation: see *Fracture-dislocation.*
Duckworth (Sir Dyce, M.D., LL.D.) and Butlin (H. T., D.C.L.), a case of erosive gastric ulceration with severe hæmatemesis; operation; recovery 1
——— and Marsh (Professor Howard, M.A.): a case of pneumococcal peritonitis; laparotomy; left empyema; thoracentesis; recovery [with notes from the pathological laboratory by Dr. Andrewes] 83, 88
Ductus arteriosus: ? patent ductus arteriosus in case of congenital heart disease (Lee Dickinson, M.D.) 253
Duodenum (ulcer of): gastro-enterostomy for simple ulcer of the stomach and duodenum; one hundred cases (B. G. A. Moynihan) 74

Ear: malformation, congenital, of upper limb and ear (R. P. Rowlands) 256
Ectopia vesicæ: see *Bladder* (inverted).
Elastric traction in treatment of contracture of hip and knee (T. H. Openshaw, C.M.G.) 245
——— steel-bar traction in treatment of firm ankylosis and contracture of left knee (T. H. Openshaw, C.M.G.) 251

PAGE

Empyema (left) complicating case of pneumococcal peritonitis; thoracentesis; recovery (Sir Dyce Duckworth, M.D., and Professor Howard Marsh, M.A.) 83
Epileptiform neuralgia: see *Neuralgia* (epileptiform).
Erythrocytolysis: two cases of malignant anæmia, without signs of erythrocytolysis (N. Dalton, M.D.) 101
Erythromelalgia (chronic) of left foot in case of polycythæmia (F. Parkes Weber, M.D.) 249
Estlander: principles of his operations (thoracoplasty) applied in case of pyopneumothorax due to phthisis (E. M. Corner) 243

Feet (deformity, congenital): in mother and infant daughter (H. Batty Shaw, M.D.) 235
Femoral arteries: see *Artery*.
Femoral hernia: see *Hernia* (femoral).
Femur: fracture of, followed by arthritis of knee-joint (T. H. Openshaw, C.M.G.) 252
——— fracture, spontaneous, of neck of femur (C. J. Symonds) . 257
Fibroid disease of the pancreas with calculi, accompanied by jaundice and subsequently by diabetes (S. Phillips, M.D.) . 96
Fibroma, naso-pharyngeal, vascular, of extensive origin: method of final removal (H. Tilley, M.D.) 212
Fibulæ: congenital absence of (C. R. Keyser) 230
Filigree: see *Silver-wire* filigree.
Fingers: gangrene of tips of fingers of both hands (C. J. Symonds) 257
Finlay (Professor David W., M.D.), a case of tuberculous pyopneumothorax treated by incision and removal of ribs . . 183
Fistula, aërial, accompanying healing after operation in case of pyopneumothorax (E. M. Corner) 243
Foot (left): chronic erythromelalgia of left foot in case of polycythæmia (F. Parkes Weber, M.D.) 249
Foreign body impacted in bronchus; removal by operation (W. Pasteur, M.D., and T. H. Kellock) 141
Fracture of body and laminæ of fifth cervical vertebra (E. M. Corner) 234
——— of both pedicles of axis (E. M. Corner) 234
——— of femur followed by arthritis of knee-joint (T. H. Openshaw, C.M.G.) 252
——— ——— spontaneous fracture of neck of femur (C. J. Symonds) 257

PAGE
Fracture of radius and ulna (ununited) (J. R. Lunn) . . . 224
Fracture-dislocation in upper cervical region, case without symptoms (W. H. Battle) 232
FRENCH (Herbert, M.D.), two cases of osteitis deformans . . 213
Friedreich's hereditary ataxy: sporadic case (B. Abrahams, M.B.) 237

Gangrene of tips of fingers of both hands (C. J. Symonds) . . 257
GARROD (A. E., M.D.), tumour of the liver in a boy æt. 10 years. 222
Gastric ulceration: see *Stomach*, ulceration of.
Gastro-enterostomy for simple ulcer of the stomach and duodenum; one hundred cases (B. G. A. Moynihan) . . . 74
Gastrotomy: creasote inhaler removed from œsophagus by (H. J. Paterson) 215
Giraldes (organ of): cyst arising in connection with (D. Armour) 244
GOODALL (E. W.), two cases of intestinal obstruction immediately following an attack of typhoid fever 145
GREEN (A. Stanley, M.B.), and BROOK (W. H. B., M.D.), cases illustrating the value of the "X" rays as a factor of diagnosis of early pulmonary tuberculosis 167

Hæmatemesis, severe, in case of erosive gastric ulceration (Sir Dyce Duckworth, M.D., and H. T. Butlin, D.C.L.) . . 1
Hæmaturia: severe and fatal case of unknown origin (W. G. Spencer) 156
Hand (left): congenital absence of phalanges of (L. McGavin) . 226
Hands (muscles of): congenital absence of small muscles of hands in mother and infant daughter (H. Batty Shaw, M.D.) . . 235
HARRIS (Wilfred, M.D.), two cases of post-diphtheritic chronic bulbar paralysis 228
——— case of early acromegaly 253
Heart, disease of: death from cardiac disease, ten weeks after successful ligature of femoral aneurysm (H. B. Robinson) . 205
——— ——— pulmonary regurgitation associated with mitral stenosis (J. P. Parkinson, M.D.) 238
——— ——— (congenital), ? patent ductus arteriosus (Lee Dickinson, M.D.) 253
——— (auricle, left): two cases of tumour, simulating mitral stenosis (H. T. Thompson and C. U. Aitchison) . . . 192
Hernia, femoral, very large (W. H. Battle) 245
——— (post-operative): case treated by the introduction of prepared silver-wire filigree (L. McGavin) . . . 59

PAGE

Hip-joint: contracture of hip and knee treated by elastic traction (T. H. Openshaw, C.M.G.) 245
HUTCHINSON (J., jun.), intra-cranial resection of the second division of the fifth nerve for epileptiform neuralgia . . 136

Inhaler: see *Creasote* inhaler.
Intestine (small); excision of forty-two inches in case of chronic intussusception; recovery (F. C. Wallis) 42
Intestines (obstruction of): two cases immediately following attack of typhoid fever (E. W. Goodall, M.D.) . . . 145
Intra-cranial resection of second division of fifth nerve for epileptiform neuralgia (J. Hutchinson, jun.) 136
Intussusception (chronic): excision of forty-two inches of small intestine; recovery (F. C. Wallis) 42

Jaundice accompanying fibroid disease of the pancreas with calculi (S. Phillips, M.D.) 96
Jaw: enlargement of bones of cranium, jaw and thorax (? syphilitic) (W. G. Stone, M.D.) 239
Jaws: suppuration about, present in two cases of malignant anæmia (N. Dalton, M.D.) 101
JOHNSON (Raymond), translucent cyst (probably dermoid) of root of nose 227
——— a case of multiple aneurysm, in which the largest, affecting the brachial artery, was excised 228

KELLOCK (Thomas H.), a case of ectopia vesicæ after operation . 210
——— a case of (?) tumour at the base of the skull . . . 210
——— and PASTEUR (William, M.D.), foreign body impacted in bronchus; removal by operation 141
KEYSER (Charles R.), congenital elevation of the shoulder . . 230
——— congenital absence of the fibulæ 230
——— a case of achondroplasia with spinal curvature (? rachitic) 240
KIDD (Percy, M.D.), two cases of tumour of the left auricle of the heart, simulating mitral stenosis; by H. T. Thompson and C. U. Aitchison, introduced by Percy Kidd, M.D. . . . 192
Knee-joint, arthritis of, following fracture of femur, improved after removal of pressure by means of splint (T. H. Openshaw, C.M.G.) 252
——— contracture of hip and knee treated by elastic traction (T. H. Openshaw, C.M.G.) 245

PAGE

Knee-joint, movable, three and a half years after operation for extensive tuberculous disease (F. J. Steward) . . . 247
——— (left) contracture and ankylosis treated by elastic steel traction (T. H. Openshaw C.M.G.) 251

Laparotomy for fibroid disease of pancreas with calculi; relief of symptoms; death (S. Phillips, M.D.) 96
——— performed in case of pneumococcal peritonitis; left empyema; thoracentesis; recovery (Sir Dyce Duckworth, M.D., and Professor Howard Marsh, M.A.) 83
Leucocythæmia (lymphatic leukæmia): two cases (F. Taylor, M.D.) 46
Ligature of superficial, femoral and popliteal arteries, for femoral aneurysm in Hunter's canal, cure of aneurysm (H. B. Robinson) 205
——— (multiple) of pedicles and omentum; pedicle trident for (H. L. Barnard) 217
Limb (upper): malformation: congenital, of upper limb and ear (R. P. Rowlands) 256
Lipoma, diffuse (adiposis dolorosa?) in a man (L. Williams, M.D.) 209
Lipomatosis (diffuse) in a man with slight general wasting (F. Parkes Weber, M.D.) 221
——— ——— in a woman without any associated pain (F. Parkes Weber, M.D.) 220
Liver: tumour of liver in boy æt. 10 years (A. E. Garrod, M.D.) 222
Lunn (John R.), a case of chronic pericarditis (syphilitic) with skiagram 224
——— a case of ununited fracture of radius and ulna . . . 224
Lymphatic leukæmia (leucocythæmia): two cases (F. Taylor, M.D.) 46

McGavin (Lawrie), a case of post-operative hernia treated by the introduction of prepared silver-wire filigree 59
——— congenital absence of the phalanges of the left hand . 226
Malformation, congenital, of upper limb and ear (R. P. Rowlands) 256
Man: diffuse lipoma (adiposis dolorosa?) in a man (L. Williams, M.D.) 209
——— diffuse lipomatosis in a man with slight general wasting (F. Parkes Weber, M.D.) 221
Marriage (H. J.) and Wallace (Cuthbert S.), a case of attempted division of the eighth nerve within the skull for the relief of tinnitus (with a report on the resulting degeneration, by E. Farquhar Buzzard, M.D.) 159, 164

PAGE

MARSH (Professor Howard, M.A.), and DUCKWORTH (Sir Dyce, M.D., LL.D.), a case of pneumococcal peritonitis; laparotomy; left empyema; thoracentesis; recovery (with notes from the Pathological Laboratory by Dr. Andrewes) . 83, 88

Maxillary bone: combined operation through soft and hard palate and extensive removal of anterior wall of left superior maxillary bone in final removal of vascular naso-pharyngeal fibroma of extensive origin (H. Tilley, M.D.) . . 212

MAYLARD (A. Ernest), congenital narrowness of the pyloric orifice: a cause of chronic gastric disease in the adult; illustrated by seven cases successfully treated by operation . . 63

Measles: cerebral defect (severe) following (G. N. Pitt, M.D.) . 32

——— with coma in an adult: recovery (G. N. Pitt, M.D.) . 23

Members of the Society xxi

——— Honorary Members xxii

——— Foreign Honorary Members xxiii

Mitral stenosis: pulmonary regurgitation associated with mitral stenosis (J. P. Parkinson, M.D.) 238

——— two cases of tumour of left auricle of heart simulating (H. T. Thompson and C. U. Aitchison) 192

MOYNIHAN (B. G. A.), one hundred cases of gastro-enterostomy for simple ulcer of the stomach and duodenum . . . 74

Muscles, of hands: congenital absence of small muscles of hands in mother and infant daughter (H. Batty Shaw, M.D.) . . 235

Myositis fibrosa, with pathological examination (F. E. Batten, M.D.) 12

Naso-pharynx, vascular fibroma of extensive origin; method of final removal (H. Tilley, M.D.) 212

Neck: fracture-dislocation in upper cervical region, case without symptoms (W. H. Battle) 232

Nerve (eighth): attempted division of eighth nerve within skull for relief of tinnitus (C. S. Wallace and H. J. Marriage) . 159

Nerve degeneration: report on resulting degenerations in case of attempted division of eighth nerve for relief of tinnitus (E. Farquhar Buzzard) 159

Neuralgia (epileptiform): intra-cranial resection of second division of fifth nerve (J. Hutchinson, jun.) 136

Nose: translucent cyst, probably dermoid, of root of nose (R. Johnson) 227

Œsophagus: creasote inhaler removed from œsophagus by gastrotomy (H. J. Paterson) 215

PAGE

Officers of the Society xix

OPENSHAW (T. H., C.M.G.): contracture of hip and knee treated by elastic traction 245

——— case of firm ankylosis and contracture of left knee treated by elastic steel bar traction 251

——— case of arthritis of knee, following fracture of femur, improved after removal of pressure, by means of splint . . 252

Omentum: pedicle trident for multiple ligature of pedicles and omentum (H. L. Barnard) 217

Ophthalmoplegia externa, with blindness of acute onset (F. E. Batten, M.D.) 225

Osteitis deformans, two cases (H. French, M.D.) 213

——— two cases (C. Gordon Watson) 231

Pain not associated in case of diffuse lipomatosis in a woman (F. Parkes Weber, M.D.) 220

Palate (soft and hard): combined operation through soft and hard palate, and extensive removal of anterior wall of left superior maxillary bone, in final removal of vascular nasopharyngeal fibroma of extensive origin (H. Tilley, M.D.) . 212

Pancreas: fibroid disease with calculi, accompanied by jaundice and subsequently by diabetes; laparotomy; relief of symptoms; death (S. Phillips, M.D.) 96

Pancreatitis, hæmorrhagic (F. Taylor, M.D.) 8

——— ——— ——— acute (A. A. Bowlby, C.M.G.) . . . 5

Paralysis (bulbar, chronic): two cases of post-diphtheritic chronic bulbar paralysis (W. Harris, M.D.) 228

Paraplegia (total) due to caries of mid-dorsal vertebræ: costotransversectomy performed: complete recovery (W. H. B. Brook, M.D.) 223

PARKINSON (J. Porter, M.D.), morbus cordis: pulmonary regurgitation associated with mitral stenosis 238

PASTEUR (William, M.D.), a case of pernicious anæmia presenting unusual features 35

——— and KELLOCK (T. H.), foreign body impacted in bronchus; removal by operation 141

PATERSON (Herbert J.), a creasote inhaler removed from the œsophagus by gastrotomy, with skiagraph showing the inhaler *in situ* (introduced by A. A. Bowlby, C.M.G.) . . 215

Pathological examination of case of myositis fibrosa (F. E. Batten, M.D.) 12

PAGE

Pedicle trident for multiple ligature of pedicles and omentum (H. L. Barnard) 217
Periostitis (chronic) of syphilitic origin (J. R. Lunn) . . . 224
Peritonitis, pneumococcal (F. Taylor, M.D.) 91
——— ——— ——— laparotomy; left empyema; thoracentesis; recovery (Sir Dyce Duckworth, M.D., and Professor Howard Marsh, M.A.) 83
PETERS (E. A., M.D.), notes of two cases illustrating the advantages and disadvantages of X-ray treatment in recurrent carcinoma of the breast 180
Phalanges of left hand, congenital absence of (L. McGavin) . 226
PHILLIPS (Sidney, M.D.), a case of fibroid disease of the pancreas with calculi, accompanied by jaundice and subsequently by diabetes; laparotomy; relief of symptoms; death . . 96
Phthisis: pyopneumothorax due to (E. M. Corner) . . . 243
——— see also *Tuberculosis* (pulmonary).
PITT (G. Newton, M.D.), case of coma with measles in an adult, followed by recovery. Appendix: case of severe cerebral defect following measles 23, 32
Pneumococcal peritonitis (F. Taylor, M.D.) 91
——— ——— ——— laparotomy; left empyema; thoracentesis; recovery (Sir Dyce Duckworth, M.D., and Professor Howard Marsh, M.A.) 83
Popliteal arteries, see *Artery*.
Polycythæmia, with enlarged spleen and chronic erythromelalgia of left foot (F. Parkes Weber, M.D.) 249
——— (chronic): case with enlarged spleen, probably disease of bone-marrow (F. Parkes Weber, M.D., and J. H. Watson, M.B.) 115
Post-operative hernia: case treated by introduction of silver-wire filigree (L. McGavin) 59
Presidents of the Society since its formation xx
Puberty, early, case of (R. P. Rowlands) 256
Pulmonary regurgitation: see *Regurgitation* (pulmonary).
Pylorus (stenosis, congenital): congenital narrowness of orifice, a cause of chronic gastric disease in the adult; seven cases successfully treated by operation (A. E. Maylard) . . . 63
Pyopneumothorax due to phthisis; thoracoplasty: healing with aërial fistula (E. M. Corner) 243
——— (tuberculous) treated by incision and removal of ribs (D. W. Finlay, M.D.) 183
Radius: fracture of radius and ulna (ununited) (J. R. Lunn) . 224

PAGE

Regurgitation (pulmonary) associated with mitral stenosis (J. P. Parkinson, M.D.) 238
Resection, intra-cranial, of second division of fifth nerve for epileptiform neuralgia (J. Hutchinson, jun.) 136
Ribs, incision and removal, in treatment of case of tuberculous pyopneumothorax (D. W. Finlay, M.D.) 183
Rickets: achondroplasia, with spinal curvature (? rachitic) (C. R. Keyser) 240
Robinson (Henry Betham), femoral aneurysm in Hunter's canal; ligature of superficial femoral and popliteal arteries; cure of the aneurysm; death from cardiac disease ten weeks later 205
Röntgen rays: advantages and disadvantages of X-ray treatment in recurrent carcinoma of the breast (E. A. Peters, M.D.) 180
——— value as factor of diagnosis of early pulmonary tuberculosis (A. Stanley Green, M.B., and W. H. B. Brook, M.D.) 167
Rowlands (R. P.), case of congenital malformation, upper limb and ear 256
——— case of early puberty 256

Sarcoma of left supra-renal body, with secondary deposits in cranial bones (H. L. Barnard) 216
Sexual organs apparently completely absent in a child (E. Beaumont) 216
Shaw (H. Batty, M.D.), congenital absence of the small muscles of the hands and deformity of the feet in mother and infant daughter 235
Shoulder: congenital elevation (C. R. Keyser) 230
Silver-wire filigree: post-operative hernia treated by introduction of (L. McGavin) 59
Skull: enlargement of bones of cranium, jaw, and thorax (? syphilitic) (W. G. Stone, M.D.) 239
——— ? tumour at base of skull (T. H. Kellock) 210
Spencer (Walter G.), severe and fatal hæmaturia of unknown origin 156
——— bilateral enlargement of testicles in a boy æt. 10 . . 225
Spine (curvature of): case of achondroplasia with spinal curvature (? rachitic) (C. R. Keyser) 240
Spleen, enlarged, in case of polycythæmia (F. Parkes Weber, M.D.) 249

PAGE

Spleen (enlarged) present in case of chronic polycythæmia (F. Parkes Weber, M.D., and J. H. Watson, M.B.) . . . 115
Splint: removal of pressure, by means of splint, improving case of arthritis of knee following fracture of femur (T. H. Openshaw, C.M.G.) 252
Steel bar traction, see *Elastic* steel bar traction.
Stenosis (mitral), see *Mitral stenosis.*
——— of pylorus: congenital narrowness of pyloric orifice, cause of chronic gastric disease in adult (A. E. Maylard) . . 63
STEWARD (F. J.), case of movable knee-joint three and a half years after operation for extensive tuberculous disease . 247
Stomach, disease of, chronic, in the adult, caused by congenital narrowness of pyloric orifice; seven cases successfully treated by operation (A. E. Maylard) 63
——— (ulcer of): gastro-enterostomy for simple ulcer of the stomach and duodenum: one hundred cases (B. G. A. Moynihan) 74
——— ulceration, erosive, with severe hæmatemesis; operation; recovery (Sir Dyce Duckworth, M.D., and H. T. Butlin) . 1
STONE (W. G., M.D.), a case of enlargement of the bones of the cranium, jaw, and thorax (? syphilitic) 239
Suppuration about jaws, associated with two cases of malignant anæmia (N. Dalton, M.D.) 101
Supra-renal body (left), sarcoma, with secondary deposits in cranial bones (H. L. Barnard) 216
SYMONDS (Charters J.), a case of gangrene of the tips of the fingers of both hands 257
——— case of spontaneous fracture of the neck of the femur . 257
Syphilis: chronic periostitis of syphilitic origin (J. R. Lunn) . 224
——— enlargement of bones of cranium, jaw and thorax (? syphilitic) (W. G. Stone, M.D.) 239

TAYLOR (Frederick, M.D.), a case of hæmorrhagic pancreatitis . 8
——— two cases of leucocythæmia (lymphatic leukæmia) . . 46
——— a case of pneumococcal peritonitis 91
Temporo-maxillary joints, ankylosis on both sides (J. J. Clarke) 110
Testicles: bilateral enlargement in boy æt. 10 (W. G. Spencer) . 225
——— see *Giraldes*, organ of.
THOMPSON (H. T.) and AITCHISON (C. U.), two cases of tumour of the left auricle of the heart, simulating mitral stenosis (introduced by Dr. Percy Kidd) 192

PAGE

Thoracoplasty (principles of Estlander's operations) in treatment of case of pyopneumothorax due to phthisis (E. M. Corner) . 243

Thorax: enlargement of bones of cranium, jaw, and thorax (? syphilitic) (W. G. Stone, M.D.) 239

Thyroid gland: primary and secondary local tuberculosis of (E. M. Corner) 112

TILLEY (Herbert, M.D.), case of vascular naso-pharyngeal fibroma of extensive origin, finally removed by a combined operation through the soft and hard palate and extensive removal of anterior wall of left superior maxillary bone 212

Tinnitus: attempted division of eighth nerve within skull for relief of tinnitus (C. S. Wallace and H. J. Marriage) . . 159

Treasurer's Statement of Receipts and Payments liii

Tuberculosis of hip-joint: case of movable hip-joint three and a half years after operation for extensive tuberculous disease (F. J. Steward) 247

——— (local) of thyroid gland, primary and secondary (E. M. Corner) 112

——— (pulmonary): cases illustrating value of X-rays as factor of diagnosis of early pulmonary tuberculosis (A. Stanley Green, M.B., and W. H. B. Brook, M.D.) 167

Tuberculous pyopneumothorax treated by incision and removal of ribs (D. W. Finlay, M.D.) 183

? Tumour at base of skull (T. H. Kellock) 210

Tumour of left auricle of heart, simulating mitral stenosis (H. T. Thompson and C. U. Aitchison) 192

——— of liver in boy æt. 10 years (A. E. Garrod, M.D.) . . 222

Typhoid fever: intestinal obstruction immediately following, in two cases (E. W. Goodall, M.D.) 145

Ulcer of duodenum: gastro-enterostomy for (B. G. A. Moynihan) 74

——— of stomach: gastro-enterostomy for (B. G. A. Moynihan) 74

Ulna: fracture of radius and ulna (ununited) (J. R. Lunn) . . 224

Vertebra (cervical, fifth), fracture of body and laminæ of (E. M. Corner) 234

——— See also *Axis* vertebra.

Vertebræ (mid-dorsal): caries of mid-dorsal vertebræ causing total paraplegia (W. H. B. Brook, M.D.) 223

PAGE

WALLACE (Cuthbert S.) and MARRIAGE (H. J.), a case of attempted division of the eighth nerve within the skull for the relief of tinnitus (with a report on the resulting degenerations by E. Farquhar Buzzard, M.D.) 159, 164

WALLIS (F. C., M.B.), a case of chronic intussusception; excision of forty-two inches of small intestine; recovery . . . 42

Wasting, slight general, in case of diffuse lipomatosis in a man (F. Parkes Weber, M.D.) 221

WATSON (C. Gordon), two cases of osteitis deformans . . . 231

WATSON (J. H., M.B.) and WEBER (F. Parkes, M.D.), a case of chronic polycythæmia with enlarged spleen, probably a disease of the bone-marrow 115

WEBER (F. Parkes, M.D.), diffuse lipomatosis in a woman without any associated pain 220

——— diffuse lipomatosis in a man with slight general wasting. 221

——— case of polycythæmia with enlarged spleen and chronic erythromelalgia of the left foot 249

——— and WATSON (J. H., M.B.), a case of chronic polycythæmia with enlarged spleen, probably a disease of the bone-marrow 115

WILLIAMS (Leonard, M.D.), a case of diffuse lipoma (adiposis dolorosa?) in a man 209

Woman: diffuse lipomatosis in a woman without any associated pain (F. Parkes Weber, M.D.) 220

X-rays: see *Röntgen* rays.

PRINTED BY ADLARD AND SON, LONDON AND DORKING.

Note.—All attempts at reduction by means of rest in bed, improvement of the cough, and the application of bandages appeared to be without result in diminishing the size of the

FIG. 15.

hernia, but the skin covering it became normal. She was anxious for operation, and the hernia was reduced on March 25, although with some difficulty, the patient being under the influence of chloroform.

The contents of the sac consisted of several feet of small